N.I. Health and Social Services
Queen's University Medical Library
MEDICAL LIBRARY
SHELVED AT
QM 34 BOEN

6341824 [X]

QUEEN'S UNIVERSITY OF BELFAST
SHELVED A
QM 34/6
MEDICAL LIBRARY
CHARGE O.

"With the Compliments of the Author"

A TREATISE

ON

PRACTICAL ANATOMY:

FOR

Students of Anatomy and Surgery.

BY

HENRY C. BOENNING, M.D.,

LECTURER ON ANATOMY AND SURGERY IN THE PHILADELPHIA SCHOOL OF ANATOMY; DEMONSTRATOR OF ANATOMY IN THE MEDICO-CHIRURGICAL COLLEGE; DEMONSTRATOR OF ANATOMY IN THE PHILADELPHIA DENTAL COLLEGE; LECTURER ON DISEASES OF THE RECTUM IN THE MEDICO-CHIRURGICAL COLLEGE, ETC.

ILLUSTRATED WITH 198 WOOD-ENGRAVINGS.

ANATOMICAL DEPARTMENT
BELFAST.
QUEEN'S UNIVERSITY

PHILADELPHIA AND LONDON:
F. A. DAVIS, PUBLISHER.
1891.

Entered according to Act of Congress, in the year 1891, by
F. A. DAVIS,
In the Office of the Librarian of Congress, at Washington, D. C., U. S. A.

Philadelphia, Pa., U. S. A.:
The Medical Bulletin Printing House,
1231 Filbert Street.

TO

JAMES E. GARRETSON, M.D.,

WHOSE FAME AS A SCHOLAR, TEACHER, SURGEON, AND AUTHOR EXTENDS THROUGHOUT THE CIVILIZED WORLD,

THE BEST WITHIN THIS BOOK IS AFFECTIONATELY DEDICATED,

IN RECOGNITION OF HIS GREAT TALENTS AND IN APPRECIATION OF THE KINDLY, GENEROUS FRIENDSHIP HE HAS EVER SHOWN

THE AUTHOR.

Digitized by the Internet Archive
in 2025

https://archive.org/details/treatiseonpracti0000henr

PREFACE.

In presenting this book to the profession, the author desires to state that it was written especially for students of anatomy and surgery.

It has been his aim to arrange the subject so as to make it equally serviceable as a text-book on anatomy and a dissector. It will be found fully abreast of the latest teachings in anatomy, and, in some directions, decidedly aggressive, as in treating of the outer layer of the muscular fibres of the uterus, and of the structure of the alveolar processes of the maxillary bones. The section on the teeth has been written with great care by Drs. T. S. Heineken, of New Jersey, and E. E. Caspersonn, of Australia. The author wishes to acknowledge the valuable aid rendered by his assistants at the Philadelphia School of Anatomy, Drs. Bland, Croskey, Mackellar, Earley, Halsey, Ellerbeck, Frutchey, Hughes, Sangree, and Mintzer, and his indebtedness to the excellent museums of the Medico-Chirurgical and Philadelphia Dental Colleges. Acknowledgment is also made of the many courtesies extended to him by Professors Garretson, Pancoast, Shoemaker, Dorr, Stellwagon, Flagg, and Montgomery. Mr. Davis, the publisher, and his courteous representative, Mr. Johnson, have in every way facilitated the arrangement of the final details, and at once agreed

to present the book in the most attractive and perfect manner possible to the mechanics of their profession.

The illustrations have been carefully selected and their sources credited. Note should also be made of the excellence of the work of the artist, Mr. George A. Newman.

Finally, the book is not a compilation; it is the result of years of practical work and a large experience in teaching. The descriptions in the text have been taken from the bone itself and the subject on the table, and are so treated as to adapt them to the student everywhere.

538 North Sixth Street.
September, 1891.

TABLE OF CONTENTS.

SECTION I.

	PAGE
OSTEOLOGY	1
Bone	1
Minute anatomy	2
Development and growth	6
Skeleton	9
Bones of the Skull	11
Frontal bone	11
Parietal bone	14
Occipital bone	16
Temporal bone	20
Sphenoid bone	26
Ethmoid bone	32
Nasal bone	36
Malar bone	37
Superior maxillary bone	38
Lachrymal bone	46
Palate bone	47
Vomer	51
Inferior turbinated bone	53
Inferior maxillary bone	54
The Skull	60
Base	63
Floor of cranium	68
Facial portion	71
Nasal cavities	72
Cavity of mouth	75
Lateral region	76
Fissures of	77
At different ages	78
In the sexes	79
In different races	79
Craniometry	79
Facial angles	82
The Spine	83
Cervical vertebræ	86
Atlas	87
Axis	88
Vertebra prominens	89
Dorsal vertebræ	90
Lumbar vertebræ	91
The sacrum	93
The coccyx	96
Bones of the Trunk	96
Hyoid	96
The thorax	97
The sternum	97
The costal cartilages	100
The ribs	100
The chest	103

PAGE
Bones of Upper Extremity 105
Clavicle 105
Scapula 107
Humerus 111
Ulna 114
Radius 116
Carpus 119
Metacarpus 122
Phalanges 124
Bones of Lower Extremity 125
Os innominatum 125
Pelvis 131
Femur 133
Patella 137
Tibia 138
Fibula 140
Tarsus 141
Metatarsus 147
Phalanges 148

SECTION II.

JOINTS AND LIGAMENTS 150
Cartilage 150
Fibrous tissue 151
Classification of 152
Articulations of head 153
Articulations of head with vertebral column 154
Articulations of the vertebral column 155
Articulations between ribs and vertebræ 155
Ligaments of sternum 156
Costo-sternal articulations 156
Articulations of vertebral column and pelvis 157
Articulations of pelvis 157
Sterno-clavicular articulations 159
Acromio-clavicular articulations 160
Scapular ligaments 160
Ligaments of shoulder-joint 161
Ligaments of elbow-joint 161
Ligaments of wrist-joint 163
Ligaments of carpus 163
Synovial membranes of carpus 164
Ligaments of hip-joint 165
Ligaments of knee-joint 166
Ligaments of ankle-joint 168
Ligaments of tarsus 169
Synovial membranes of tarsus 170

SECTION III.

MUSCULAR SYSTEM 172
Structure of Muscle 172
Muscles of head 176
Muscles of neck 185
Muscles of the thorax 192
Muscles of the back 194
Muscles of the abdomen 201
Muscles of the upper extremities 205
Muscles of the lower extremities 216
Muscles of the perineum and ischio-rectal region 229

SECTION IV.

PAGE
THE VASCULAR SYSTEM 232
ARTERIES 232
General considerations 232
Aorta 234
Subclavian 236
Axillary 239
Brachial 241
Radial 241
Ulnar 242
Common carotid 243
External carotid 243
Internal carotid 245
Thoracic aorta 247
Abdominal aorta 247
Common iliac 249
Internal iliac 250
External iliac 251
Femoral 252
Popliteal 253
Anterior tibial 253
Posterior tibial 254
Pulmonary 255
VEINS 255
General considerations 256
Of neck 257
Of cranium 258
Of upper extremity 260
Of lower extremity 261
Of trunk 261
Portal vein 263
Vena cava ascendens 262
Vena cava descendens 263
LYMPHATICS 264
General considerations 264
Of head and neck 265
Of upper extremity 265
Of trunk 266
Of lower extremity 269

SECTION V.

THE NERVOUS SYSTEM 270
GENERAL CONSIDERATIONS 270
Brain 274
Dura mater 276
Arachnoid 277
Pia mater 278
Cerebrum 279
Convolutions of frontal lobe 282
Convolutions of parietal lobe 283
Convolutions of occipital lobe 283
Convolutions of temporo-sphenoidal lobe 283
Convolutions of orbital lobe 283
Of the island of Reil 284
Of the inner surface of hemisphere 284
Fissures of cerebrum 285
Base of 286

PAGE
Brain, Section of 289
Lateral ventricle 290
Third ventricle 295
Fourth ventricle 297
Medulla oblongata 299
Cerebellum 301
The spinal cord 303
Membranes of 304
Sections of 306
Cranial nerves 308
1. Olfactory 308
2. Optic 309
3. Motor oculi 310
4. Patheticus 310
5. Trifacial 311
Lenticular ganglion 311
Meckel's ganglion 312
Submaxillary ganglion 314
Otic ganglion 314
6. Abducens 314
7. Facial 314
8. Auditory 316
9. Glosso-pharyngeal 316
10. Pneumogastric 317
11. Spinal accessory 318
12. Hypoglossal 319
Spinal nerves 319
Cervical 320
Cervical plexus 320
Brachial plexus 321
Dorsal 324
Lumbar 324
Lumbar plexus 325
Sacral 327
Sacral plexus 327
SYMPATHETIC 330
Cervical ganglia 330
Thoracic ganglia 332
Solar plexus 332
Lumbar ganglia 332
Pelvic ganglia 333

SECTION VI.

THORACIC VISCERA 334
THE THORAX 334
The heart 335
Pericardium 335
Superior vena cava 337
Inferior vena cava 337
Right auricle 337
Right ventricle 338
Left auricle 339
Left ventricle 340
Endocardium 342
The larynx 343
Thyroid cartilage 343
Cricoid cartilage 343
Epiglottis 343
Arytenoid cartilages 344

PAGE
The larynx, Ligaments of 344
Muscles of 345
Vocal cords 345
The trachea 346
The bronchi 346
Their septum 346
The pleuræ 347
The lungs 347
Structure 348
Air-cells 349
Organs of digestion 350
Mouth 350
Teeth 351
Physical characters 352
Permanent 353
Temporary 357
Structure of 357
Table of eruption 361
Salivary glands 362
Parotid 362
Submaxillary 363
Submental 364
The pharynx 364
The tonsils 365
The œsophagus 365

SECTION VII.

ABDOMINAL VISCERA 367
ABDOMEN 367
Peritoneum 369
The stomach 371
The small intestine 373
The large intestine 376
The liver 379
The gall-bladder 382
The pancreas 383
The spleen 383
The kidney 384
The ureter 390
The supra-renal capsule 391
The thyroid gland 391
The thymus gland 392

SECTION VIII.

ELVIC VISCERA, INCLUDING ORGANS OF GENERATION . . 393
The pelvis 393
The bladder 393
The male urethra 395
Prostate gland 396
Cowper's gland 397
The penis 397
The testes 399
The seminal vesicles 402
FEMALE ORGANS OF GENERATION 402
The vulva 403
The urethra 404
The vagina 405

PAGE
The uterus 406
The Fallopian tubes 409
The ovaries 409
The mammary glands 411

SECTION IX.

SPECIAL SENSES 413
The Eye 413
The sclerotic 414
The choroid 415
The retina 416
Appendages 420
The Ear 422
The external ear 423
The middle ear 424
The internal ear 428
The membranous labyrinth 433
The Organ of Taste 433
The Organ of Smell 435
The Skin 436

SECTION X.

REGIONAL ANATOMY 440
The Neck 440
The Axilla 447
The Perineum 450
Scarpa's Triangle 454
Femoral Hernia 455
Inguinal Hernia 456

LIST OF ILLUSTRATIONS.

FIG.		PAGE
1.	Lacunæ and canaliculi	4
2.	Frontal bone, outer surface	11
3.	Frontal bone, inner surface	13
4.	Parietal bone, outer surface	15
5.	Parietal bone, inner surface	15
6.	Occipital bone, outer surface	17
7.	Occipital bone, inner surface	19
8.	Temporal bone, outer surface	20
9.	Temporal bone, inner surface	23
10.	Temporal bone, petrous portion	24
11.	Sphenoid bone, superior surface	27
12.	Sphenoid bone, anterior surface	29
13.	Ethmoid bone, lateral view	33
14.	Ethmoid bone, lateral mass removed	34
15.	Nasal bone	36
16.	Malar bone	37
17.	Superior maxillary, anterior surface	39
18.	Superior maxillary, inner surface	41
19.	Roof of mouth	45
20.	Lachrymal bone	47
21.	Palate bone, in profile	48
22.	Palate bone, inner surface	48
23.	Vomer	52
24.	Inferior turbinated bone	53
25.	Inferior maxillary, outer surface	54
26.	Inferior maxillary, inner surface	56
27.	Showing angulation of tooth-sockets	57
28.	Lateral view of skull	60
29.	Base of skull	64
30.	Floor of the cranium	69
31.	Facial portion of skull	73
32.	Nasal meatuses	74
33.	Vertebral column	85
34.	Relation of the vertebræ to the neck and trunk	85
35.	A cervical vertebra	86
36.	The atlas	87
37.	The axis	88
38.	Vertebra prominens	89
39.	A dorsal vertebra	90
40.	Peculiar dorsal vertebræ	90
41.	A lumbar vertebra	91
42.	The sacrum, anterior surface	93
43.	The sacrum, posterior surface	95
44.	The hyoid bone	97
45.	The sternum and costal cartilages	98
46.	The peculiar ribs	101
47.	The osseous thorax	104
48.	The left clavicle, upper surface	105
49.	The left clavicle, under surface	106
50.	The scapula, posterior surface	108
51.	The scapula, anterior surface	109
52.	The humerus, anterior surface	111

FIG. PAGE
53. The humerus, posterior surface 113
54. Radius and ulna, anterior surface 115
55. Radius and ulna, posterior surface 117
56. Carpus, metacarpus, and phalanges, dorsal surface 120
57. Carpus, metacarpus, and phalanges, palmar surface 123
58. Os innominatum, outer surface 126
59. Os innominatum, inner surface 128
60. The pelvis 132
61. The axis of the pelvis 132
62. The femur, anterior surface 134
63. The femur, posterior surface 135
64. Section of the head of femur 136
65. The patella 137
66. The tibia and fibula, anterior surface 139
67. The tibia and fibula, posterior surface 141
68. Tarsus, metatarsus, and phalanges, dorsal surface 142
69. Tarsus, metatarsus, and phalanges, plantar surface 146
70. Diagram of cartilages 150
71. Temporo-maxillary articulation 153
72. Sacro-ischiatic articulation 158
73. Ligaments about shoulder-joint 160
74. Ligaments about elbow-joint 161
75. Vertical section through hip-joint 166
76. Knee-joint ligaments 167
77. Knee-joint ligaments, internal 167
78. Muscular tissue 173
79. Unstriped muscular tissue 174
80. Muscles of the head 177
81. Muscles of the orbit 179
82. Muscles of the face 181
83. Temporal muscle 183
84. Pterygoid muscles 184
85. Muscles of the neck 186
86. Constrictor muscles of pharynx 189
87. The diaphragm 193
88. Muscles of the back 195
89. Muscles of the abdomen 202
90. Transverse section of abdomen, showing fascia 204
91. Muscles of the shoulder and arm 207
92. Triceps 207
93. Posterior muscles of forearm 211
94. Extensor tendons of hand 212
95. Flexor tendons of hand 214
96. Muscles of the thigh, anterior region 217
97. Adductor muscles of thigh 219
98. Deep muscles of the gluteal region 220
99. Muscles on posterior femoral region 222
100. Anterior muscles of leg 223
101. Posterior muscles of leg 225
102. Second layer of muscles of foot 227
103. Muscles of the perineum 230
104. Diagram of the circulation 232
105. The aorta 235
106. Circle of Willis 237
107. Axillary artery 240
108. Arteries of face and neck 244
109. Internal maxillary artery 245
110. Abdominal aorta 248
111. Diagram showing the cerebral sinuses in profile 258

FIG. PAGE
112. Diagram showing the cerebral sinuses of the dura mater 259
113. Lymphatics of the head and neck 266
114. Lacteals during intestinal digestion 268
115. Nerve-fibres 270
116. Ganglionic cell and branching fibres 271
117. Structure of nerve-elements 272
118. Diagram of brain 274
119. The sinuses of the dura mater 277
120. Section through the cortex of a frontal convolution 280
121. Left side of human brain 281
122. Orbital surface of the left frontal lobe 283
123. Left hemisphere of brain, showing island of Reil 284
124. Convolutions of the median aspect of the right hemisphere 285
125. Base of brain 287
126. Centrum ovale majus 290
127. Transverse section of brain through the basal ganglia 291
128. Vertical section of the brain 294
129. Horizontal section of the brain, showing third ventricle 296
130. Floor of the fourth ventricle 298
131. Medulla oblongata, pons, cerebellum, and crura cerebri 300
132. The cerebellum, upper surface 301
133. The cerebellum, lower surface 302
134. Spinal cord and nerves 303
135. Section of spinal cord and membranes 304
136. Diagram showing the relations of the spinal nerves to the motor, sensory, and reflex areas of the body 305
137. Transverse section of spinal cord 306
138. Transverse section of spinal cord, showing structure of gray and white matter 307
139. The foramina of exit for the cranial nerves 309
140. Nerves of the face and head 315
141. Digital nerves 328
142. Diagram of the spinal sympathetic system and connections 331
143. Diagram of the heart 335
144. Right auricle and right ventricle laid open 336
145. Arrangement of muscular fibres around the auricles and great veins 337
146. Base of the heart, auricles removed 341
147. Course of the muscular fibres of the heart 342
148. Vertebral section of larynx 343
149. The human glottis 345
150. Heart and lungs 348
151. Two clusters of air-cells 349
152. Temporary teeth 351
153. Permanent teeth 352
154. Diagram of premolar tooth 353
155. Upper permanent teeth in position 356
156. Section through a canine tooth 358
157. Enamel prisms 359
158. Section of a salivary gland 363
159. Pharynx laid open from behind 364
160. Pharynx, median section 365
161. The abdomen 367
162. Vertical section, showing arrangement of peritoneum 369
163. Glands of the fundus of stomach 372
164. Section of intestine, showing villi 375
165. Transverse section of lobules of liver 381
166. Section of the kidney 385
167. Section of Malpighian pyramid 386
168. Diagram of the course of uriniferous tubules 387

FIG. PAGE
169. Blood-vessels and tubules of kidney 388
170. The secretory portions of the kidney 389
171. Spermatozoa 400
172. The vulva 403
173. Section of the pelvic organs 405
174. Uterus and appendages 406
175. Section of uterus and appendages 407
176. Section of uterus through ostium internum 408
177. Section of an ovary 410
178. Diagram of a horizontal section through eye 413
179. Diagram of the formation of retina 417
180. Vertical section of retina 418
181. Layers of the retina 419
182. External, middle, and internal ear 423
183. The pinna 423
184. Left tympanum and auditory ossicles 424
185. Diagram of outer surface of membrana tympani 425
186. Middle ear and ossicles 427
187. The labyrinth 429
188. Scheme of the labyrinth 430
189. Scheme of the organ of corti 431
190. Apparatus of the cochlea 432
191. Structure of the gustatory organs 434
192. Section of the skin 437
193. Epithelium 438
194. Lymphatics of head and neck 442
195. Muscles of neck 444
196. Dissection of axilla 449
197. Structures of the perineum 451
198. Dissection for inguinal hernia 457

PRACTICAL ANATOMY.

OSTEOLOGY.

BONE.

BONE is the hardest structure in the human body, with the exception of the teeth. It is composed of one-third organic and two-thirds inorganic matter. The following table represents practically their relative proportions:—

ORGANIC MATTER:	Gelatin and blood-vessels,	33 parts.
INORGANIC MATTER:	Calcium phosphate, . . .	51 parts.
	Calcium carbonate, . . .	12 parts.
	Calcium fluoride, . . .	2 parts.
	Magnesium phosphate, .	1 part.
	Sodium chloride, ...	1 part.

Externally, bone is pinkish white in color, while within it is of a deeper red. It is covered with periosteum, a fibrous, investing membrane, from which it derives the vessels which supply it with nutrition. Bone is also tough and somewhat elastic; more so in infants than in young adults; while in old age it becomes brittle. An analysis of the bones of the growing skeleton shows that they have a much higher percentage of organic matter and less of earthy than the skeleton of a vigorous adult, while in old age the organic matter is decidedly decreased and the inorganic or mineral matter correspondingly increased. The proportion between the organic and inorganic matter differs also in the same skeleton; thus, in the petrous portion of the temporal bone there is an excess of earthy matter,

while the hyoid bone and lower ribs contain a larger percentage of organic matter than the average. The specific gravity of bone varies, the average being near 1.85.

On section, bone is seen to be composed of two kinds of tissue,—an outer dense portion, or compact bone, and an inner portion, which is loose, spongy, and cancellous. An examination of the compact tissue by means of a suitable lens demonstrates that it is exceedingly porous; in fact, the difference between the compact and cancellous tissue is largely one of condensation. These two tissues are found in different amounts in different bones, according to the requirements of the structures into which they enter. Thus, where great bulk and little weight are important, the spongy tissue predominates, surrounded by a shell of compact tissue, which is always on the exterior. If a living bone is cut, it bleeds, owing to the free vascular supply derived from the periosteum; this is especially the case in the growing skeleton, where the osseous circulation is very active. The blood-vessels which enter the bone penetrate at all points on its surface, and then run in minute canals in the substance of the bone. If the periosteum is destroyed, either by disease or injury, caries always, and necrosis sometimes, results.

MINUTE ANATOMY OF BONE.

If a thin, transverse section of a long bone is examined through a $\frac{1}{4}$ or $\frac{1}{5}$ objective, its structure is clearly brought into view. Large, round openings are observed, which are the cut ends of the Haversian canals, and around these are clustered concentrically minute, dark, oval cavities, called lacunæ. A number of fine canals are seen, passing from lacuna to lacuna, and from these to the Haversian canals. They are known as the canalic-

uli calciferi. They are exceedingly fine tubules, and aid in the distribution of the pabulum of the bone. This arrangement of the Haversian canals, lacunæ, and canaliculi is known as the Haversian system, and is most perfectly developed in the long bones. It is, however, also found in the other bones, and even in the fibres and lamella of the spongy tissue, where the thickness of the plates is at all considerable. As the Haversian canals run parallel with the long axis of a bone, therefore a longitudinal section will show the Haversian canals as laid open, and they appear as grooves, at the sides of which the lacunæ are arranged in rows or lamellæ. Passing between the lacunæ, and from them to the Haversian canals, are the canaliculi, as in a transverse section. The Haversian canals frequently divide or branch, rarely running farther than for a distance of two or three lines without bifurcating or receiving a branch of communication. They vary in size from $\frac{1}{1000}$ to $\frac{1}{200}$ inch in diameter. Now and then a large canal is seen, but is then partly filled with marrow. These canals serve for the transmission of the blood-vessels and lymphatics, and also for a few nerves, principally branches of the sympathetic. Spinal nerves, when traced into bone, are, as a rule, distributed to the articular extremities. The lacunæ are minute cavities hollowed out in the bone-substance. They are ovoidal in form, somewhat flattened or compressed, and average in length $\frac{1}{1800}$ inch, in width $\frac{1}{3600}$ inch, and in depth $\frac{1}{5000}$ inch. They are formed, as are all other spaces in bone, by absorption, and lodge a cell with numerous processes.

The following diagram represents the relation of the lacunæ to each other, and, as is seen, they are simply chambers for the lodgment of multipolar cells, each pole or process lying in a canaliculus and anastomosing

here and there with the processes of the cell in the adjoining lacuna. The canaliculi are extremely fine tubules, which, as a rule, do not exceed $\frac{1}{1200}$ inch in length, and which measure from $\frac{1}{20000}$ inch to $\frac{1}{12000}$ inch in diameter. If a bone is macerated in dilute nitric acid, the mineral matter it contains is dissolved out, the bone loses its rigidity, and becomes pliable and compressible, although it retains its original form. Any long,



FIG. 1.—LACUNÆ AND CANALICULI.
(The lacunæ contain the bone-corpuscles.)

thin bone thus treated can be tied in a knot. If a section is made of a macerated bone, it is found to retain its grosser histological characters, but the canaliculi are indistinct and not readily discerned. There are, however, some further points clearly brought into view. The fibrous structure of the bone becomes apparent, and, as the bone was originally molded in fibro-cartilage, the fibrous elements are seen forming primary and secondary lamellæ. A primary lamella is the arrangement of the

longitudinal fibrous elements around the Haversian canals. The secondary lamellæ are the fibrous structures disposed around the axis of the bone; they are formed, as the bone grows in thickness, by deposits beneath the periosteum. Transverse fibres, known as the perforating fibres of Sharpey, pass through the lamellæ, pinning them together. If a bone is carefully burned until all the organic matter has been destroyed, it will, as in the case of the macerated bone, retain its general form, even to minute anatomical points, proving the uniform distribution or diffusion of the earthy and animal matter throughout the bone. A bone thus treated is brittle, and readily crumbles under the weight of the hand.

Filling the alveoli of spongy bone, and contained within the medullary cavities of long bones, is a substance known as marrow. It is of two kinds,—the red and the yellow. The former is found in all the bones in fœtal life and in the bones of the skeleton of the infant. In the adult, all contain the red marrow except the long bones,—those provided with medullary cavities; in these the marrow is yellow and of the consistency of soft cheese. Red marrow is a sticky fluid which contains 25 per cent. of solids, in which there is a trace of fat. In it are found large multinucleated cells, giant cells, supported by a delicate skeletal net-work of connective tissue. Corpuscles resembling leucocytes are also observed, as are also red blood-corpuscles. As red marrow has been proven to be a blood organ, it is not extravagant to assume that the changes in the corpuscular elements which have been described by some writers are in reality the stages in the transformation of the white into the red blood-corpuscles. The yellow marrow consists almost entirely of fat, nearly 96 per cent., and subserves, probably, the ordinary processes of nutrition. Bone is

supplied with nutrition through branches of blood-vessels which ramify in the periosteum. They enter the bone through minute foramina on its surface, and run in the Haversian canals. They are especially abundant about the articular extremities, where the foramina are numerous and large. The veins which run in the bone are, as a rule, attached to the sides of the canals, and remain patulous on section. This is particularly observed on section of the cranial bones. The nutrient artery of a bone does not supply nutrition to the bone itself, but enters the medullary cavity, to the contents of which it is distributed.

The periosteum is a fibrous membrane which closely invests the bone except at the articular surfaces. It consists of two layers,—an outer areolar and an inner dense layer. In young life it is pinkish in color, thick and vascular, but, as age advances, it becomes yellowish, less vascular, quite thin, and adheres very tightly to the bone. At the points of the insertion of tendons the fibres of the periosteum blend with those of the tendon. The periosteum is not only the investing vascular membrane of the bone, but also a bone organ. In the growing bone its under surface is soft and granular and contains an abundance of osteoblasts, active in increasing the diameter of the bone; nerves are distributed to it freely.

DEVELOPMENT AND GROWTH OF BONE.

An examination of the skeleton of an embryo shows that certain bones, such as those of the long and short varieties, consist primarily of cartilage, while others, such as the flat bones of the skull, are developed between two membranes, without a pre-existing cartilaginous mold. Hence we speak of two forms of ossification, —intra-cartilaginous and inter-membranous. As the

fœtus grows its bones increase not only in length, but also in diameter, and this is accomplished by the deposition of bone from the under surface of the periosteum, and constitutes another form of ossification known as the subperiosteal. The bone is deposited in layers, forming the secondary lamellæ already described. The point at which bone-tissue is first deposited is called the centre of ossification, the earliest evidence of which is a marked vascularity, followed by more or less calcification. In intra-cartilaginous ossification a general cellular activity is observed; the cartilage-cells increase in number by a process of fission, elongate, arrange themselves with their long axes transverse to the long axis of the bone, and in parallel rows. In the matrix, or cartilage, in which the cells are imbedded, lime-salts are freely deposited, destroying the transparency of the section, and, if the process of ossification is to be further observed, the section must be treated with an acid to dissolve out the obscuring mineral salts. As they approach the area of ossification the cartilage-cells swell in size, become ovoidal in shape, and their capsules, as well as the surrounding matrix, become infiltrated with lime-salts. They contain a dark, granular matter, called primitive marrow, and are lined with rounded or cuboidal cells. Dipping down from the vessels of the perichondrium are small blood-vessels, which advance and penetrate the cartilage. They invade the large cells just described, which, by a process of absorption, begin to communicate, forming canals and spaces lined by layers of rounded cells continuous with the cells beneath the perichondrium. These cells are of the greatest importance; some are concerned in the formatien of marrow, while others become the osteoblasts described by Gegenbauer.

It must be remembered that the formation of bone is not a simple process of calcification, but the result of the functional activity of the osteoblasts. The formation of all the spaces and canals in cartilage and bone is due to absorption. The canals formed by the process described are known as medullary sinuses, and are lined by osteoblasts and medullary cells. Through the agency of the osteoblast, layers of bone begin to encroach concentrically upon the medullary sinuses, forming the primary lamellæ surrounding the Haversian canals, which these medullary sinuses ultimately become.

The formation of the lacunæ and canaliculi is not definitely settled. Briefly, the process is probably as follows: The medullary sinuses or canals, as previously stated, are lined by layers of osteoblasts, from three to seven deep. The peripheral layer undergoes bony transformation, and then the next, and thus layer after layer ossifies, forming the concentric lamellæ of the Haversian system. The nucleus of the osteoblast resists the change described, although the cell-wall and contents in part undergo ossific transformation. The nucleus remains as a space or cavity, which is gradually fashioned into a lacuna. The formation of the canaliculi is not understood, although it is probable that the contents of the osteoblasts are not entirely absorbed, but that delicate fibres of protoplasm remain, radiating from the nucleus and communicating with the adjoining cell, and that these fibres ultimately become the canaliculi. In the inter-membranous form of ossification, the first evidence is the formation of a vascular centre, from which rays of fibro-cartilaginous material issue. This material is calcified, and then passes through the process of ossification already described.

THE SKELETON.

The skeleton is that arrangement of bones which supports the soft structures of the body. It consists, in the adult, of 200 bones, as follows:—

Head	Cranium,	8	22
	Face,	14	
Vertebral column, including sacrum, and coccyx,			26
Upper extremities,			64
Ribs, sternum, and os hyoides,			26
Lower extremities,			62
			200

The bones are divided into four classes,—long, short, flat, and irregular. A long bone presents a shaft, two extremities, and has a medullary cavity. The shaft is cylindrical or prismatic, hollow, filled with yellow marrow, contained within a delicate investing membrane called the endosteum, which lines the medullary cavity. It is a hollow cylinder of compact tissue, which becomes thinner toward the extremities; these are expanded and bulky, and serve for articulation. About the centre of a long bone is the nutrient foramen; it enters the medullary canal and transmits an artery to the marrow. The direction of the nutrient foramen and canal is different in different bones: in the long bones of the upper extremities it is directed toward the elbow-joint; in the femur, toward the hip-joint; and in the bones of the leg, toward the ankles.

A short bone is thick, irregular, cuboidal, and consists of a shell of compact bone inclosing spongy tissue, the alveoli of which are filled with red marrow. The short bones are those of the tarsus and carpus.

A flat bone is plate-like in form, and consists of two tables of compact bone held together by cancellated tissue. In the bones of the skull the tables of the flat

bones are of different degrees of density; the outer table, less dense, is tough and elastic; the inner is denser and harder, and consequently brittle. The flat bones are used mainly for protection, and also afford broad surfaces for muscular attachment.

Irregular bones are extremely irregular in outline, and commonly consist of a shell of dense bone inclosing spongy tissue, the interstices of which are filled with red marrow.

Bones present certain points for examination,—elevations and depressions, ridges and grooves, surfaces, lines, foramina. A blunt elevation is called a tubercle or tuberosity; a depression may be slight or pit-like or deep, or shallow and extensive, when it is designated a fossa. Ridges may be rounded or sharp; in the latter case they are called crests. Grooves may be shallow, as the musculo-spiral groove on the humerus, or deep. Surfaces may be rough or smooth. Lines may be rough, sharp, spiral, or broad. Besides these, a number of other terms are employed: thus, the spine is a sharp, thorn-like process; a trochanter, a huge blunt elevation for the attachment of muscles; condyles are oblong elevations of bone covered with cartilage, arranged in pairs; an articular surface is a plane, of more or less extent, covered with cartilage. In the growing skeleton the shafts of many bones are separated from their extremities by layers of cartilage; such an extremity constitutes an epiphysis, which remains separated from the shaft until both have attained their full development, when the layer of cartilage ossifies. Where a blunt process of bone grows out from the shaft it is called an apophysis. If the extremity of a bone forms a single rounded prominence, covered with cartilage, it is called a head; a constriction just below the head of a bone is known as the neck.

THE SKULL.

The skull is formed of twenty-two bones; of these, eight enter into the formation of the cranium and fourteen into the construction of the face. The bones of the cranium are arranged singly and in pairs. The single bones are the frontal, ethmoid, sphenoid, and occipital; those in pairs, the parietal and the temporal.

THE FRONTAL BONE.

The frontal bone is located at the anterior part of

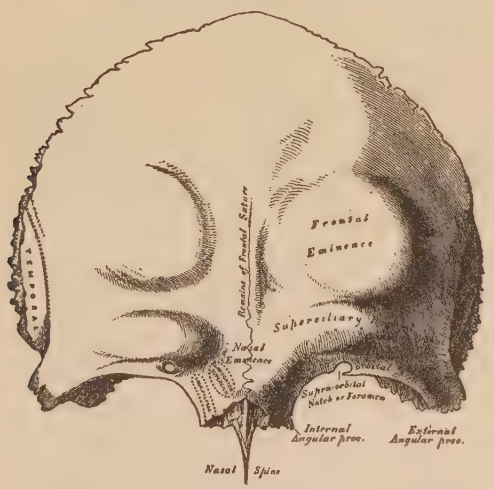

FIG. 2.—FRONTAL BONE, OUTER SURFACE.

the cranium and forms the forehead. It consists of a vertical and horizontal portion. The vertical portion is convex from side to side and from above downward; midway between its superior and inferior border, on each side of the median line, are two rounded elevations, known as the frontal eminences, the bases of which, in well-marked specimens, are about the size of a silver half-dollar; below these, directed horizontally outward, are the rounded superciliary ridges which mark the

position of the frontal sinuses; below these are the supra-orbital ridges, where the vertical and horizontal portions join. These ridges present at their inner third a notch or foramen, known as the supra-orbital, and which transmit the supra-orbital nerve and artery. The ridges terminate externally in well-marked processes of bone, known as the external angular processes, which are serrated for articulation with the frontal process of the malar; internally, they approach one another and terminate in the internal angular processes, also serrated for articulation, with the superior maxillary and nasal; they are separated by a mass of bone, slightly elevated, from one-half to three-quarters of an inch in breadth, and known as the glabella. The supra-orbital ridges are strongly arched, and assist in forming the rim of the orbits. Passing down midway, dividing the bone into halves, is the remains of the frontal suture, well marked in young bones. It indicates the line of union of the two halves of the bone. The superior border of the frontal bone is strongly indented and toothed for articulation with the parietal bones; laterally it is beveled for articulation with the great wing of the sphenoid. Passing upward and backward, in a curved direction from the external angular process, is the commencement of the temporal ridge. The process of bone posterior to the ridge forms an angle with the vertical portion, and assists in the formation of the temporal fossa. Projecting downward midway from between the internal angular processes is the nasal spine, which articulates in front with the posterior borders of the nasal bones, and behind with the anterior border of the ethmoid. The inner surface of the vertical portion is concave in every direction, and presents a number of shallow depressions for the accommodation of the convolutions of the brain. Besides these,

there are some sharp, pit-like depressions which lodge the Pacchionian glands,—small fibrous bodies developed on the outer surface of the dura mater. Running along the middle line from the superior border to a pit in front of the ethmoidal notch is the frontal crest, which gives attachment to the falx cerebri and lodges the longitudinal sinus. The horizontal portion consists of two orbital plates, separated by a deep, broad notch,—the ethmoidal. These plates present for examination inferior and superior sur-

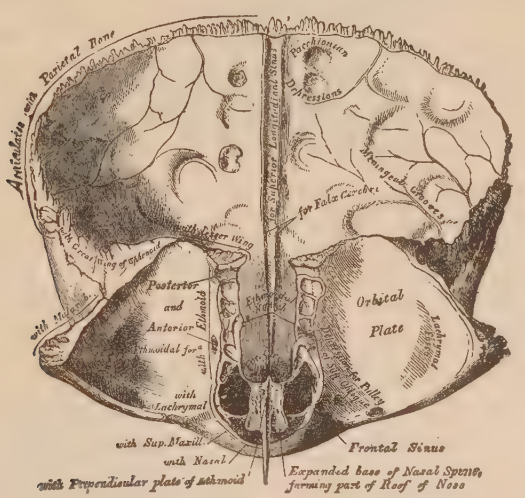

FIG. 3.—FRONTAL BONE, INNER SURFACE.

faces, posterior and ethmoidal borders. The inferior surface is strongly concave and smooth, the superior slightly convex and marked by the convolutions of the brain. Just within the external angular process is a shallow depression which lodges the lachrymal gland. Behind the internal angular process is a small tubercle, sometimes a depression which gives attachment to the pulley of the superior oblique muscle. The orbital plates are thin and translucent, consisting of compact tissue only. The posterior border articulates with the lesser wing of the

sphenoid; the ethmoidal border, thickened and cellular, articulates with the ethmoid. Two shallow grooves are observed traversing this border, one anterior and one posterior, and which, when articulated with the ethmoid, form the anterior and posterior ethmoidal foramina. Along the anterior part of the ethmoidal border large openings are observed, which lead into almond-shaped cavities behind the supra-orbital ridges. These cavities are the frontal air sinuses, and are separated from each other in the median line by a plate of bone. They are formed by the divergence of the tables of the frontal bone; on a vertical section they appear triangular; their largest diameter is horizontal. The superior border of the frontal articulates with the two parietal bones and the greater wing of the sphenoid; the external angular process with the malar; the internal angular process with the nasal and superior maxillary. The frontal bone develops from two centres, which appear near the centre of the frontal eminences. These centres first appear about the third month of fœtal life.

THE PARIETAL BONES.

The parietal bones, two in number, are located at the sides and vault of the skull behind the frontal bone. They articulate with each other at the vertex of the skull, and form the interparietal or sagittal suture. Each bone has four borders, four angles, and two surfaces, and is traversed from the anterior to the posterior border by a curved line, the temporal ridge, continuous with the temporal ridge on the frontal bone. The temporal ridge divides the external surface into two portions, the upper and lower, the upper surface being the larger and smooth, the lower surface the smaller and marked by faint irregularities and minute foramina; it assists in form-

ing the temporal fossa. Near the upper posterior angle

FIG. 4.—PARIETAL BONE, OUTER SURFACE.

is a foramen, the parietal, which transmits a vein to the longitudinal sinus. About the centre of the bone is the

FIG. 5.—PARIETAL BONE, INNER SURFACE.

parietal eminence. The inner surface is impressed by

the convolutions of the brain, and also presents several grooves, which are best marked and most constant near the anterior inferior angle. The grooves lodge the middle meningeal artery and its branches. The superior border is slightly beveled at the expense of the inner surface, and, when the bones are articulated, it assists in forming a groove which lodges the continuation of the superior longitudinal sinus. Depressions for the Pacchionian bodies are also observed. The superior border articulates with its fellow in the middle line of the skull, forming a deeply serrated and denticulated suture. The anterior border articulates with the frontal bone by tooth-like processes, which firmly interlock with similar processes of the frontal bone. The anterior inferior angle, with part of the inferior border, articulates with the great wing of the sphenoid. The inferior border is concave, and is beveled on its outer surface to articulate with the squamous portion of the temporal; posteriorly the inferior border articulates with the mastoid portion of the temporal bone. The posterior border articulates with the occipital by means of well-marked dentate processes. The parietal bone develops from one centre, which appears about the third month.

THE OCCIPITAL BONE.

The occipital bone is situated at the back and base of the skull. It is strongly curved, forming an arch of about one-third of a circle. Viewed posteriorly it is diamond-shaped. It presents for examination two superior lateral and two inferior lateral borders, an external and an internal surface, and a basilar process. The superior borders meet above at the apex of the bone, and articulate with the posterior borders of the parietal bones by means of tooth-like processes. The inferior borders

articulate with the temporal bones; the upper half with the mastoid portion, the lower half with the petrous part of the temporal bone. The upper half merely abuts against the mastoid portion; the lower half has projecting a well-marked process of bone—the jugular process—which articulates with the jugular surface of the petrous portion of the temporal. Anterior to the jugular process is the jugular notch, which, with the jugular fossa on the petrous portion of the temporal, forms the

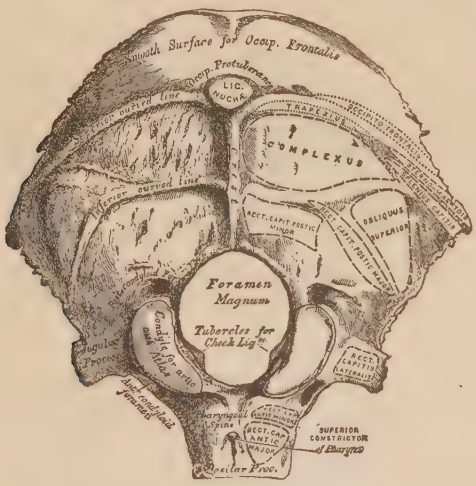

FIG. 6.—OCCIPITAL BONE, OUTER SURFACE.

jugular foramen for the transmission of the lateral sinus down the neck. The inferior lateral borders are separated anteriorly by a thick quadrilateral process of bone, the basilar process, which, in the developing skeleton, articulates with the sphenoid, but after the twenty-fifth year the layer of cartilage between them ossifies and the occipital and sphenoid form one bone. The outer surface is convex, and midway between the apex and foramen magnum presents the external tuberosity for the attachment of the ligamentum nuchæ; branching out

from each side of this are the superior curved lines. Running from the tubercle to the foramen magnum is a sharp ridge of bone, the external crest, from which passes, midway between the superior curved lines and the foramen magnum, the inferior curved lines. The bone above the superior curved lines is smooth; below it is rough, for the attachment of muscles. At the junction of the posterior portion with the basilar process is the foramen magnum, which transmits the spinal cord some nerves, vessels, and membranes. This opening is oval in outline, the larger part of the oval being posterior; viewed internally, it appears larger than when looked at from the outer surface. Placed at each side, anterior to its transverse diameter, are the occipital condyles, which approach each other anteriorly, their axes crossing about one inch in front of the foramen magum; they serve for articulation with the atlas. In front of each condyle is the hypoglossal foramen for the transmission of the hypoglossal nerve. This foramen is always present, and is of large size. Behind the condyle a foramen is often found, known as the posterior condyloid; it transmits a vein to the lateral sinus.

The inner surface of the occipital bone is concave, slightly impressed by the convolutions of the brain, and is divided into four shallow fossæ by the occipital cross, the vertical limb of which affords attachment to the falx cerebelli and falx cerebri; it lodges the superior longitudinal sinus. The horizontal limbs give attachment to the tentorium cerebelli and lodge the lateral sinuses. At the point at which they cross, the longitudinal and lateral sinuses meet, forming the torcular Herophili. The superior fossæ lodge the posterior lobes of the brain; the inferior fossæ, the cerebellum. The superior surface of the basilar process is smooth, con-

cave from side to side, and ascends from the foramen magnum. It lodges the medulla oblongata. The inferior surface is rough, for muscular attachment; it presents the pharyngeal spine, which is not, as a rule, prominent, but affords attachment to the raphe of the pharynx. At the sides of the anterior part of the foramen magnum are small tubercles for the attachment of the check ligaments. The inner aspect of the bone is beveled as it approaches the foramen magnum, and pre-

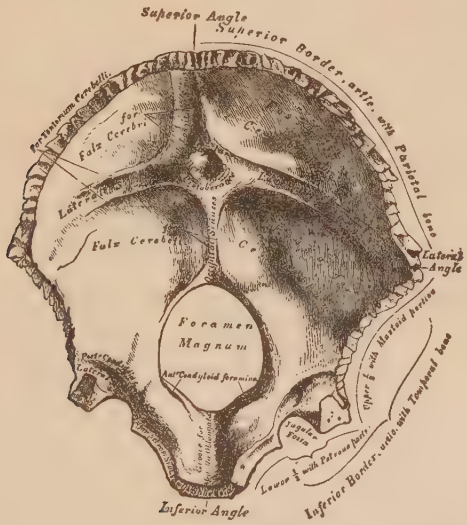

FIG. 7.—OCCIPITAL BONE, INNER SURFACE.

sents on each side the anterior condyloid or hypoglossal foramen. The jugular process and a portion of the inferior lateral border are grooved for the lateral sinus.

The occipital bone develops by four centres, one for the posterior part, one for each condyle, and one for the basilar process; these centres appear about the second month. It belongs to the class of flat bones. At birth it consists of four pieces, which ossify to form a single bone about the sixth year.

THE TEMPORAL BONES.

The temporal belong to the class of irregular bones. They are situated at the sides and base of the skull, and present three portions,—the squamous, mastoid, and petrous. The squamous portion is a thin plate of bone, which presents for examination an inner and outer surface and a border. At its superior part the border is convex, beveled at the expense of its inner surface, and articulates with the inferior border of the parietal. The

FIG. 8.—LEFT TEMPORAL BONE, OUTER SURFACE.

anterior and inferior part of the border articulates with the sphenoid. The squamous portion is translucent; it is composed of dense bone, and contains no diploic structure. Its outer surface, smooth and slightly convex, presents some shallow grooves for the deep temporal arteries. It assists in forming the temporal fossa, which is limited posteriorly by the temporal ridge, separating the squamous from the mastoid portion. Projecting horizontally forward from the lower and posterior part of the squamous portion is the zygomatic process, the

extremity of which is serrated for articulation with the malar bone. The zygoma arises from the side of the temporal bone by three roots. The posterior root is the temporal ridge; the middle root passes down in front of the external auditory meatus, limiting the glenoid fossa posteriorly; the anterior root forms a well-marked tubercle, which passes downward and inward in front of the glenoid fossa, and becomes lost in the eminentia articularis. The superior border of the zygoma is long, thin, and sharp, and has attached to it the two leaflets of the temporal aponeurosis. The inferior border, shorter than the superior, thick and rounded, forms two arches, the first between the extremity and the tubercle. This arch affords attachment to the masseter muscle. The second arch, deeper and much shorter than the first, is between the anterior and the middle roots of the zygoma, and assists in forming the roof of the glenoid fossa.

The internal surface of the squamous portion is marked by depressions for the convolutions of the brain, and grooved along its posterior portion by the middle meningeal artery.

The mastoid portion is behind and below the temporal ridge. It articulates superiorly with the parietal bone, and posteriorly with the occipital. Its borders are broad and blunt, posteriorly slightly serrated. It is a rough, bulky process of bone, terminating inferiorly in a tubercle called the mastoid process. In the posterior border is the mastoid foramen, which is sometimes placed in the suture between the mastoid portion and the occipital bone. The inferior portion of the mastoid process presents two grooves upon its inner face. The external, or digastric, is for the attachment of the digastric muscle; the inner groove not so strongly marked,

is for the passage of the occipital artery. A section of the mastoid process shows that it is cellular, and its cells, which communicate with the tympanum, are lined by a continuation of the tympanic mucous membrane. The inner surface of the mastoid portion is deeply grooved for the passage of the lateral sinus. In front of the mastoid portion, and behind the middle root of the zygoma, is the trumpet-shaped opening of the external auditory meatus, surrounded by a rough ring of bone, the auditory process, to which is attached the external ear. The external auditory meatus is a canal which passes slightly downward and forward to the tympanum, from which it is separated by the membrana tympani. The length of this canal in the bone is about three-fourths inch. It is about one-fourth inch in diameter. The glenoid fossa is a deep cavity in front of the external auditory meatus. It is bounded anteriorly by the tubercle of the zygoma and the eminentia articularis; posteriorly, by the middle root of the zygoma and the vaginal process; internally, by the vaginal process and the eminentia articularis. It is about three-fourths inch in depth, one-half inch antero-posteriorly, and is crossed obliquely from behind, forward and downward, by the Glasserian fissure, which begins just below the middle root of the zygoma, and passes downward and forward to the angle between the petrous and squamous portions of the temporal bone. It communicates with the tympanum, transmits the laxator tympani muscle and the tympanic branch of the internal maxillary artery, and lodges the processus gracilis of the malleus. The canal of Huguier is just in front of the Glasserian fissure, and transmits the chorda tympani nerve. The roof and posterior wall of the glenoid fossa are translucent, and can be readily crushed in by a force projected

against them. A penetration of the roof of the Glasserian fissure will enter the cranial cavity, and may injure the inferior surface of the temporo-sphenoidal lobes of the brain. The posterior wall is a frail partition, formed by the vaginal process. It separates the glenoid fossa from the external auditory canal.

The petrous portion of the temporal bone is not seen at the side of the skull. It springs from the inner surface of the temporal bone, and projects forward and in-

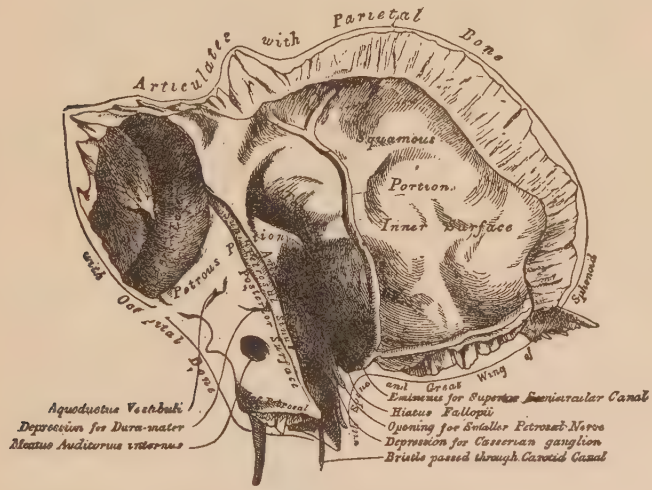

FIG. 9.—LEFT TEMPORAL BONE, INNER SURFACE.

ward, forming an angle of 35 degrees with the squamous portion of the bone. In shape, it is the frustum of a trilateral pyramid lying upon its side. Its base is applied to the inner surface of the squamous and mastoid portions. It presents for examination an anterior, a posterior, and an inferior surface, and an apex. The anterior is smooth and polished, and presents, near its junction with the squamous portion, an elevation which marks the position of the superior semi-circular canal. Below this is a depression, beneath which is the tym-

panum; the bone separating the tympanum from the cranial cavity is very thin and translucent. Internal to this is the hiatus Fallopii, which transmits the large petrosal nerve. A smaller opening frequently exists for the transmission of the smaller petrosal nerve, another branch of the facial. Near the apex is a depression, about the size of a lentil, which accommodates the ganglion of Gasser. The bone at the apex is slightly

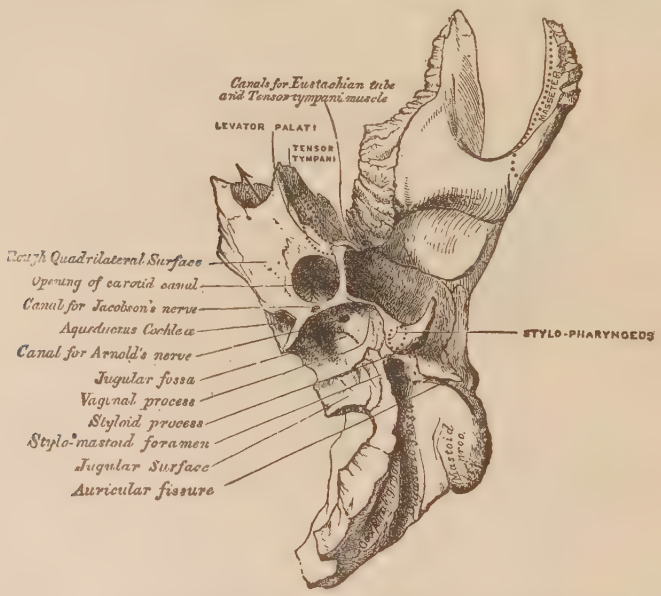

FIG. 10.—LEFT TEMPORAL BONE, INFERIOR SURFACE OF THE PETROUS PORTION.

notched, to accommodate the internal carotid artery as it curves into the cranial cavity. At the junction of the petrous and squamous portions is the remains of a suture, which marks the line of separation between the petrous and squamous portions. The posterior surface forms a steeper incline than the anterior, and presents for examination the internal auditory meatus, which is placed about the centre. This canal is about three lines in

diameter and from two to four lines in depth. At the bottom is placed a vertical, cribriform plate, through which the auditory nerve passes to the labyrinth. At the upper part of the vertical plate is a foramen, about the size of a broom-straw. It leads into a canal called the aquæductus Fallopii, and transmits the facial nerve. External to the auditory meatus is a canal called the aquæductus vestibuli, which communicates with the vestibule of the labyrinth and transmits a small vein. A sharp process of bone gives attachment to the dura mater. The inferior surface is very irregular, and presents twelve points for examination. These are placed along the anterior and posterior borders, and a few midway between. Those along the posterior border, beginning at the apex, are: (1) the quadrilateral rough surface; (2) the aquæductus cochlea; (3) the jugular fossa, near the anterior portion of which is seen (4) a foramen which transmits the auricular branch of the pneumogastric nerve. External to the jugular fossa is (5) the jugular surface for articulation with the jugular process of the occipital bone. Along the anterior border, beginning at the apex, we have: the quadrilateral rough surface; (6) the opening of the carotid canal; (7) the vaginal process which passes backward, inclosing (8) the styloid process, posterior to which, and at its base, is observed (9) the stylo-mastoid foramen, the termination of the aquæductus Fallopii; external to the stylo-mastoid foramen is (10) the auricular fissure for the transmission of a branch of the pneumogastric nerve; in the partition between the carotid canal and the jugular fossa is (11) Jacobsen's foramen for the transmission of a branch of the glosso-pharyngeal nerve to the tympanum; in the angle between the petrous and squamous portions is (12) the Eustachian tube, leading

into the tympanum. The quadrilateral rough surface affords attachment to muscles. The aquæductus cochlea transmits a vein from the cochlea, and frequently a small artery is seen entering the canal by the side of the vein. The jugular fossa is deep, and, with the jugular notch on the occipital bone, forms the jugular foramen. The carotid canal passes vertically upward one-fourth inch, then bends at right angles, runs horizontally forward for another fourth of an inch, and terminates at the apex. That part of the anterior surface of the petrous portion overlying the carotid canal is notched for the passage of the artery upward to the base of the brain. A vertical, antero-posterior section of the petrous portion shows that it approaches an equilateral triangle. Its superior border is grooved for the lodgment of the superior petrosal sinus and for the attachment of the tentorium cerebelli. The petrous portion does not contain any spongy tissue. In it is found an excess of the mineral matter. The temporal bone is developed by two principal centres,—one for the zygomatic and squamous part, and the other for the petrous and mastoid portion. The styloid process and the auditory process have each a separate centre. These centres appear near the end of the second month. The temporal bone contains the organs of hearing, which will be described with the ear.

THE SPHENOID BONE.

The sphenoid bone is situated at the base of the skull. It articulates with the orbital plates of the frontal anteriorly, and with the basilar process of the occipital posteriorly. It also articulates with all the other bones of the cranium, binding them firmly and solidly together, and with five bones of the face,—the two malar, the two palate, and the vomer. It presents for exam-

ination a body, two greater wings, two lesser wings, and two pterygoid processes. When viewed from the front it resembles a bat with wings extended. The body is hollow, cuboidal in form, and presents superior, inferior, anterior, and posterior surfaces. The greater and lesser wings spring from the sides of the body. The superior surface from before backward presents the following points: The ethmoidal spine for articulation with the ethmoid; this is a smooth surface of bone, slightly grooved on each side of the median line for the accommodation of the olfactory tracts; anteriorly, it forms a

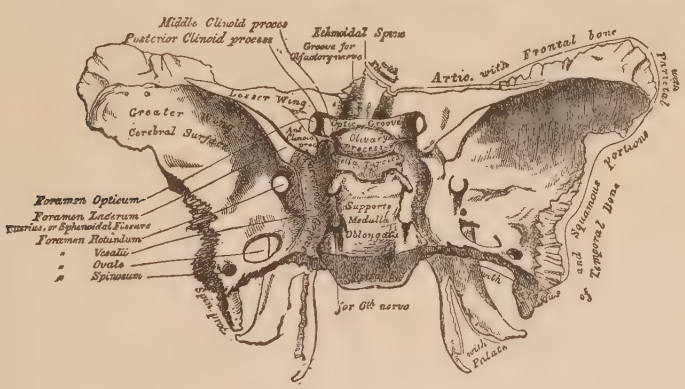

FIG. 11.—SPHENOID BONE, UPPER SURFACE.

spine which is received in an angle at the posterior portion of the ethmoid. This surface is continuous laterally with the upper surface of the lesser wings. Behind the ethmoid spine is the optic groove, which lodges the optic chiasm; it terminates at each side at the optic foramen. Behind the optic groove is the olivary body, an ovoidal mass of bone which slightly overhangs a fossa posterior to it, called the sella turcica, which lodges the pituitary body. At the sides of this fossa, behind the olivary body, are the middle clinoid processes,—slight elevations which give attachment to the dura mater. Overhanging the

sella turcica posteriorly is a plate of bone which terminates at each side in well-marked processes,—the posterior clinoid. This plate is notched at the sides for the passage of the sixth pair of nerves, and is also centrally notched for the accommodation of the infundibulum. The superior surface behind the posterior clinoid processes forms a descending quadrilateral plate of bone, the os planum of the sphenoid, which is continuous with the superior surface of the basilar process of the occipital. It is smooth and polished, and supports the pons Varolii. At its posterior inferior angle it is grooved for the passage of the sixth nerve. At each side of the body the superior surface presents a well-marked groove, slightly sinuous, which lodges the cavernous sinus and the internal carotid artery; it is called the cavernous groove.

The anterior surface presents in the median line a vertical, plate-like process of bone, called the sphenoidal crest. It articulates with the vertical plate of the ethmoid, and assists in forming the septum nasi. The sphenoidal crest is not simply a projection from the surface, but extends into the interior of the body, forming a vertical partition. After the age of puberty the body is hollow, forming the sphenoidal air sinuses. These sinuses are frequently subdivided by other bony partitions, and are lined by a continuation of the Schneiderian mucous membrane of the nose, with which they communicate. On each side of the crest the large, irregular openings of these sinuses are observed. They are largely covered in by small scroll-like bones,—the sphenoidal turbinated. Laterally, the anterior surface articulates with the os planum of the ethmoid; its upper border, with the frontal; its lower, with the orbital process of the palate bone. The inferior surface presents, in the middle line, the rostrum,—a ridge of bone contin-

uous with the crest; it fits in the angle formed by the diverging alæ of the vomer. At each side are curved ridges of bone, called the vaginal processes, for articulation with the alæ of the vomer. Between the vaginal and pterygoid processes is the pterygo-palatine groove, which is formed into a canal by articulation with the sphenoidal process of the palate; it transmits the pterygo-palatine vessels and the pharyngeal nerve. The posterior surface, before the twentieth year, is covered by a layer of cartilage which separates it from the basilar

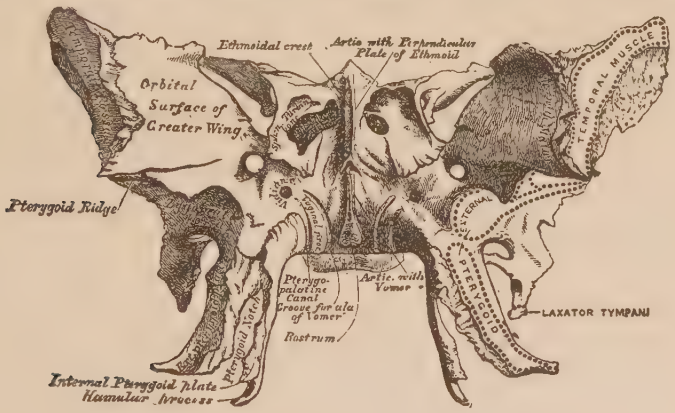

FIG. 12.—SPHENOID BONE, ANTERIOR SURFACE.

process of the occipital. After the twentieth year this cartilaginous plate ossifies, and the sphenoid and occipital form one bone. Projecting from the sides of the upper part of the body of the sphenoid are two thin, sabre-like processes,—the lesser wings. These are placed horizontally, their surfaces looking up and down. The anterior border is serrated for articulation with the orbital plate of the frontal. The posterior border is thin and smooth, and is received in the fissure of Sylvius. It projects at its inner posterior portion, and forms a triangular process of bone called the anterior clinoid

process. Its surfaces are smooth,—the upper polished, —and form part of the floor of the anterior fossa of the skull. The inferior surface, near its junction with the body, is slightly roughened for attachment of the recti muscles. It forms the posterior part of the roof of the orbit and the superior boundary of the anterior lacerated foramen. The lesser wings arise by obliquely-placed and flattened roots, which are perforated by the optic foramina for the transmission of the optic nerves and the ophthalmic arteries. They are frequently considered as arising by two roots each. The greater wings arise from the sides of the body of the sphenoid by broad, flattened roots, and curve upward, outward, and forward. Each wing presents three surfaces,—a superior, an anterior, and an external. The superior surface passes obliquely upward, outward, and forward. Its posterior projecting extremity is called the spine. It is strongly concave from front to back, is smooth, impressed by the convolutions of the brain, and enters into the formation of the middle cranial fossa. At its junction with the body anteriorly, it is pierced by the foramen rotundum,—a round foramen which is directed horizontally forward. Near its junction with the body posteriorly, is the foramen ovale,—an oval foramen, the axis of which is vertical. Near the extremity of the greater wing, posteriorly is the foramen spinosum. These are the principal foramina; in addition, there are some minute foramina for the entrance of vessels into the bone; one of these, between the foramen ovale and the body of the sphenoid, is known as the foramen of Vesalius, and transmits a small vein. The anterior surface of the greater wing is quadrilateral, smooth, slightly concave from above downward, and at its lower posterior part presents one or two small tubercles for the origin of the lower

head of the external rectus muscle; occasionally, the inferior rectus also has a point of origin close to the lower head of the external rectus. One or two small foramina are occasionally observed; they transmit small vessels. The plane of the anterior surface is directed nearly vertically; it looks obliquely forward and inward, and forms the outer posterior wall of the orbit. The external surface is divided by the pterygoid ridge into a superior and an inferior portion. The superior surface forms part of the side of the skull, and is about an inch and a half long by one-half to three-fourths of an inch broad. It is concave from before backward, and assists in forming the temporal fossa. A few small foramina are seen which transmit small, nutrient vessels. The inferior surface extends from the pterygoid ridge to the base of the pterygoid process, and assists in forming the roof of the zygomatic fossa. The pterygoid ridge is about an inch and a half long, and runs from the orbital plate to the spine of the great wing. The upper anterior margin of the greater wing articulates with the frontal; the upper posterior portion articulates with the anterior inferior angle of the parietal. The posterior border articulates with the squamous portion of the temporal. The spine is received into the angle between the squamous and petrous portions of the temporal bone. The anterior border of the orbital surface articulates with the malar.

The pterygoid processes are two strong, somewhat irregular processes of bone, consisting each of two plates of bone joined anteriorly. Each process arises from the under surface of the body and greater wing, and is directed vertically downward. At the base of the pterygoid process is the Vidian canal; it passes horizontally backward above its root. This canal transmits the

petrosal nerve to Meckel's ganglion, which is situated in the spheno-maxillary fossa. The anterior border of the pterygoid process is broad at the base. Passing downward from the Vidian canal is a groove which, in the articulated skull, assists in forming one of the posterior palatine canals. The inner edge of the anterior border is rough, for articulation with the vertical plate of the palate bone. The lower portion of the anterior border is cleft, forming the pterygoid notch, which articulates with the tuberosity of the palate bone. Posteriorly the two plates diverge, the inner being longer, but narrower, than the outer. It terminates in a hook-like process of bone, called the hamular process. The outer plate, broader but shorter than the inner, is directed obliquely backward and outward. Between the plates at the base is a shallow depression, the scaphoid fossa, below which is the pterygoid fossa, bounded externally by the external plate, internally by the internal plate, and in front by the tuberosity of the palate. The pterygoid plates are mainly for muscular attachment. The sphenoid bone develops by ten centres, which appear from the end of the second month to the middle of the third. At birth it consists of three pieces, which do not join before the end of the first year.

THE ETHMOID BONE.

The ethmoid is an irregular bone, and consists of a vertical and a horizontal plate, arranged in the form of a cross, and hanging from the lateral edges of the horizontal plate are the two lateral masses. It is an exceedingly fragile bone about the size of an English walnut. It is placed in the middle line of the skull, and fills the ethmoidal notch of the frontal. It articulates with thirteen bones,—the frontal anteriorly, the sphenoid

posteriorly, and with eleven bones of the face. It is placed between the two orbits, and helps to form the inner wall of each orbital cavity. It also assists in forming the floor of the anterior fossa of the cranium and the roof and sides of the nasal cavities. The vertical portion of the ethmoid above the horizontal plate is a smooth, triangular piece of bone with a sharp edge. It somewhat resembles a cock's crest, and hence is called the crista galli. Its sides are somewhat bulged, and it is frequently hollow, inclosing a small air sinus. It serves for the

FIG. 13.—ETHMOID BONE.

attachment of the falx cerebri. The vertical plate below the horizontal portion is thin, quadrilateral in outline, presenting the anterior superior and inferior borders, the posterior superior and inferior borders, and two surfaces. It assists in forming the septum of the nose, and is generally slightly inclined to one side. It is somewhat roughened and grooved on its surfaces, and presents many minute foramina near its junction with the horizontal plate. The anterior superior border articulates with the frontal and nasal. The triangular cartilage of

the nose is attached to the anterior inferior border. The posterior superior border articulates with the crest of the sphenoid; the posterior inferior, with the vomer. The horizontal plate is perforated on each side of the crista galli with rows of foramina, and is, therefore, called the cribriform plate. It is placed between the two orbital plates of the frontal, filling the ethmoidal notch, and helps to form the anterior fossa of the skull. Its superior surface is narrow and grooved for the olfactory tracts and bulbs. The foramina, fifteen to eighteen in number, are

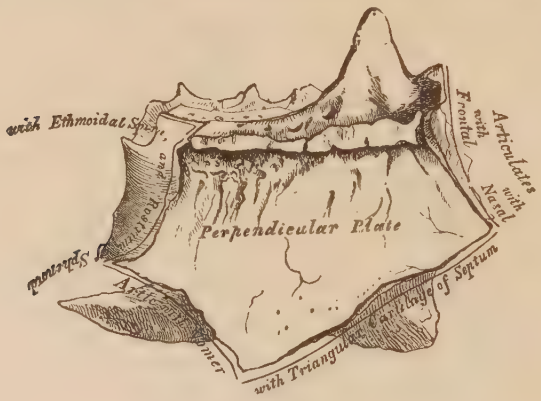

FIG. 14.—ETHMOID BONE.
(Right lateral mass removed.)

arranged in three rows, and transmit the branches of the olfactory nerve to the nose. At the side of the crista galli is the nasal fissure for the passage of the nasal branch of the ophthalmic nerve. Anteriorly the cribriform plate is notched and expanded into two wings, which articulate with the frontal spine, and posteriorly is a deeper notch for articulation with the rostrum of the sphenoid. These articulations form "groove-and-tongue joints" (schindylesis). The lateral masses are pendent from the lateral edges of the cribriform plate. They consist of two vertical masses of thin-walled cells, some of

which, in the disarticulated bone, appear as cavities on the surface, but with similar depressions on the adjoining bone all these broken cells are completed. The lateral mass presents for examination an external and an internal surface, and an anterior inferior and posterior border. The external surface presents a number of broken cells, and a smooth, rectangular plate of bone, the os planum, which forms part of the inner wall of the orbit. This plate, at its upper border, presents two notches, which, with similar notches on the frontal bone, form the anterior and posterior ethmoidal foramina. The os planum articulates along its superior border with the frontal; anteriorly, with the lachrymal; the inferior border, with the superior maxillary; and the posterior, with the sphenoid and the palate. Below the os planum is an unciform or hook-like process of bone, which passes downward and articulates with the superior maxillary, and helps to close the antrum of Highmore. The inner surface of the lateral mass is very irregular. It is rough, and grooved for the passage of branches of the olfactory bulbs. Running obliquely downward and backward from the upper posterior portion is the superior turbinated process (rudimentary in man), while below, at its inferior border, is the middle turbinated process,—a scroll-like, elongated plate of bone, with its convexity presenting upward and inward. The cells of the ethmoid are divided into anterior and posterior, separated by a more or less complete bony partition; they communicate with the frontal and sphenoidal sinuses, and with the nasal fossa.

The ethmoid develops from three centres; one for the vertical plate and one for each of the lateral masses and its attached horizontal portion. The centres first appear about the fifth month.

THE NASAL BONES.

The nasal are two small, quadrilateral, flat bones, which are placed in the middle line of the skull, below the frontal, and form the bridge of the nose. They present for examination four borders and two surfaces. The superior border is short, thick, and serrated for articulation with the internal angular process of the frontal. The inner border is slightly beveled at the expense of its inner surface; it is thicker above than below, and articulates in the middle line with its fellow. The external border is thin and rough and is strongly curved, and articulates with the superior maxillary bone.

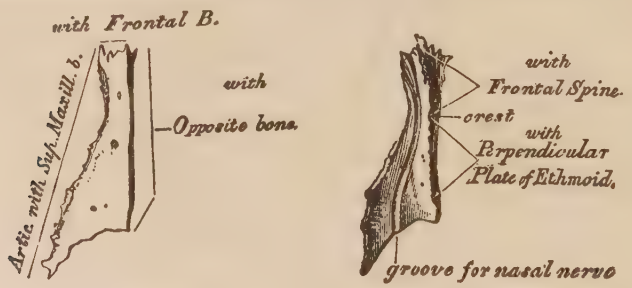

(Outer surface.) (Inner surface.)

FIG. 15.—NASAL BONES.

The inferior border is thin and sharp, and often irregular ("frayed out"). The external surface is smooth, and perforated by a few small foramina; it is concave from above downward, convex from side to side. The internal surface is concave from side to side, convex from above downward; it presents a slight sinuous groove, passing from the superior to the inferior border, for the nasal nerve. The posterior lip of the inner border is prominent, and forms, with its fellow, the nasal crest for articulation with the spine of the frontal bone and the vertical plate of the ethmoid. The nasal bone develops from one centre, which appears about the second month.

THE MALAR BONES.

The malar are two irregular bones which form the osseous support to the cheeks. They are irregularly quadrilateral, and present for examination a body and four processes,—the frontal, orbital, maxillary, and zygomatic. The body has an external and an internal surface. The external surface is convex, smooth, and, near its upper border, presents the malar foramen, the opening of the temporo-malar canal, which transmits some small branches of the superior maxillary division of the fifth nerve. The posterior surface is concave, and presents a

(Outer surface.) (Inner surface.)

FIG. 16.—MALAR BONES.

rough surface for articulation with the superior maxillary bone; it enters into the formation of the temporal and zygomatic fossæ. The frontal process is strong and thick, its edges are rounded, and its articulating end is serrated for articulation with the external angular process of the frontal. The orbital margin is arched, with its concavity presenting upward. The orbital process is a curved, shelf-like plate, which projects backward from the orbital margin and descends from the frontal process downward and inward; it assists in forming the outer wall and floor of the orbit, and presents the inner opening of the temporo-malar canal. Its

anterior border is rounded, and forms part of the orbital ridge; its posterior border is rough, and articulates, behind the frontal process, with the frontal; lower down, with the great wing of the sphenoid; the inner third articulates with the superior maxillary. Just external to its articulation with the superior maxillary is a smooth, non-articular surface, which enters into the formation of the spheno-maxillary fissure. The maxillary process is a rough, trilateral surface, which articulates with the superior maxillary bone. The zygomatic process is strong, and serrated for articulation with the extremity of the zygoma. The inferior border of the malar bone is on a line with the zygoma. It develops from one centre, which appears about the second month.

THE SUPERIOR MAXILLARY BONE.

The superior maxillary are two triangular bones forming the upper jaw and the greater part of the osseous structure of the face. Each bone articulates with nine bones,—the frontal, ethmoid, nasal, malar, lachrymal, vomer, inferior turbinated, palate, and with its fellow, with which its alveolar process forms an arch, the superior dental, in which the teeth are placed. Each bone assists in the formation of three cavities,—the orbital, nasal, and buccal; two fossæ,—the spheno-maxillary and the zygomatic; and two fissures,—the pterygo-maxillary and the spheno-maxillary. It presents for examination a body and four processes,—nasal, malar, palatine, and alveolar. In the adult the body is cuboidal, hollow, and forms an air sinus, known as the antrum of Highmore, which begins to develop about the fifth year. The superior surface of the body is smooth, triangular, and presents a groove, the infra-orbital, which begins at the posterior border and curve

slightly outward and downward, enters the substance of the bone, and terminates below the anterior border, at the infra-orbital foramen; a branch of this canal descends in front of the antrum in the substance of the bone. The infra-orbital canal transmits the superior maxillary division of the fifth nerve.

The Circumference of the Superior Surface.—The inner border anteriorly is notched, smooth, and assists in forming the lachrymal canal; behind this it is

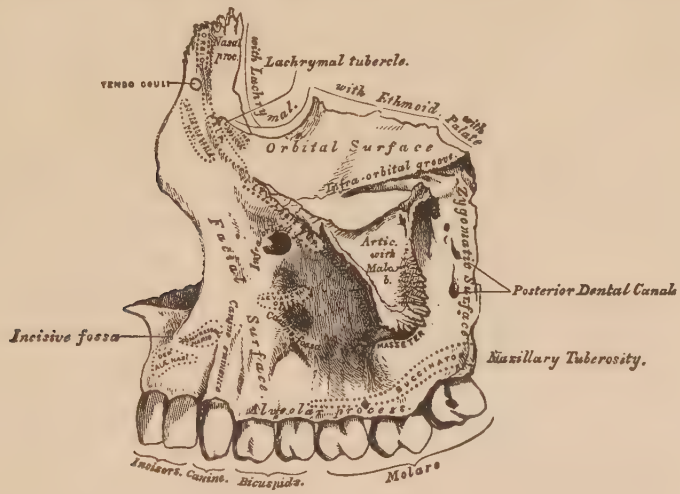

FIG. 17.—SUPERIOR MAXILLARY BONE.

serrated, somewhat cellular, and articulates from before backward with the lachrymal, lower border of the os planum of the ethmoid, and the orbital surface of the palate. The posterior border is directed obliquely backward and outward, is somewhat rounded, presents at its centre the beginning of the infra-orbital groove, and forms the greater part of the lower boundary of the spheno-maxillary fissure. The anterior border is directed obliquely outward and backward; at its angle with the posterior border is a rough, trilateral, irregular

surface of bone, the malar process, with which the malar articulates. The lower margin of this surface looks obliquely downward and forward, and is more or less straight; the upper margin is concave and terminates posteriorly in a hook-like process, which articulates with the great wing of the sphenoid. This process projects from the side of the superior maxilla, its lower border being horizontally notched, affording attachment for the masseter muscle. The posterior margin is also concave and vertical. The anterior border of the superior surface, internal to the malar process, is smooth, rounded, and forms part of the circumference of the orbit.

The posterior surface of the body is directed nearly vertically downward, is bluntly rounded, and presents along its inner border a groove, which, when articulated with the vertical plate of the palate, is converted into the posterior palatine canal. Along the posterior border are several foramina,—the posterior dental, which transmit nerves and vessels to the molar teeth. At the lower portion is the post-molar tubercle, prominent after the eruption of the wisdom-tooth. After the absorption of the alveolus, consequent upon loss of the teeth, the post-molar tubercle frequently disappears. At its lower portion it articulates with the tuberosity of the palate, and sometimes with the pterygoid process of the sphenoid. The posterior border of the superior maxillary forms the anterior boundary of the pterygo-maxillary fissure, and limits the spheno-maxillary fossa anteriorly. The internal surface forms part of the outer wall of the nose and mouth. It is divided by a horizontal process of bone, the palatine, which projects inward from the line of junction of the lower with the middle third of the inner surface. That

portion above the palatine process enters into the formation of the outer wall of the nose; that portion below assists in forming the cavity of the mouth. Above the palatine process, near the posterior border of the bone, is an opening leading into the antrum of Highmore, which is a cavity about the size of a hickory-nut. The opening leading into the antrum is very large and irregular in the disarticulated bone, but, in the articulated skull, processes of the turbinated, ethmoid, and

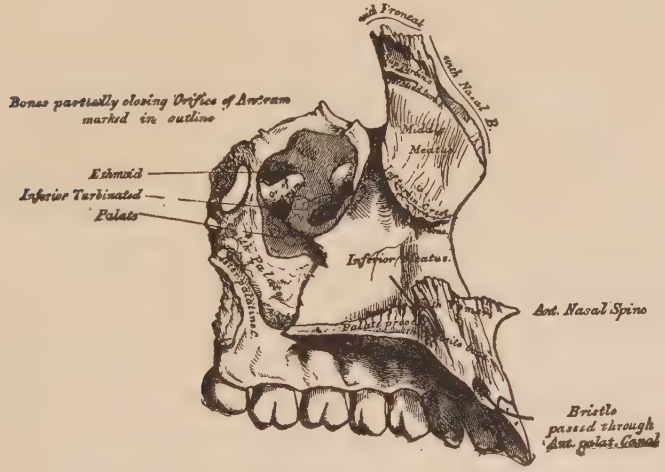

FIG. 18.—SUPERIOR MAXILLARY, INNER SURFACE.

palate bones close in the antrum, leaving only a small orifice, which communicates with the middle meatus of the nose. The nasal mucous membrane is continued through this opening, and lines the antrum. Upon section it is trilateral, frequently subdivided by delicate lamellæ of bone, and often presents upon its floor conical projections, which correspond to the apices of the roots of the first and second, and sometimes the last, molar teeth. Its walls are thin and translucent, and, if probes of whale-bone are inserted in the

posterior and anterior dental canals, these are seen to run in the outer wall of the antrum, skirting its lower portion. Running in the roof of the maxillary sinus is the infra-orbital canal, the floor of which is quite thin.* At the junction of the internal with the superior surfaces are a series of broken cells. Below the antrum the bone is smooth, concave, and continuous with the superior surface of the palatine process. Running from the lower portion of the opening of the antrum downward and forward is a fissure for articulation with the maxillary process of the palate bone. Posterior to the antrum the inner surface is rough, and articulates with the external surface of the vertical portion of the palate, which converts a groove on the inner surface of the superior maxillary into a canal,—the posterior palatine; it passes downward and slightly forward, and transmits the posterior palatine nerve from Meckel's ganglion. At the anterior portion of the inner surface is a trilateral plate of bone, the nasal process, about one and one-half inches in length and three-fourths inch in width. At its upper portion is a ridge called the superior turbinated crest, and at its lower portion another ridge, the inferior turbinated crest, which articulate with the middle turbinated process of the ethmoid and the inferior turbinated bone, respectively. Behind the nasal process, between it and the antrum, is a deep groove, the lachrymal, which is converted into a canal by articulation with the lachrymal and inferior turbinated. It lodges the nasal or lachrymal duct, and terminates in the inferior meatus of the nose. All that portion of the inner surface of the nasal process between the superior and inferior turbinated crests enters into the formation of the middle meatus of the nose.

* A study of the position of this canal is important in excision of the second division of the fifth nerve by Garretson's operation.

That portion of the inner surface below the inferior turbinated crest assists in forming the inferior meatus of the nose. Below the palatine process the bone is rough and uneven, and, extending horizontally backward from the posterior edge of the palate process, is a roughened ridge for articulation with the angle of junction of the vertical and horizontal portions of the palate bone.

The anterior surface of the superior maxillary looks forward, outward, and slightly downward. Just below the orbital ridge is the infra-orbital foramen, through which the second division of the fifth nerve emerges upon the face. This foramen is slightly oval, its anterior or upper margin forming a lip or ridge, which overhangs the foramen, and which becomes lost upon each side of it. The bone just below is grooved. The infra-orbital foramen is commonly on a line with the second bicuspid tooth. Below and somewhat posterior to the infra-orbital foramen is a triangular, shallow depression,—the canine fossa; it forms the anterior wall of the antrum, and is quite translucent. It gives origin to the levator anguli oris muscle. In front of this is a vertical elevation, the canine eminence, which marks the position of the root of the canine tooth. Anterior to the canine eminence is the incisive fossa,—a depression above the lateral incisor tooth; it gives origin to muscles. The inner border of the anterior surface, above the palatine process, presents a large, semi-heart-shaped notch,—the opening of the nose anteriorly. This notch begins at the nasal process; its border is smooth; it curves downward, outward, and then horizontally forward, terminating in a sharp-pointed process, which, when articulated with its fellow, forms the anterior nasal spine. The nasal process is a triangular plate of bone, which projects upward and forward. Its anterior border articulates

with the nasal; its apex, thick and serrated, with the frontal; its posterior projecting edge, with the lachrymal, forming the lachrymal canal. The external surface is smooth, slightly concave, and presents a few nutrient foramina, and affords attachment to muscles. The posterior border is grooved by the lachrymal duct. The inner surface has been described. The palate process is a thick, spongy, shelf-like plate of bone, which projects horizontally inward from the inner surface of the superior maxillary. It begins at the anterior surface of the bone, and passes backward, terminating posteriorly on a line just above the anterior portion of the second molar tooth, and nearly opposite the posterior surface of the malar process. The palatine process presents for examination a superior and inferior surface, a posterior and internal border. The superior surface is concave from side to side, smooth, and forms the floor of the nose. The inferior surface is rough, perforated by many nutrient foramina, and is slightly grooved for the passage of vessels. The inner border is thick. Along its upper surface it is thrown into a sharp lip, which, in the articulated skull, forms a crest that is continued backward from the anterior nasal spine; it articulates with the vomer. The anterior portion of the palatine process is thicker than the posterior; its inferior surface is curved upward and backward, beginning at the necks of the incisor teeth. The inner border behind the central incisor is grooved (sometimes it presents a canal), and, when articulated with its fellow, forms the anterior palatine canal. It transmits the anterior palatine vessels. The posterior border is thin, rough for articulation with the palate, and concave on the upper edge. The alveolar process is a temporary structure, and but little developed prior to the eruption of the teeth. It entirely disappears in

edentulous subjects. As it serves for the secure accommodation of the teeth, it is best seen in perfect dentures. The alveolar process consists largely of spongy bone. It is broader behind than in front, and presents eight principal cavities for the teeth, those for the molar teeth being subdivided by lamellæ of bone, forming separate sockets for the roots. These sockets are of different

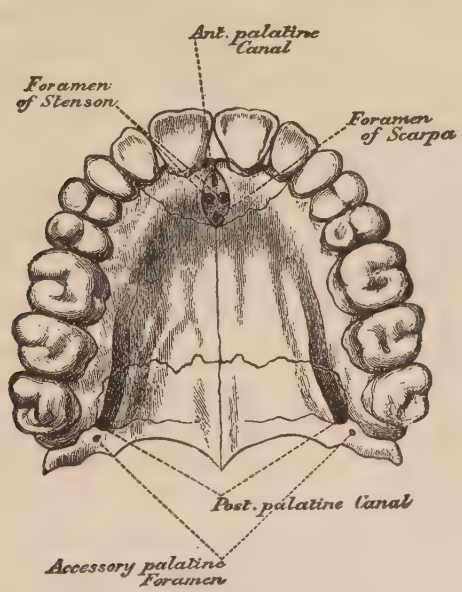

FIG. 19.—ROOF OF THE MOUTH.
(Formed by the palatine processes of the superior maxillary bones and the palatine processes of the palate bones.)

sizes; thus, the canine socket is the deepest, the socket for the first molar the broadest. The direction of the axes of the sockets is upward, and for the anterior teeth also slightly backward, giving to the teeth their forward projection, as is well seen in the negro. The outer surface of the alveolar process is thrown into vertical elevations and depressions, which mark the position of the roots of the teeth and the intervals between them. The

alveolar border abruptly constricts the necks of the teeth, but does not fit around them tightly; the teeth can be rattled in their sockets in the recently cleaned skull; this, of course, under normal circumstances, cannot be done, as the soft structures serve to pack the teeth firmly in position.

The superior maxillary develops by four centres, which appear at the beginning of the third month. One centre serves for the development of the nasal and facial portions, including the anterior wall of the antrum. A second centre is for the development of the malar and orbital portion, with the lateral and posterior parts of the bone. From a third centre the inner surface and posterior portion of the palatine process develop. The anterior portion of the palate process and the anterior part of the bone up to the canine tooth are developed by a separate centre. The line of junction between this incisive portion and the rest of the bone occasionally persists as a suture, a condition which in some of the lower animals is the rule, forming a separate piece of bone, the intermaxillary, particularly well seen in the skulls of sheep. When this centre does not appear, a cleft exists at the anterior part of the roof of the mouth, constituting one form of harelip and cleft palate.

THE LACHRYMAL BONE.

The lachrymal is a delicate, flat, quadrilateral bone, situated at the inner wall of the orbit; articulating anteriorly with the nasal process of the superior maxillary, above with the orbital plate of the frontal, posteriorly with the os planum of the ethmoid, and inferiorly with the orbital plate of the superior maxillary, and the inferior turbinated bone. It is about four lines in width by eight lines long. It is translucent, and, other than

the articulating borders, presents for examination an external and an internal surface. The external surface is smooth, and divided by a ridge into an anterior grooved and a posterior flat portion. The ridge, known as the lachrymal ridge, terminates inferiorly in a well-marked, hook-like process, which projects forward and articulates with the superior maxillary. In front of the lachrymal ridge is the groove, which, when the bone is articulated with the nasal process of the superior maxillary, forms the lachrymal canal. Posterior to the lachrymal ridge the bone is smooth and forms part of the inner wall of the orbit. The internal surface is roughened and at times cellular; it articulates with the ethmoid and inferior turbinated. This bone develops from one centre, which appears in the second month.

FIG. 20.—LACHRYMAL BONE.

THE PALATE BONES.

The palate consist of two irregular bones, placed at the posterior portion of the nose, the outer wall and floor of which they assist in forming. They enter into the formation of the roof of the mouth and floor of the orbit, and form part of the inner wall of the maxillary sinus (antrum of Highmore). The palate bones also assist in forming three fossæ,—the pterygoid, zygomatic, and spheno-maxillary; and one fissure,—the spheno-maxillary. Each presents for examination a vertical and a horizontal portion arranged in the form of the letter **L**, and projecting upward from the superior border of the vertical limb are two processes,—a large anterior, the orbital, and a small posterior, the sphenoidal. The horizontal portion presents

for examination a superior and an inferior surface, an anterior, inner and a posterior border.

The anterior border is thin and serrated for articulation with the posterior border of the palatine process of the superior maxillary. The inner border is thick, rough, and spongy; its upper edge is turned up in a prominent lip, which, when articulated with its fellow of the opposite side, forms the crest with which the vomer articulates, and is continuous with the crest of the palatine process of the superior maxillary bone. The posterior

FIG. 21.—PALATE BONE.
(Viewed posteriorly.)

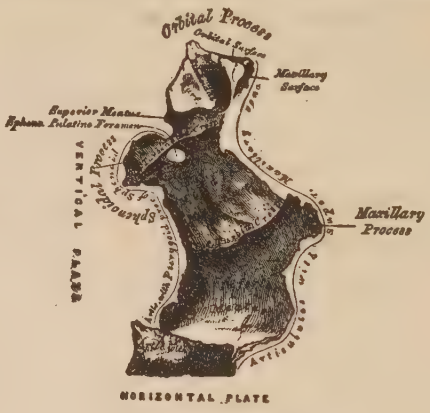

FIG. 22.—PALATE BONE.
(Inner surface.)

border is thin, concave from side to side, and terminates in the middle line posteriorly in a spine forming in the articulated skull,—the posterior nasal spine. The superior surface is smooth, concave from side to side, and forms the posterior portion of the floor of the nose. The inferior surface is smooth, but slightly irregular. Near the posterior border is the palatine ridge, which curves outward and backward and affords attachment to the tensor palati muscle. External and anterior to the palatine ridge is a groove which passes upward upon the external surface of the vertical plate. This groove is converted

into the posterior palatine canal in articulation with the superior maxillary. The vertical portion presents for examination an internal and external surface, an anterior and posterior border, and the orbital and sphenoidal processes. The internal surface is smooth, and is crossed by two oblique ridges,—the superior and inferior turbinated crests for articulation with the middle turbinated process of the ethmoid and the inferior turbinated bone, respectively. Below the inferior turbinated crest the bone is concave, and forms the posterior part of the inferior meatus of the nose; between the crests the surface is slightly concave, and forms part of the middle meatus. The surface is frequently grooved for small vessels, and occasionally presents a foramen near the posterior border. The external surface, above the angle of junction with the horizontal plate, is rough for articulation with the inner surface of the superior maxillary. Above the rough surface is a quadrilateral, smooth, slightly concave surface, which helps to close the antrum of Highmore. Along the posterior portion of this surface the bone is thrown into a lip, which slightly conceals the posterior palatine groove. This groove curves from above slightly forward, downward, and backward, and is larger below than above. In the articulated skull the opening of the canal is just above the wisdom-tooth. The anterior border is thin, sharp, and irregular; it extends from the orbital to the horizontal process. At its middle it presents a projecting, vertical plate of bone, the maxillary process, which assists in closing the antrum. The posterior border is concave, rather thick, irregular, grooved, and terminates at its lower portion in the tuberosity, which is a transversely expanded piece of bone, serrated at its edges for articulation with the internal and external pterygoid plates, with an intervening, smooth, concave

surface, which completes the pterygoid fossa anteriorly. At the junction of the horizontal portion with the tuberosity are several foramina, leading into canals,—the accessory posterior palatine. The orbital process is a hollow wedge, which projects from the upper anterior border of the vertical plate; it is about one-half inch antero-posteriorly, one-half inch vertically, and one-fourth inch transversely. It presents five surfaces, two of which are non-articular and three articular. The non-articular surfaces are the orbital and zygomatic; the articular are the ethmoidal, maxillary, and sphenoidal surfaces. The orbital surface is triangular and smooth, and is directed upward and forward and outward, and assists in forming the floor of the orbit. The zygomatic surface is quadrilateral in outline, smooth, is directed outward, backward, and slightly downward. It limits the spheno-maxillary fossa anteriorly. The angle of junction of the zygomatic and orbital surfaces is smooth and rounded, and forms part of the anterior boundary of the spheno-maxillary fissure. The ethmoidal surface is directed forward, inward, and upward; it articulates with the lateral mass of the ethmoid behind and below the os planum. Occasionally the cavity of the orbital process communicates with the cells of the ethmoid. The maxillary surface is directed forward, downward, and outward, is trilateral in outline, and slightly rough for articulation with the upper part of the posterior border of the superior maxillary. The sphenoidal is directed backward, inward, and upward. It is a quadrilateral surface, the margins of which are roughened for articulation with the sphenoidal turbinated bone. The sinus of the orbital process is sufficiently large to hold a currant; its walls are thin and translucent, its floor (maxillary surface) being frequently cribriform. The sphenoidal process projects from the

back part of the upper border, overhanging the posterior border. It is trilateral, compressed from side to side, and presents for examination an anterior, posterior, and superior border, and two surfaces,—the external and internal. The posterior border is thin, irregular, and articulates with the pterygoid process. The superior border is flattened, and overhangs the superior meatus; it is slightly roughened, and articulates with the sphenoidal turbinated bone. The anterior border is concave, smooth, and rounded, and forms the posterior boundary of the spheno-palatine notch. The external surface is divided by a longitudinal crest into an anterior non-articular and a posterior articular, grooved surface, which assists in forming the posterior palatine canal. Anterior to the ridge the bone is smooth, and leads into the spheno-palatine foramen. The internal surface is smooth, strongly concave from above downward, and assists in forming the superior meatus of the nose. Between the sphenoidal and orbital processes is the spheno-palatine notch or foramen; it is oval in form, its long axis being almost vertical in the articulated skull. Its boundary anteriorly is smooth, broad, and formed by the posterior inferior border of the orbital process. Posteriorly, the border is sharp; small spiculæ or spines of bone sometimes project from the circumference, subdividing it. This notch is converted into a foramen by the sphenoidal turbinated bone. It transmits the spheno-palatine vessels and nerves.

The palate bones develop from a single centre, which appears at the external border of the horizontal plate about the third month.

THE VOMER.

The vomer is a flat, translucent, quadrilateral bone, which articulates posteriorly with the rostrum of the

sphenoid and below with the nasal crest formed by the articulation of the horizontal processes of the superior maxillary and palate bones. It assists in forming the partition, or septum, of the nose. It presents two surfaces and four borders,—superior, anterior, inferior, and posterior. It is somewhat diamond-shaped, its outline being not unlike that of an arrow-head. The surfaces are smooth. Running obliquely from behind, forward and downward, is the naso-palatine groove, transmitting the naso-palatine nerve; it terminates, in the articulated skull, at the anterior palatine canal. The surfaces of the vomer form part of the inner wall of the nasal cavities. The superior border is thin and irregular, and articulates with the perpendicular plate of the ethmoid, and anteriorly with the septal cartilage of the nose. The inferior border is rough, and articulates with the nasal crest along the middle line of the floor of the nose. The posterior border is slightly concave, rounded and smooth, and forms the separation between the openings of the posterior nares. The superior border is thick, thickest at its posterior part, and thrown into two well-marked alæ, or wings, which fit on either side of the rostrum of the sphenoid, forming with the vomer a tongue-and-groove articulation. The anterior border is directed obliquely forward and downward, the superior upward and obliquely backward, the inferior border nearly horizontally, and the posterior border obliquely backward and downward. The vomer develops by two centres, which appear about the second month; at first

FIG. 23.—VOMER.

it consists of two laminæ, which sometimes fail to unite, inclosing a sinus between them.

THE INFERIOR TURBINATED BONES.

The inferior turbinated are two irregular, scroll-like bones situated in the nasal cavities. They are spindle-shaped in outline, and run horizontally along the outer wall of the nose. The bones consist of a quadrilateral, vertical plate, about three-quarters of an inch square; from its inner surface the turbinated portion curves inward and downward. The vertical plate presents for examination an external and internal surface, and irregular borders. The external surface is rough, for articula-

(Inner surface.) (Outer surface.)

FIG. 24.—INFERIOR TURBINATED BONES.

tion with the inner surface of the lateral mass of the ethmoid and superior maxillary, and it also assists in closing the antrum. The inner surface of the vertical plate forms part of the external wall of the nose. Projecting from the anterior border of the vertical plate is the lachrymal process, a vertical lamella of bone, which articulates with the lower border of the lachrymal. The anterior border articulates with the posterior edge of the nasal process, completing the lachrymal canal. The turbinated portion is spindle-shaped, strongly curved inward, downward, and outward; rougher and more irregular on the inner convex than on the outer or under concave surface. The extremities are pointed, the posterior sharper than the anterior. The upper border of the turbinated portion, in front of the vertical

plate, articulates with the inferior turbinated crest of the superior maxillary, with the lachrymal and ethmoid. Posterior to the vertical plate, it articulates with the inferior turbinated crest of the palate. The inferior turbinated develops by a single centre, which appears about the fourth month.

THE INFERIOR MAXILLARY.

The inferior maxillary is an irregular bone which forms the lower jaw. It is the strongest and largest bone of the face, and consists of a body and two rami. The body, placed horizontally, is bent like a horseshoe; it

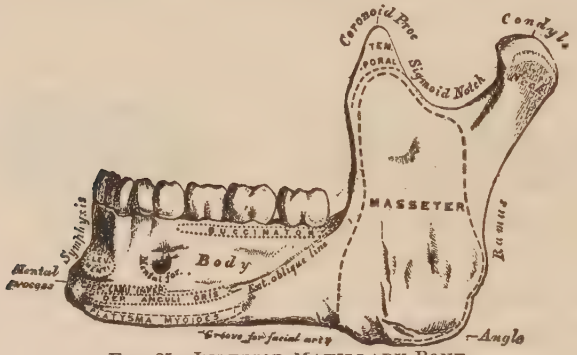

FIG. 25.—INFERIOR MAXILLARY BONE.

is a thick plate of bone, curved on the flat, and presents for examination an external and internal surface, a superior and inferior border. The external surface is strongly convex from side to side, and, in front, concave from above downward. It is somewhat rough and irregular, and presents in the median line a ridge, which indicates the line of union (symphysis) between the two halves of the bone. This ridge expands near the inferior border in a triangular, slightly-elevated mass of bone,—the mental process. On each side of the ridge, beneath the incisor teeth, is a shallow depression, the incisive fossa, which gives origin to the levator menti muscle.

External is the canine eminence, which marks the position of the root of the canine tooth; it is less developed than the canine eminence of the upper jaw. About an inch and a quarter external to the median line is the mental foramen, at which a leash of filaments of the inferior dental nerve make their appearance upon the face. The mental is an oval foramen, two lines in its transverse and three lines in the conjugate diameter, with its long diameter parallel with the lower border; it is almost directly in a line below the second bicuspid tooth. It is a little below the middle line of the bone; an examination of a number of inferior maxillary bones shows it to be at the junction of the inferior two-fifths with the superior three-fifths of the bone. Posterior to the mental foramen, the outer surface is convex from above downward. An oblique ridge—the external oblique line—begins posterior to the mental foramen and curves backward and upward, becoming continuous with the anterior edge or border of the ramus. The internal surface is strongly concave from side to side, convex from above downward. It presents on each side of the median line, below the middle of the bone, two tubercles—the genial tubercles—for muscular attachment. These tubercles are arranged in pairs, two above and two below. A little posterior to the superior genial tubercles, and running backward and slightly upward, is the internal oblique line, or mylo-hyoid ridge, which gives attachment to the mylo-hyoid muscle. This ridge is not well defined anteriorly, but becomes prominent beneath the molar teeth. It passes upward and backward on the inner surface of the ramus. Above the mylo-hyoid ridge, on each side of the median line, is a shallow depression, which lodges the sublingual gland. At the sides of the inferior genial

tubercles is a shallow depression, the digastric fossa, for the attachment of the anterior belly of the digastric. Below the internal oblique line, posteriorly, is a broad, shallow depression, the submaxillary fossa, which lodges the submaxillary gland. The inferior border is strong, thick, and rounded. Its anterior portion, between the mental foramina, is strongly everted. Near its junction with the ramus a shallow groove is frequently seen, for the passage of the facial artery. The superior border

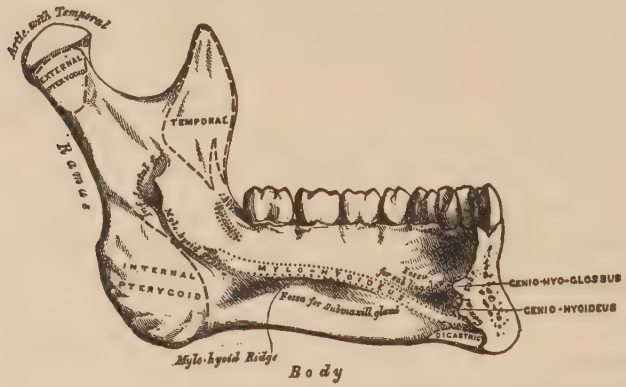

FIG. 26.—LEFT HALF OF INFERIOR MAXILLARY BONE, INNER SURFACE.

constitutes the alveolar process, which is narrower in front than behind, and presents sixteen sockets for the reception of the teeth. The alveoli for the incisor teeth are conical pits, compressed laterally. They are about half an inch in depth, their apices recede from the anterior surface of the bone, and their axes are inclined slightly outward. The incisor teeth readily drop out of their sockets after the removal of the soft structures. The canine alveoli are the deepest sockets of the lower jaw; their axes are placed vertically; they are conical pits, laterally slightly compressed, and oval on section; the long axis of the oval is directed outward,

forming an angle of about 40° with the median line. The sockets of the bicuspids are conical pits, compressed antero-posteriorly. Their sections are oval, the long axis of the oval in the first bicuspid being about 50°, that of the second about 60°. The vertical axis of the cuspid sockets is directed slightly inward. The sockets for the three molar teeth are each double, a partition of bone passing transversely across the cavity, subdividing it into an anterior and posterior socket; these are for the lodgment of the roots of the molar teeth. The septum between the roots is thick in the first molar, less so in the second, and thinnest and irregular in the third. Along the median line the partition is bulged, both anteriorly and posteriorly; this is best seen in that across the first molar socket. In all molar sockets the anterior division is broadest and largest. The cavity for the wisdom-tooth is not regular in form. The vertical axes of the molar teeth are inclined inward, the second more than the first, and the last are generally most strongly inclined. The object of the inclination of the axes of the lateral sockets of the lower jaw is to enable the lower teeth to articulate or strike against the upper, and, as the lower jaw is broader than the upper, this can only be effected by an inward inclination of the axes of the teeth, and hence of their sockets. Behind the last molar is a triangular, rough depression, the post-molar fossa, well marked in some of the lower animals. The alveolar border is slightly everted anteriorly, slightly inverted posteriorly.

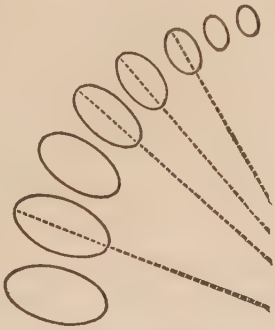

FIG. 27.—SHOWING ANGULATION OF TOOTH-SOCKETS.

The rami of the inferior maxillary bone are two

strong, flat, quadrilateral processes of bone at right angles to the body. They present for examination an external and internal surface; an anterior, posterior, superior, and inferior border; an angle, and two processes. The external surface is smooth, flat, and presents some elevations and ridges for the attachment of the masseter muscle. The internal surface is very uneven. About its centre is the inferior dental foramen, leading into the inferior dental canal, which is directed obliquely downward and forward. The approach to the inferior dental foramen from above is funnel-shaped and grooved at the expense of the inner surface of the ramus. Overlapping the foramen is a sharp lip of bone, deeply-notched on its upper edge; it gives attachment to the internal lateral ligament of the jaw. Running downward and forward from the lower border of the inferior dental foramen is a well-marked groove, the mylo-hyoid, which lodges the mylo-hyoid artery and nerve. At the posterior lower portion is a well-marked, shallow fossa, the posterior margin of which is very rough; it serves for the attachment of the internal pterygoid muscle. Above the foramen the bone is flattened and beveled up to the superior border. The anterior border is thin and sharp, and continuous with the external oblique line; it terminates above in a flattened, triangular process, the coronoid, which gives attachment to the temporal muscle. The superior border is strongly concave and sharp, and forms the sigmoid notch; it runs from the coronoid process anteriorly to the condyloid process, which projects upward and backward from the posterior angle of the superior border. It is a strong process of bone, compressed antero-posteriorly, and surmounted by the condyle, which articulates with the glenoid fossa of the temporal bone. The condyle is directed outward

and slightly forward, forming an angle of about 15 degrees with a transverse line bisecting the two glenoid cavities. It is about three-fourths of an inch transversely, one-fourth of an inch antero-posteriorly. It is slightly convex from side to side, and strongly convex from front to back. The articular surface extends downward upon the posterior border of the process, and deeper internally than externally. Below the articulating surface, anteriorly, is a depression at which the external pterygoid is inserted, and lower down the bone becomes somewhat constricted, forming the neck. The posterior surface of the process is convex from side to side and from above downward. The posterior border is slightly concave from above downward; it is smooth and rounded, and directed downward and somewhat forward. The inferior border is the continuation of the lower border of the body; at the junction with the posterior border it forms an angle which is markedly obtuse in infancy and old age; in the adult, between twenty and fifty years, it approximates a right angle. The posterior border of the angle gives attachment to the stylo-maxillary ligament.

The inferior maxillary develops by two principal centres, one for each half, which meet and join at the symphysis, forming one bone. The shape and general appearance of the inferior maxillary differ at different periods of life; thus, at birth it consists of two halves, the angle is very obtuse, and the alveolus is undeveloped, although it contains the sockets of the temporary teeth and the germs of the permanent set. In the adult the angle is nearly a right angle, all the ridges and processes are strongly defined and developed, the alveolar process is strong and complete, constricting the necks of the teeth. In old age the bone recedes and approximates its

infantile characteristics, the angle is again very obtuse, the alveolar process absorbed, and the mental process pointed and prominent.

The skull is an ovoid structure with a flattened and irregular base. It consists of two portions,—the cranium and the face. In the adult male these two are of nearly equal proportions; in infancy the cranial portion is nearly

FIG. 28.—A LATERAL VIEW OF THE SKULL.

1. Inferior maxilla.
2. Angle of inferior maxilla.
3. Condyle of inferior maxilla.
4. Mastoid portion of temporal.
5. Occipital.
6. Zygoma.
7. Coronoid process of inferior maxilla.
8. Malar bone.
9. Superior maxilla.
10. Nasal bone.
11. Frontal bone.
12. Temporal bone.
13. Parietal bone.
14. Superciliary ridge.

eight times as large as the facial. In adult females the cranium constitutes about three-fifths and the face two-fifths of the bulk of the skull. The bones which enter into the formation of the skull are, with the exception of the inferior maxillary, immovably articulated together, and comprise the synarthrodial joints. On the surface

of the skull are a number of irregular linear markings, which are the lines of articulation between the different bones; they are called the seams or sutures. Three of these have received special names: the coronal, between the frontal and parietal bones; the sagittal, between the two parietal; and the lambdoid, between the parietal and occipital bones. Sutures are also named from the bones between which they are placed; thus, the fronto-parietal, the inter-parietal, the parieto-occipital, the temporo-sphenoidal, the naso-maxillary, the temporo-maxillary, the maxillo-malar, and others. Some of the sutures are very irregular and deeply dentated; such are the fronto-parietal, the inter-parietal, the parieto-occipital. Others are formed by the beveled edge of one bone resting against the beveled edge of another, as in the anterior part of the temporo-parietal articulation and the spheno-parietal. Some simply abut, as the inter-nasal, inter-maxillary, spheno-occipital (prior to the ossification of the interposed plate of cartilage), part of the spheno-temporal. Some form a groove-and-tongue joint, as is the case with the vomer in its articulations with the palate and the palatine processes of the superior maxillary, and also with the rostrum of the sphenoid. All the sutures are most marked in early life; later, some of them undergo ossification, and are thus obscured or altogether obliterated.

The cranial portion of the skull forms an osseous case, which is ovoidal in shape and contains the brain. Its capacity in the highest (xanthochroic) races is about one hundred cubic inches. As a general rule, the lower the race, the less the capacity of the brain-case. An antero-posterior section of the cranium is oval, the smallest end of the oval being anterior. A transverse section approximates a circle. These sections also exhibit the mechanical construction of the cranium,

which is such as to effectually resist violence to the organ which it contains. The cranium is about seven inches long, five inches at its widest part, and five inches high from the vertex to the base. Its circumference is about nineteen inches. Its walls average three-sixteenths inch in thickness. If divided in the median line, it is found not to be absolutely symmetrical. Marked asymmetry of the cranium is frequently observed in the insane, and also in the criminal classes. The skull presents for examination five regions,—a superior, an inferior, two lateral, and an anterior. The superior region is known as the vertex, or summit. It is bounded in front by the superciliary ridges and the glabella; behind, by the superior curved lines of the occipital; laterally, by a line drawn from the superior curved line of the occipital to the temporal ridge, and thence to the external angular process of the frontal. The vertex is formed by the frontal, the two parietal, and the occipital bones. From before backward are seen, on each side of the median line: the frontal eminence, the remains of the frontal suture, the parietal eminence or boss, the parietal foramen, and, in some skulls, at the angle of articulation between the two parietal and the apex of the occipital, a separate piece of bone, sometimes a number, constituting islands of bone held firmly in position by dentated processes. They are called Wormian bones. They are also found, but less frequently, at the junction of the coronal and sagittal sutures. In some of the lower animals, as the sheep, they are the rule. The development of Wormian bones in these positions is due to the deposit of separate ossific centres. In the fœtus the bones of the cranium are not fully developed, hence not solidly articulated, and, by slight pressure, their edges, particularly those forming the vertex, can be made to overlap.

The most marked lack of full development is seen at the junction of the frontal, coronal, and sagittal sutures, where a diamond-shaped or quadrilateral opening exists, which does not close before the second year.

At the junction of the sagittal and lambdoid sutures is a narrow, elongated opening, caused by the divergence of the posterior part of the superior borders of the parietal bones, and, as before stated, it is at this place principally that Wormian bones are developed. Such openings are also met with at the sides of the skull, at the temporo-parietal and parieto-sphenoid articulations. In the infant, these openings in the skull pulsate synchronously with the action of the heart, and hence they are called fontanelles; the anterior are situated at the frontal, sagittal, and coronal sutures; the posterior, at the junction of the sagittal and lambdoid sutures. These two fontanelles should be carefully studied, as they are of great importance to the obstetrician in determining the position of the head of the fœtus. The internal surface of the vertex is smooth, strongly concave, and presents a number of slight elevations and depressions, which correspond with the convolutions of the brain. Running along the median line, from front to back, is the groove which lodges the superior longitudinal sinus. This groove is penetrated by many minute foramina, which transmit veins to the sinus. Two of these, the parietal, are of larger size. They are situated near the posterior superior angle of the parietal bone. The inner surface of the vertex also presents grooves at its sides for meningeal arteries. Of these the deepest and most important is that which passes up from the anterior inferior angle of the parietal bone. It lodges the middle meningeal artery.

The base of the skull presents for examination an

external or inferior surface and an internal or superior surface. The external surface extends from the incisor

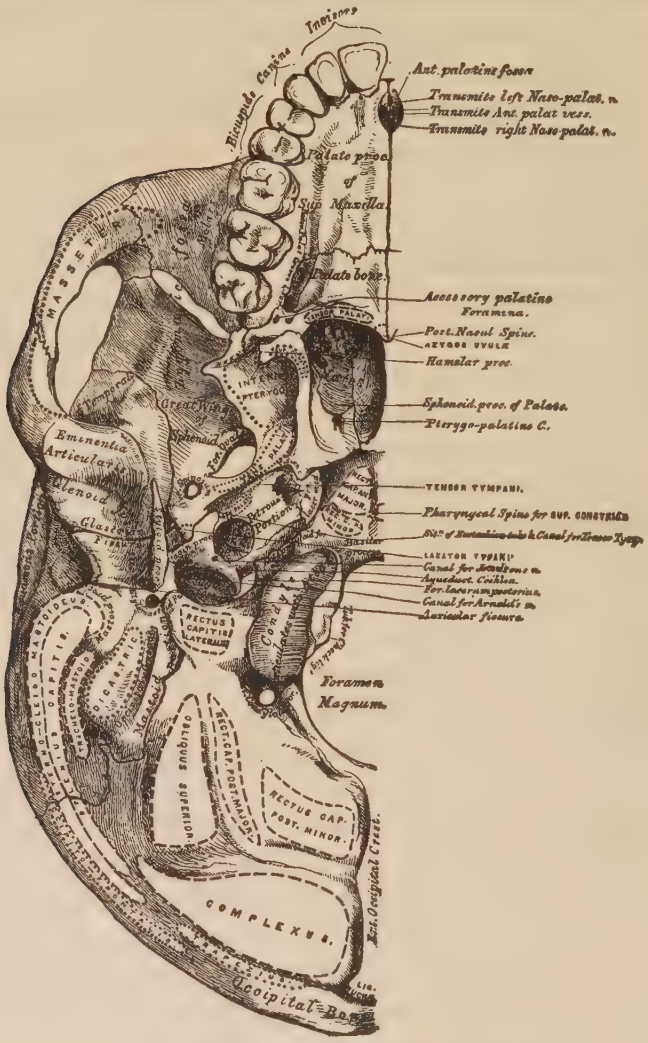

FIG. 29.—BASE OF SKULL, EXTERNAL SURFACE.

teeth anteriorly back to the superior curved lines of the occipital, and laterally to the zygomatic processes and a

line drawn from the third root of the zygoma back to the superior curved line of the occipital. It is exceedingly irregular and rough, and is divided into two portions,—the cranial and the facial. The former occupies the posterior two-thirds and the latter the anterior third of the base. The bones entering into the formation of the inferior surface of the base are, from behind forward, the occipital, two temporal, sphenoid, vomer, two palate, and two superior maxillary; in all, nine bones.

About the middle of the cranial portion of the base is the foramen magnum, the position of which varies somewhat in the different races; as a rule, it is farther posterior in the inferior races than in the higher; in the anthropoid apes it approaches the posterior part of the skull. At each side of the foramen magnum anteriorly are the condyles for articulation with the atlas; behind the condyles are the posterior condyloid foramina, which transmit veins to the lateral sinuses. Passing backward from the foramen magnum to the external occipital protuberance is the occipital crest, from which the inferior curved lines branch outward and downward. At the sides of the crest, between the curved lines, the bone is slightly shallow and rough, for the attachment of muscles. In front of the condyles are the large anterior condyloid or hypoglossal foramina, for the transmission of the hypoglossal nerves. These foramina penetrate the bases of the condyles and pass horizontally forward. External to the condyles, and in front of a line drawn from the mastoid process to the anterior portion of the condyle, is the foramen lacerum posteriorus, or jugular foramen. It is irregularly ovoidal in form, the large end of the oval being directed toward the mastoid process; its axis is directed obliquely outward and backward, forming an angle of from 35 to 45 degrees with the

transverse diameter of the skull. It is bounded posteriorly by the occipital bone, anteriorly by the petrous portion of the temporal. It is formed by the jugular notch of the occipital and jugular fossa of the temporal bone. Its axis is curved, being directed at first upward, then horizontally backward. It transmits the jugular vein, the glosso-pharyngeal, pneumogastric, and spinal accessory nerves. External to the jugular foramen is the stylo-mastoid foramen, out of which the facial nerve emerges from the skull. Anterior to the jugular foramen is the opening of the carotid canal, which at first passes vertically upward, then horizontally inward and forward; its upper inner wall is deficient. In front of the carotid foramen, in the angle between the petrous and squamous portions of the temporal bone, is the rough, funnel-shaped opening of the Eustachian canal, which leads into the tympanum; it is directed obliquely backward and outward and is divided horizontally by a partition of bone,—the processus cochleariformis. The lower part of the canal serves as an air-vent (it is the Eustachian canal proper) to the tympanum. The upper canal lodges the laxator tympani muscle.

In front of the foramen magnum is the rough quadrilateral basilar process, continuous in the adult skull with the body of the sphenoid, with which it joins just behind the vomer. The sides of the basilar process assists in forming the middle lacerated foramen, which is bounded externally by the apex of the petrous portion of the temporal bone, anteriorly by the base of the pterygoid process and posterior border of the great wing of the sphenoid, and internally by the basilar process of the occipital. It is triangular, with the base of the triangle directed forward, and in the recent state is filled with cartilage, which, however, is penetrated by small

canals for the transmission of meningeal arteries to the brain; it is also traversed horizontally by the large petrosal nerve, which enters the Vidian canal at the base of the pterygoid process. The interval between the petrous and squamous portions of the temporal is occupied by the great wing of the sphenoid, which here presents two foramina,—the foramen spinosum and the foramen ovale. The latter is placed external to the base of the pterygoid process, and transmits the third division of the fifth pair of nerves. External and posterior to the foramen ovale is the foramen spinosum, in the spinous process of the great wing of the sphenoid; it transmits the middle meningeal artery. In front of these foramina the base is concave from side to side, and forms the roof of the zygomatic fossa. External to the petrous portion of the temporal is the glenoid fossa for articulation with the condyle of the inferior maxillary bone. It is limited posteriorly by the post-glenoid tubercle (the second root of the zygoma), the wall of the meatus auditorius externus, and the vaginal process; anteriorly, by the tubercle of the zygoma and the eminentia articularis. Its axis is directed outward and somewhat forward. The plane of the cranial portion of the base is directed forward and upward. The facial portion of the base is anterior to a line drawn through the tubercles of the zygoma. It drops abruptly from the anterior part of the cranial portion of the base, its plane being directed nearly horizontal, and, if continued backward, would strike the posterior margin of the foramen magnum. The facial portion of the base is formed behind by the pterygoid processes, between which are the posterior nasal openings, separated by the vomer. Projecting posteriorly, in the middle line, is the posterior nasal spine, which gives attachment to the uvula.

The facial portion of the base forms the roof of the mouth; it is limited anteriorly by the posterior face of the incisor and canine teeth, laterally by the inner face of the bicuspids and molars. It is trilateral in outline, a foramen being found at each angle,—in front the anterior palatine, and at each of the posterior angles the posterior palatine foramen. Running backward, from the anterior palatine foramen to the posterior nasal spine, is the palatine crest, formed by the articulations of the inner borders of the horizontal portions of the superior maxillary and palate bones. The upper surface of the base forms the floor of the cranial cavity and supports the brain. It is divided into three fossæ,—anterior, middle, and posterior. The anterior is the smallest, and is situated on the highest plane; the posterior is the largest, and occupies the lowest portion of the cranial cavity; the middle fossa is on a lower plane than the anterior. The anterior fossa is bounded in front and at the sides by the frontal bone, and is limited behind by the posterior border of the lesser wing of the sphenoid and orbital plate of the frontal. It supports the anterior lobes of the brain. It is convex from side to side and smooth, although impressed by the convolutions of the brain. In the middle line is the crista galli of the ethmoid, which affords attachment to the falx cerebri. On each side are the olfactory foramina in the cribriform plate of the ethmoid; these foramina transmit the filaments of the olfactory nerves to the nose. In front of the crista galli is a pit called the foramen cæcum, which sometimes exists as a canal, and transmits a small vein; it is the point of origin of the great longitudinal sinus. The middle fossa is strongly concave and irregular; it supports the temporo-sphenoidal and middle lobes of the brain. It is limited in front by the posterior edge of the

lesser wing of the sphenoid and orbital plate of the frontal and the great wing of the sphenoid, which, with the squamous portion of the temporal, forms also its

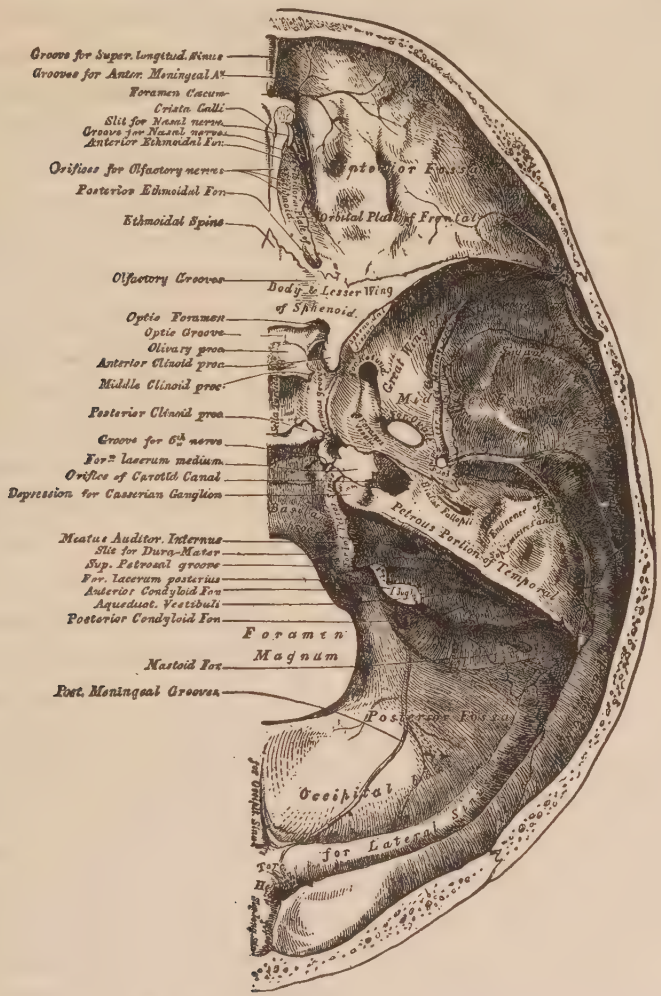

FIG. 30.—FLOOR OF THE CRANIUM.

outer boundary. Behind, the middle fossa is bounded by the anterior surface of the petrous portion of the temporal. The principal foramina are: the anterior

lacerated, which is under the cover of the lesser wings of the sphenoid; the foramen rotundum, the foramen ovale, the middle lacerated, the foramen spinosum, the hiatus Fallopii, and the opening of the carotid canal. The posterior fossa is bounded in front by the posterior surface of the petrous portion and the incline of the basilar process of the occipital bone; laterally by the occipital, parietal, and mastoid portion of the temporal. It is strongly concave in every direction, and lodges the cerebellum, the medulla, and the posterior lobes of the brain. The principal foramina are the posterior lacerated, anterior condyloid, and the foramen magnum. The posterior condyloid and the mastoid, when present, transmit veins. The interior of the cranial cavity presents certain grooves, some of which are constant and invariable in position. These grooves lodge the blood-sinuses which are formed by the divergence of the layers of the dura mater. The principal grooves are the following: The groove for the superior longitudinal sinus; it begins at the foramen cæcum, and, gradually growing broader, curves backward along the median line, terminating at the internal occipital protuberance. A slight groove is continued downward toward the foramen magnum for the accommodation of an ascending sinus. The grooves for the lateral sinuses are very large and important. They pass horizontally outward from the internal occipital protuberance, on the horizontal limb of the occipital cross, as far forward as the mastoid portion of the temporal, then curve downward behind the petrous portion, then inward, and terminate at the posterior lacerated foramina, through which the lateral sinuses pass, assuming the name of jugular vein. The superior and inferior petrosal sinuses groove the superior and posterior borders of the petrous part of the temporal, and communicate with the lateral

sinuses. At each side of the body of the sphenoid, extending from the anterior lacerated foramen backward in a sinuous manner, is the groove for the cavernous sinus. In addition to these grooves, upon the inner surface of the cranium we have canals ramifying freely in the diploic structure of the cranial bones, which lodge veins or blood-sinuses; these blood-channels can be exposed by rasping away the outer table of the cranial bones.

The base of the skull is exceedingly interesting. A line drawn through the apices of the mastoid processes will bisect the foramen magnum and pass just behind the occipital condyles. In the lowest races, as the Australoid, this line passes through the condyles near their anterior border, owing to the recession of the foramen magnum in the lower races. A line drawn transversely through the auditory meatuses will pass through the jugular foramina, the anterior part of the occipital condyles, and touch the anterior margin of the foramen magnum. A line drawn just in front of the glenoid fossæ will pass through the foramen ovale and the line of junction between the occipital and sphenoid bones. The plane of the base of the cranium anteriorly is on a line with the upper border of the zygomatic processes.

Between the superior and inferior surfaces of the base anteriorly is the facial portion of the skull, presenting the openings of the orbital and nasal cavities.

The orbital are two pyramidal cavities below the frontal bone. Their axes diverge and are directed outward, forming an angle of 40 degrees. The apex is posterior at the optic foramen. The base is the large, irregularly circular opening which forms the circumference of the orbit. Seven bones enter into the formation of each orbital cavity. They are the frontal, sphenoid, malar, superior maxillary, ethmoid, lachrymal, and

palate. As the frontal, ethmoid, and sphenoid are common to both cavities, the two orbital cavities together are formed of but eleven bones. At the apex of the orbit is the optic foramen, which transmits the optic nerve and ophthalmic artery. External to this is the anterior lacerated foramen, a triangular opening directed upward and outward. It transmits the third, fourth, ophthalmic division of the fifth, and sixth pair of nerves, and the ophthalmic vein. It communicates with the spheno-maxillary fissure, which passes outward and downward from the inner portion of the foramen lacerum anterius. The roof of the orbit is strongly concave, and is formed by the horizontal plate of the frontal, and, posteriorly, the under surface of the lesser wing of the sphenoid. The outer wall, directed obliquely outward and forward, is formed by the great wing of the sphenoid and the malar bone. The inner wall, directed backward, slopes slightly downward and outward, is formed principally by the lachrymal and ethmoid. The floor, slightly concave, is formed by the superior maxillary, malar, and palate. The orbital cavities contain the eyes and their muscular apparatus, and afford these delicate organs protection from injury by the strong and prominent orbital ridge which forms the circumference of the cavity.

The nasal cavities are placed in the middle of the face, between and below the orbits. They have openings anteriorly and posteriorly. The anterior opening is somewhat heart-shaped, the apex being above; the posterior openings, two in number, are elliptical, their long axes are directed vertically, and they open into the pharynx. Owing to the absence of the triangular cartilage in the prepared skull, the anterior opening is not divided. The nasal are two wedge-shaped cavities, separated from each other by the vertical plate of the eth-

moid and the vomer. The thick end of the wedge is at the floor of the nose, the thin end at the upper part of the nasal cavities. The outer wall of the nose inclines strongly inward as it passes upward; the septum or partition is nearly perpendicular. The nasal cavities present for examination an inner and outer wall, a floor

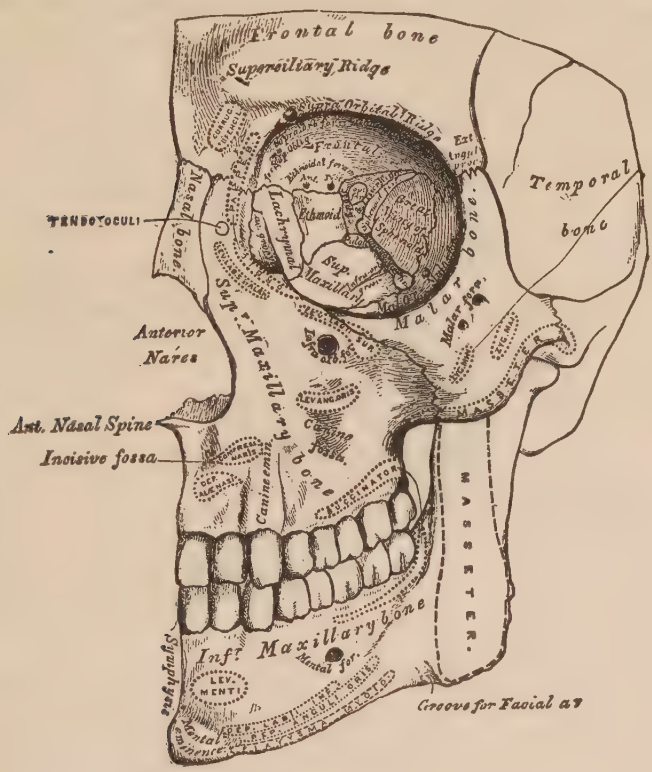

FIG. 31.—FACIAL PORTION OF SKULL.

and a roof, an anterior and a posterior opening. The inner wall is formed almost entirely of a thin, bony partition, consisting of the vertical plate of the ethmoid and the vomer. In the recent state, the triangular notch at the anterior part of the septum is completed by the triangular cartilage, which extends to the anterior open-

ings of the nose and assists in supporting the soft structures. The entire partition is called the septum nasi. It is smooth, covered with periosteum and mucous membrane. The outer wall is exceedingly irregular, and is formed by the superior maxillary, lachrymal, palate, inferior turbinated, and internal plate of the pterygoid process. Traversing the outer wall from front to back are the superior and middle turbinated processes of the ethmoid and the inferior turbinated bone. These

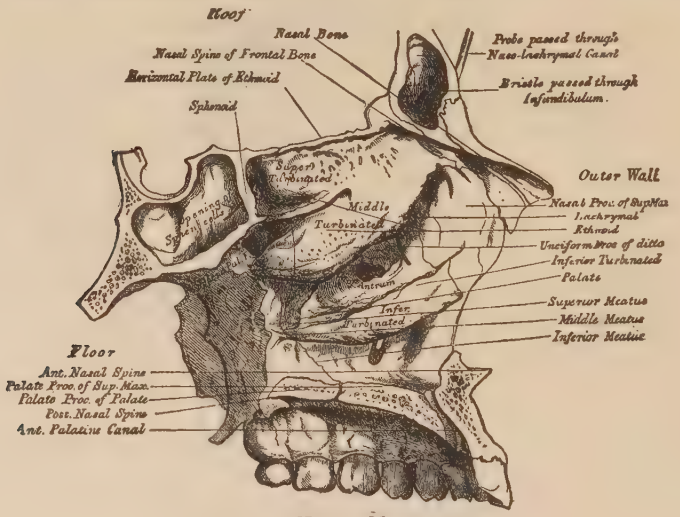

FIG. 32.—NASAL MEATUSES.

divide each nasal cavity into three horizontal passages,—the superior, middle, and inferior meatuses. The inferior is situated below the inferior turbinated bone, the middle between the middle turbinated process of the ethmoid and the inferior turbinated bone, the superior above the middle turbinated process. Of these, the largest is the inferior meatus. It is bounded below by the floor of the nose; at its anterior part is the opening of the lachrymal canal. The middle meatus occupies the posterior two-thirds of the nasal cavity.

Anteriorly it presents the opening of the frontal and ethmoidal sinuses, and about its centre is the opening of the antrum of Highmore. The superior meatus, situated at the posterior third of the nasal cavity, communicates with the posterior ethmoidal cells and the sphenoidal sinus. The floor of the nose is formed by the superior surface of the horizontal processes of the superior maxillary and palate bones. It is smooth, slightly concave from side to side, and broader at the centre than at either extremity. The roof consists of three portions,—anterior, middle, and posterior. The anterior portion slopes downward and forward, and is formed by the nasal bones and the spine of the frontal; the middle portion is horizontal, and is formed by the cribriform plate of the ethmoid; the posterior is the anterior and under surface of the body of the sphenoid, which slants backward and downward. The anterior opening, with the triangular cartilage in place, is semi-cordiform; the posterior opening is elliptical.

The cavity of the mouth is below the nasal cavities and extends in the skull, from the inner surface of the alveolar processes of the superior and inferior maxillary bones and the inner surfaces of the teeth, backward to the posterior border of the hard palate. It presents for examination a roof (the hard palate) and anterior and lateral boundaries. The roof is formed by the horizontal processes of the superior maxillary and palate. It is rough, concave from side to side and from front to back, and presents in the median line a ridge, which is more or less well marked. Behind the central incisor teeth is the anterior palatine canal; on each side posteriorly, and just internal to the last molar tooth, is the opening of the posterior palatine canal, and running forward from this is a well-marked groove for the artery and

nerve. The anterior and lateral boundaries are formed by the alveolar processes, teeth, and inferior maxillary bone.

On the lateral region of the skull is the temporal fossa, limited above by the temporal ridge, in front by the external angular process of the frontal and the posterior concave surface of the malar. Externally, and arching across, is the zygomatic process of the temporal. Internally, and below, is the pterygoid ridge. The fossa is cuneiform in shape, the base of the wedge being directed anteriorly. It is formed by the frontal and great wing of the sphenoid anteriorly, and the squamous portion of the temporal posteriorly; the malar bone is in front. Near the posterior part of the fossa are some shallow grooves for the deep temporal arteries. The temporal muscle arises from the entire extent of the fossa.

The zygomatic fossa is situated below the temporal fossa; it is bounded in front by the posterior surface of the superior maxillary and its malar process, and the posterior surface of the malar bone; above, by the inferior surface of the great wing of the sphenoid and the inferior surface of the anterior portion of the temporal; externally, by the zygoma and inferior maxillary bone; internally, by the external pterygoid plate; below, by the alveolar process of the superior maxillary; and, posteriorly, by the eminentia articularis.

The spheno-maxillary is a triangular fossa, situated at the upper inner, anterior part of the zygomatic fossa. It is bounded anteriorly by the posterior border of the superior maxillary; posteriorly, by the anterior border of the pterygoid process; above, by the under surface of the body of the sphenoid and zygomatic surface of the orbital process of the palate, and, internally, by the

external surface of the vertical plate of the palate. This fossa lodges Meckel's ganglion, and is traversed by the superior maxillary division of the fifth nerve. Five important foramina open into it, three posteriorly,—the foramen rotundum, the Vidian, and the pterygo-palatine; on the inner wall is the spheno-palatine, and below the posterior palatine. In addition, small nutrient foramina open into this fossa. The spheno-maxillary fossa communicates externally with the zygomatic fossa; anteriorly, with the orbit; internally, with the nasal, and, posteriorly, with the cranial cavity. Three fissures centre in the spheno-maxillary fossa,—the sphenoidal, the spheno-maxillary, and the pterygo-maxillary. The sphenoidal passes upward, outward, and forward; the spheno-maxillary downward, forward, and outward; and the pterygo-maxillary vertically downward.

The fissures are: The sphenoidal, triangular in shape, is between the greater and lesser wings of the sphenoid at the posterior part of the orbit, and has been described as the "foramen lacerum anterius." The spheno-maxillary fissure is bounded anteriorly and below by the posterior edge of the orbital surface of the superior maxillary and the malar; above, by the lower margin of the orbital surface of the great wing of the sphenoid. It communicates with the spheno-maxillary and zygomatic fossæ. The pterygo-maxillary fissure is bounded anteriorly by the posterior border of the superior maxillary; posteriorly, by the anterior border of the pterygoid process. This fissure is a continuation downward of the spheno-maxillary fossa.

A study of the skull entire is of much importance in the general science of anthropology, and a few facts bearing upon craniology may here be not uninteresting.

The skull differs in form in different races, in the sexes, and at the various ages or periods of life.

Age.—The skull in infancy presents an immensely large cranial and a small facial portion, the facial portion being but one-eighth as large as the cranial. The air-sinuses, such as the frontal, maxillary, and sphenoidal, are entirely undeveloped; the diploic structures are not formed until about the tenth year. The alveolar processes are but little developed, containing, however, the developing deciduous teeth and the germs of the permanent set. None of the articulations are firm, although such sutures as the frontal and that between the two halves of the inferior maxillary are beginning to give evidences of ossification. Large gaps are seen at different parts of the skull, notably at the anterior and posterior part of the superior surface, constituting the fontanelles. The original centres of ossification are exceedingly prominent, as is seen in the frontal and parietal eminences. These eminences or bosses serve as "fenders" to the skull of the infant, protecting the structures within from serious injury. In the adult female, the cranial portion of the skull predominates, constituting about three-fifths, the facial portion constituting but two-fifths of the skull. In the adult male, the cranial and facial portions are nearly equal. This is due to the greater development in the male of the large facial air-sinuses, and the normally larger formation of the facial bones. In old age the skull undergoes a retrograde change; the teeth fall out, the alveolar processes become absorbed, the symphysis menti becomes elevated and protrudes owing to the greater obliquity of the angle of the inferior maxillary, the air-sinuses diminish in size, and the cranial portion again largely predominates; in fact, the entire skull diminishes in size, the cranial as well as

the facial portion, but in the latter the change is more rapid and relatively much greater than in the former.

Sex.—The differences in the skulls of the sexes are not apparent before adult age, and again diminish as senility advances. In the adult male skull, as already stated, the facial and cranial portions are nearly equal; in the female skull the cranial portion is the larger. The female skull presents fewer departures from its infantile characters than the skull of the male; this is especially seen in the development of the facial sinuses. The facial angle in the female skull is, as a general rule, less acute than in the skull of the male. The weight of the male skull will average about twelve and a half ounces; the female skull averages about eleven ounces, making a difference of about 12 per cent. between the male and female skulls. All of the ridges, grooves, and other anatomical points are less prominent in the female skull than in the skull of the male.

Race.—The greatest difference exists in the skulls of the different races, and the study of these differences constitutes the science of craniology. Probably first in importance in the determination of race by a study of the skull is craniometry, or the measurement and proportions of the skull. If a horizontal section is made through the cranium just above the supra-orbital ridges, and the vault removed, the section presented is an oval. If the long diameter of this oval is taken to represent 100, and the transverse diameter measures 80 per cent. or more of the long diameter, the skull is called a broad, or brachycephalic, skull. If the transverse diameter is less than 75 per cent. of the long diameter, the skull is called a narrow, or dolichocephalic, skull. If the transverse diameter measures from 75 to 80 per cent. of the long diameter, the skull is called mesocephalic,—a term sug-

gested by Broca. This system of measures constitutes the cephalic index of Retzius, which is generally stated to be 80, or 78, or 75, which means so many per cent. of the long diameter, and is of much practical importance in differentiating between the skulls of different races, thus: The Mongol races are brachycephalic; the Lapps have the most brachycephalic skulls, the cephalic index in these people often rising as high as 90. Contrasted to these are the cephalic indices of the negroes, Caledonians, Australians, and others. In these people the cephalic index is about 72. The highest types of the white races have a skull the cephalic index of which is about 78. In taking these measurements it must be remembered that they are to be taken at the extreme points on the section. Another series of measurements, in which the vertical diameter is compared with the transverse, is also interesting, but less important than the index already discussed. In order to obtain the vertical diameter, a transverse section should be made vertically from the junction of the coronal and sagittal sutures, slightly oblique, downward, and backward, so that the lower portion of the section shall pass just in front of the occipital condyles. This measurement determines the relation of breadth to height, but, owing to the variations in the shape of the skull in the same races, it is not of much importance. An illustration, however, is not uninteresting; it must be understood, however, that the basis of measurement is the length of the head, as before described, and which is taken as 100. The index of height (vertical index) in the Kaffir is 73, in the Hottentot 71½; both skulls are dolichocephalic, with an index of 72; this, as can be seen at a glance, may at times serve to distinguish different skulls whose ordinary cephalic indices may be alike. Many other measure-

ments have been made, and, though interesting, are so variable and uncertain that but little practical importance attaches to them. Some are so wildly extravagant as hardly to reach even the dignity of a speculation.

It is important to ascertain the capacity of the cranium, and this depends somewhat upon the method employed. The best substances with which to fill the cranium are shot and water; if water is used, it is necessary to adjust a thin, very elastic, and highly distensible gum bag to the interior of the cranium, and then proceed to fill it; the liquid, of course, molds the gum bag accurately to the interior of the cranium. The water is then drawn off and carefully measured. When shot is employed the large openings must be filled with wax, and great care should be taken to allow the shot to roll in very gently, so as to avoid "packing." The capacity of the cranium is, as a general rule, greater in the higher than in the lower races. The female crania of any race are less capacious than the male crania of the same race. The capacity of the crania of the present century is, in all cases where the opportunities for study and comparison exist, larger than the crania of ten or twenty centuries ago. The average capacity is about 94 cubic inches in the superior races, while in 15 Australians it was 65 cubic inches.* As a general rule, it may be stated that, the greater the intellectual development of a race, the greater the capacity of the brain-case. The well-formed cranium of the European will measure 7¼ inches long, 5½ inches broad, and 5¼ inches in height; in circumference, about 21½ inches. The face presents certain measurements of decided interest. The average breadth of the face of the Briton is about 5 inches, the Hottentot averages 4½ inches, and the Chinese 5½ inches. The

* See Morton, "Crania Americana."

length of the face from the naso-frontal articulation, or transverse suture, differs also in different races. In the Esquimaux it is about 5½ inches; in the South African negroes, 4½ inches. Illustrations can be very largely multiplied, but the reader is referred to special treatises on the subject. The skull also presents certain "angles;" thus, if two planes are drawn vertically at the sides of the skull, they approach or recede from one another at their upper extremities. In order to facilitate the taking of such angles, the parietal goniometer (Quatrefage's) should be used.

The facial is probably the most important angle in the discrimination of skulls. Of these there are a multitude; that of Camper, having been the first suggested, is frequently alluded to. It consists of a line drawn from the glabella to the edge of the middle incisor tooth; this line is intersected by one drawn from the middle of the external auditory meatus to the anterior and inferior borders of the floor of the nose. An angle is here formed which varies from 70 to 80 degrees, and which diminishes as we pass from the higher to the lower races. The angle of Cloquet, when the alveolus is preserved, has some advantages; it consists of a line drawn from the glabella to the neck of the central incisor, and this is crossed by a line drawn through the external auditory meatus to the same point. Jacquart's angle, when the alveolus is absent, is probably the best; it consists of a line drawn through the external auditory meatus to the anterior nasal spine, and a vertical line drawn from the glabella to the base of the anterior nasal spine. If skulls are examined comparatively, by means of the facial angle, it must be remembered that the same angle should in all cases be employed, and the angle used should be noted, otherwise the measurements would

result in confusion. When the skull of a negro is viewed in profile, it is observed that the superior maxillary bones project, that the teeth are thrust obliquely forward, and that the malar bones also project forward. If a line is drawn in such a skull from the glabella to the mental process, it will fall considerably behind the canine teeth. Such a skull is called prognathous, and occurs largely in the natives of Africa and Oceanica. An orthognathous skull is one in which the facial structures do not project beyond a vertical line dropped from the glabella; in such a skull the teeth are generally fixed in a vertical position. The "Caucasian" race of Blumenbach are mostly orthognathous.

Many other details of great interest are beyond the purposes of this book, and the reader is referred to the numerous treatises on this subject.

THE SPINE.

The spine, or vertebral column, consists of twenty-six bones, including the sacrum and coccyx. The vertebræ, twenty-four in number, are piled one upon another, forming a strong, flexuous, tapering column which rests on the base of the sacrum. The vertebræ are divided into three groups,—superior or cervical, middle or dorsal, and inferior or lumbar. Each vertebra presents for examination a body, two pedicles, two laminæ, a spinous process, two transverse processes, and two pairs of articular surfaces. The body is in front; it is a cylindroid mass of bone, and forms, with the vertebræ above and below, the pillar of support to the head and upper extremities. Its superior and inferior surfaces are articular, slightly concave, and elevated at the circumference into a rim or lip. In front and at the

sides the body is concave from above downward, convex from side to side, and presents numerous foramina for the passage of vessels. Posteriorly it is flattened, slightly concave from side to side, and presents the opening of the sinus of the body, leading into a small cavity which lodges the veins of the body of the vertebræ. The opening is frequently double. The pedicles are two strong processes of bone, laterally somewhat compressed. They project from the upper, outer, posterior portion of the body, and are directed obliquely backward and slightly outward and upward. They are deeply notched below, slightly notched above, forming, when articulated with the vertebræ above and below, the intervertebral foramina. The laminæ are two strong, plate-like structures, which are continued backward from the pedicles, and are directed downward and inward, joining in the middle line to form the spine of the vertebra. Their upper and lower borders are rough, for the attachment of ligaments. The spinous process is formed by the fusion of the two laminæ behind. In the dorsal region the spines are directed obliquely downward; their apices are not cleft, but are more or less tuberous; the upper border is sharp. In the lumbar region they are strong and broad and are directed horizontally backward; the upper and lower borders are sharp and their extremities rough. In the cervical region the apices of the spines are cleft, and, except the seventh cervical, but little developed. The spinous processes serve for the attachment of muscles. The transverse processes project horizontally outward, in the cervical region, from the junction of the body and the pedicles; in the dorsal and lumbar regions, from the junction of the pedicles and laminæ. In the cervical region they are perforated by the vertebral foramen, for the transmission of the

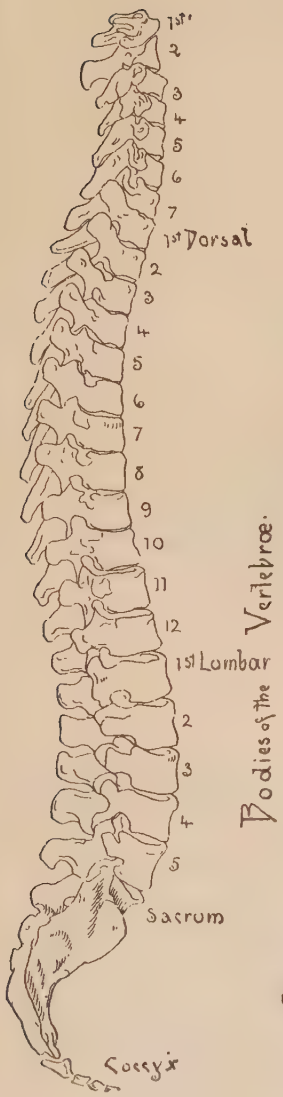

FIG. 33.—THE VERTEBRAL COLUMN, OR SPINE.

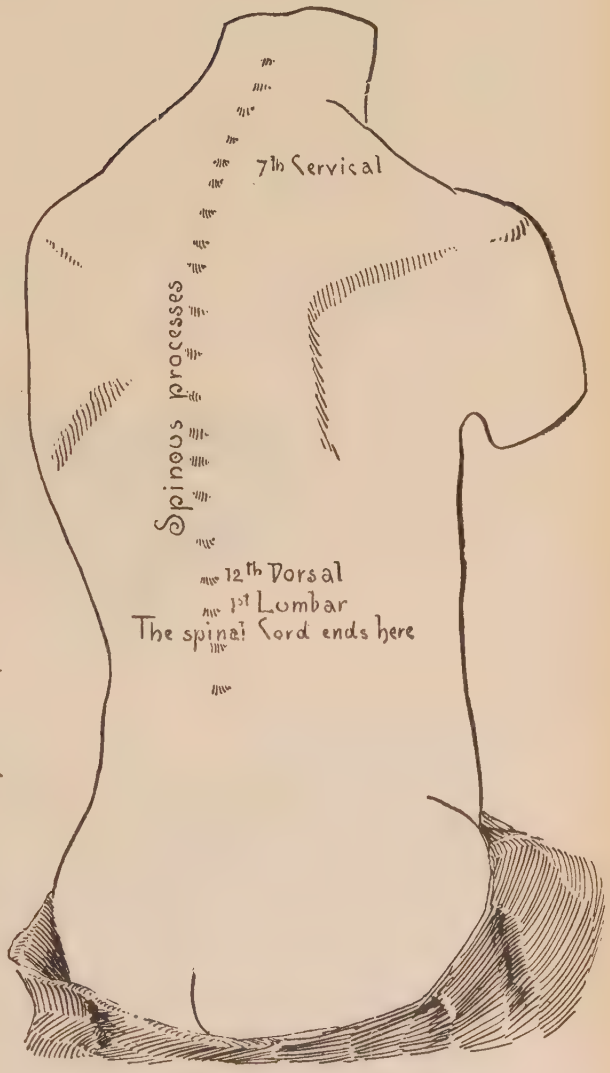

FIG. 34.—RELATION OF THE VERTEBRÆ TO THE NECK AND TRUNK.

vertebral artery; in the dorsal region their extremities anteriorly present an articulating surface, for articulation with the tubercles of the ribs; in the lumbar region they are thin and sharp. The articular surfaces consist of two pairs,—the superior and inferior. They are situated at the junction of the pedicles with the laminæ. The upper ones, in the cervical region, are directed upward, looking slightly backward; in the dorsal region their faces are directed obliquely backward and upward, becoming, in the lower dorsal and lumbar region, nearly vertical. The inferior pair, in the upper cervical vertebræ, look downward and forward, but in passing down

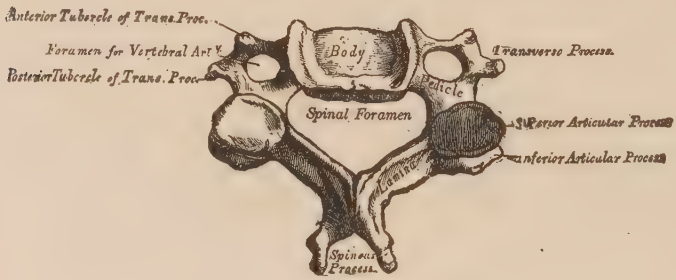

FIG. 35.—A CERVICAL VERTEBRA.

the vertebral column their faces become directed gradually more and more forward, looking slightly downward; in the lower dorsal and lumbar regions the plane of the articular surfaces is nearly vertical. A vertebra, as has been seen, consists of a solid segment anteriorly, from the sides and back part of which project the pedicles, which are continued backward into the laminæ, thus forming two lateral arches joined together posteriorly, and forming the spinous process. These arches inclose a large foramen, which, in the articulated spine, forms an osseous canal which lodges the spinal cord.

The cervical vertebræ are seven in number, and this

number is the same in all the mammalia, with a few exceptions. A cervical vertebra is distinguished by the foramen in its transverse process, the large size of the spinal foramen, the nearly horizontal position of the articular surfaces, and the bifid spinous process. The body is small, concave above, with a rather prominent rim, and is convex below. The transverse processes present two projections,—the anterior and posterior tubercles. The laminæ are narrow, long, and thin, and slightly overlap. The first, second, and seventh cervical are peculiar. The first cervical, or atlas, articulates above with the skull. It has neither body nor

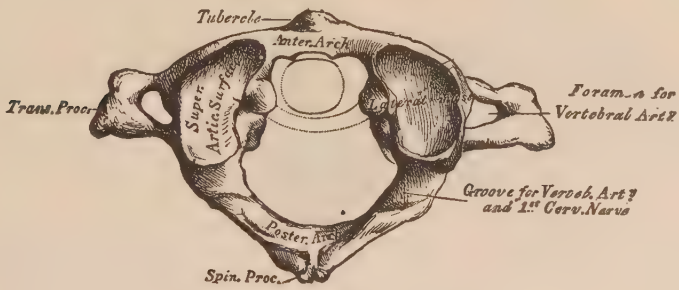

FIG. 36.—THE ATLAS.

spinous process, and consists of two arches—anterior and posterior—and two lateral masses. The anterior arch—about one-sixth of the bone—presents anteriorly a tubercle, posteriorly a slightly concave articular facet, for articulation with the odontoid process of the axis. The anterior arch is convex from side to side anteriorly; posteriorly, it is concave. The posterior arch forms nearly one-half of the circumference of the bone; it terminates posteriorly in a rudimentary spinous process, or tubercle, for the attachment of muscles. On the upper surface of the posterior arch, just behind the articular surface for the condyles of the occipital bone,

is a well-marked groove for the passage of the vertebral artery. The lateral masses present the superior and inferior articular surfaces. The superior articular surfaces are strongly concave, oval or reniform; their axes are directed forward and outward; they receive the condyles of the occipital bone. The inferior articular surfaces are flat, directed downward and slightly inward to articulate with the axis. Projecting inward from the inner borders of the lateral masses are the tubercles for the attachment of the transverse ligament, which passes behind the odontoid process of the axis, holding it in place against the anterior arch of the atlas; posterior to the

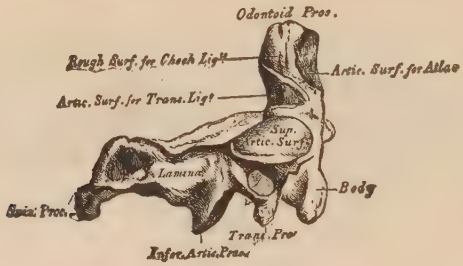

FIG. 37.—THE AXIS.

transverse ligament is the spinal foramen for the transmission of the cord. The transverse processes project from the outer border of the lateral mass and are broad and strong.

The axis is distinguished by a strong, pivot-like process, the odontoid, which projects upward from its body. This process is, in fact, the detached body of the atlas joined to the body of the axis. It forms the axis on which the atlas, and with this the head, rotates. The body presents anteriorly a ridge, and on each side of the ridge a depression for the attachment of muscles. It is prolonged below into a prominent lip, which overlaps the anterior part of the body of the vertebra below. Pos-

teriorly, the body is flat; inferiorly, concave from front to back. From the upper surface projects the conical odontoid process, which is slightly constricted at the base, and terminates above in a strong, blunt apex. On its anterior surface is the oval articular facet for articulation with the anterior arch of the atlas. At the base of the odontoid process, on each side, are well-marked nutrient foramina, sometimes two or more in number. The superior surfaces are flat, and look upward and slightly outward. They are placed upon the pedicles. Encroaching upon the transverse processes, they overhang the vertebral foramina. The inferior processes present forward and downward. The transverse processes project strongly downward, and are traversed by the vertebral canal, which at first ascends, then curves horizontally outward. The laminæ are strong; sharp above, thick below. On the upper surface are the vertebral grooves, which lodge the vertebral arteries as they pass behind the superior articular surfaces. Nutrient foramina, some of large size and rather constant in position, exist on the superior surface of the laminæ. The spinous process is bifid below. It affords attachment to muscles.

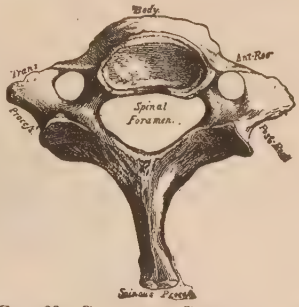

FIG. 38.—SEVENTH CERVICAL, OR VERTEBRA PROMINENS.

The seventh cervical, known as the vertebra prominens, is distinguished by its long, spinous process, which is neither split nor bifid. It serves for the attachment of the ligamentum nuchæ, or suspensory ligament of the head.

The dorsal vertebræ, twelve in number, present the following characters: Their bodies are heavier and larger

than in the cervical region. At the sides of the bodies, near the base of the pedicles, are two semi-oval, articu-

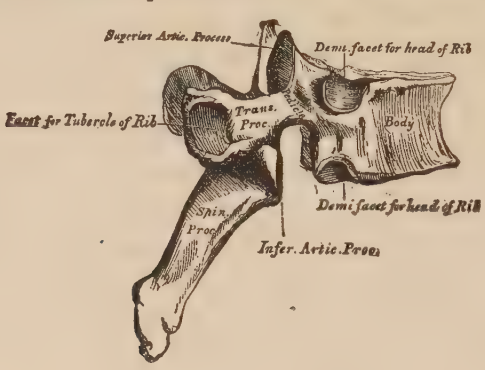

FIG. 39.—A DORSAL VERTEBRA.

lar facets, placed at the upper and lower borders; in the articulated spine they form articular surfaces for the

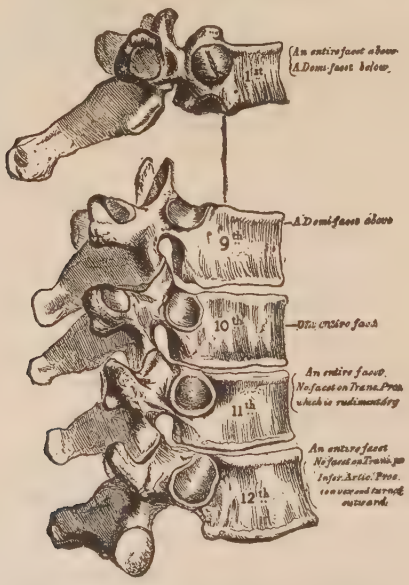

FIG. 40.—PECULIAR DORSAL VERTEBRÆ.

heads of the ribs. The transverse processes are thick and strong, clubbed at the extremities, and project back-

ward and outward. They present anteriorly a shallow, concave, articular surface for articulation with the tubercle of the rib. The pedicles are laterally somewhat flattened and project directly backward, encroaching upon the spinal foramen, making the dorsal portion of the spinal canal the least capacious. The upper dorsal vertebræ resemble the lower cervical, the lower dorsal, the lumbar. The first, tenth, eleventh, and twelfth have an entire facet at the side of the body; the ninth, a semi-facet above; the rest have a semi-facet above and below. The transverse processes of the eleventh and twelfth have no articular surface.

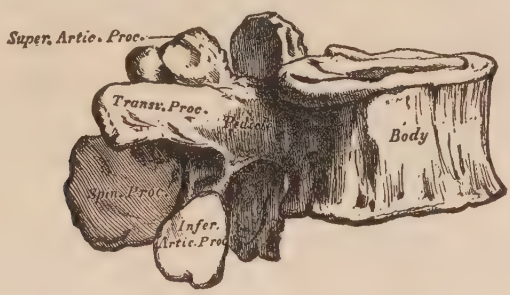

FIG. 41.—A LUMBAR VERTEBRA.

The lumbar vertebræ, five in number, are the largest vertebræ of the spinal column. The body is broad, slightly concave above and below, and presents strongly-curved rims. The pedicles are thick and of great strength. The superior articular surfaces look inward and slightly backward, their plane being nearly vertical. The inferior articular surfaces are directed outward and slightly forward. The laminæ are heavy plates of bone, which form a blunt, quadrilateral, spinous process, which projects horizontally backward. The transverse processes, directed backward and outward, are thin, blade-like, and light, in proportion to the rest of the bone.

Each vertebra develops from three primary centres, which appear about the middle of the second month. The primary centres are one for the body and one for each lateral arch. Besides these, six secondary centres appear later in life, completing the transverse and spinous processes, and in the articular plates on the superior and inferior surfaces of the body.

Exceptions.—The atlas develops by three centres,—one for the anterior arch and one for each lateral mass. The axis develops by six centres,—one for the body and one for each lateral arch, and three for the odontoid process. The lumbar vertebræ have, in addition to the number for the other vertebræ, a centre for each tubercle behind the superior articular surface.

The spine, viewed laterally and in profile, presents two anterior convex and two anterior concave curves,—the former in the cervical and lumbar, and the latter in the dorsal and sacral regions. These curves are largely due to the form of the bodies of the vertebræ, which, in the cervical region, are thicker anteriorly than posteriorly; in the dorsal region they are thicker posteriorly, and in the lumbar, especially the fifth lumbar, thicker anteriorly than posteriorly, as in the cervical region. The spinal canal is largest in the cervical, next in the lumbar, and smallest in the dorsal region. There is a limited motion in every intervertebral articulation, but, by the combined movement of the vertebræ upon one another, a great variety of movements, such as bending and lateral rotation of the trunk and head, are possible. The articulations between the cervical vertebræ admit of the greatest motion, next in the lumbar, and least in the dorsal. The direction of the spines of the dorsal vertebræ downward locks them together, and the position and plane of the articular surfaces also serve to give rigidity to this

part of the spinal column. The vertebræ gradually increase in size from the axis to the first dorsal, then decrease to the fifth dorsal, and then increase in size from the fifth dorsal to the fifth lumbar. The intervertebral foramina are largest in the lumbar, next in the cervical, and smallest in the dorsal region.

THE SACRUM.

The sacrum is a wedge-shaped bone, which sets between the two ossa innominata. It presents for exam-

FIG. 42.—THE SACRUM, ANTERIOR SURFACE.

ination a base, an apex, two lateral borders, and an anterior and posterior surface. The base presents upward, and supports the spinal column. The apex, directed downward, articulates with the coccyx. The lateral borders articulate with the ossa innominata. The bone is flattened antero-posteriorly, and strongly curved. The anterior surface is smooth, markedly concave from above downward, slightly so from side to side. About an inch on either side of the median line are the four

anterior sacral or intervertebral foramina for the transmission of the sacral nerves. They are arranged in pairs. The first pair are the largest; the others decrease gradually in size from the first to the last. The first and second pairs are ovoid, sometimes reniform, with the long axes vertically; the superior, inner, and inferior borders are abrupt and rounded. Externally the approach to the foramina is by a broad, shallow groove. The third pair are round. The fourth pair are oval, with the long axis obliquely upward and outward. Running horizontally between the sacral foramina are well-marked ridges, which indicate the original separation of the bone into five pieces. At the junction of the anterior surface and base the sacrum presents a prominent, sharp lip, called the promontory, which intensifies the angle formed by the articulation of the sacrum and the last lumbar vertebra.

The posterior surface is irregular and rough. Running along the median line is a strongly-marked, irregular crest, formed by the incomplete fusion of the rudimentary spinous processes. About an inch on each side are the posterior sacral foramina, arranged in pairs and opposite the anterior. They transmit the posterior sacral branches of the spinal nerves. The posterior sacral foramina are smaller in size than the anterior, but have nearly the same form. The superior pair are overlapped by a sharp plate of bone along their inner borders, and below terminate in a groove. The posterior surface mainly affords attachment to muscles and ligaments. The superior portion, or base, presents a central articulating surface, the opening of the sacral canal, and at the sides of the articulating base expanded surfaces of bone called the alæ. The articulating surface is broad, convex anteriorly, flattened posteriorly, surrounded by a

prominent rim, which in front curves downward to form the promontory. The alæ project laterally; they are trilateral, rough surfaces, continuous with the anterior surface by a rounded border. Numerous foramina penetrate these surfaces and afford exit to a great number of veins.

The apex articulates with the coccyx. It is deficient behind, exposing the termination of the sacral canal between two well-marked processes, which project down-

FIG. 43.—THE SACRUM, POSTERIOR SURFACE.

ward, and known as the sacral cornua. The lateral borders of the sacrum serve principally for articulation with the ossa innominata. The articular surfaces are ear-shaped, and are designated the auricular surfaces; they measure about two and three-fourths inches long, by one inch in width. Just behind the auricular surfaces, near the upper part of the bone, is the digital fossa, for the attachment of strong ligaments. Below the auricular surfaces the bone is rough, for the attachment of the sacro-sciatic

ligaments. If a vertical section through the median line of the sacrum is made, the sacral canal, continuous with the spinal canal, is laid open. It is large above, but becomes rapidly contracted as it descends toward the apex. The canal is flattened antero-posteriorly; opening into it are the four pairs of anterior and posterior sacral foramina for the transmission of the sacral nerves.

The sacrum is dveloped by thirty-five centres, which appear at the end of the second month of fœtal life, and in the upper segments of the bone. Each segment ossifies separately; they become joined together by distinct ossific centres, the lowest two first, and this process extends upward until the five segments form the one bone, which is not completed before the twenty-fifth year.

The coccyx is a rudimentary bone and consists of four segments; its base articulates with the apex of the sacrum.

BONES OF TRUNK.

THE HYOID BONE.

The hyoid bone is situated in front of the bodies of the third and fourth cervical vertebræ; it gives attachment to the muscles of the tongue, and is not articulated with the skeleton. The bone forms a half-circle, the convex portion presenting anteriorly. It consists of a body, two greater and two lesser cornua. The body is the central thick portion of the bone; it is flattened, and presents an anterior and posterior surface, superior and inferior borders. The anterior surface, convex from side to side, presents a median vertical ridge crossed by a horizontal line dividing the surface into four shallow fossæ, which afford attachment to the muscles of the tongue. The posterior surface is smooth and rounded, and gives attachment to the thyro-hyoid membrane. The superior border is bluntly rounded; the inferior

border, curved and irregular, is slightly everted. Articulating with the sides of the body are the greater cornua, and attached to the body by a plate of cartilage are two epiphyseal cartilages,—the lesser cornua. The greater cornua are somewhat flattened, taper from before backward, and terminate in clubbed extremities, which give attachment to the thyro-hyoid ligaments. The articulation between these processes and the body rarely persists beyond the fiftieth year. The lesser processes project slightly upward and backward from the body just above the articular surfaces for the greater cornua; they are short, conical processes, which afford attachment to the stylo-hyoid ligaments. The hyoid is an eminently elastic bone, consisting of equal portions of organic and earthy matter. The cornua are largely cartilaginous in character. This bone develops by five centres, one for the body and one for each cornu.

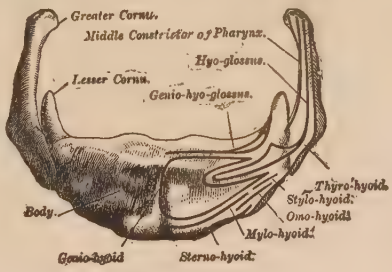

FIG. 44.—THE HYOID BONE.

THE THORAX.

The thorax is formed by the sternum and costal cartilages in front, the bodies of the vertebræ behind, laterally by the ribs. It is an osseo-cartilaginous structure, flattened antero-posteriorly, is highly elastic, and susceptible of an increase in all its diameters by the action of the muscles of respiration. It contains the heart, lungs, great vessels and nerves.

THE STERNUM.

The sternum, or breast-bone, is a flat bone situated in the median line, articulating with the clavicle above

and at the sides with the costal cartilages. It presents three portions,—an upper manubrium, middle gladiolus,

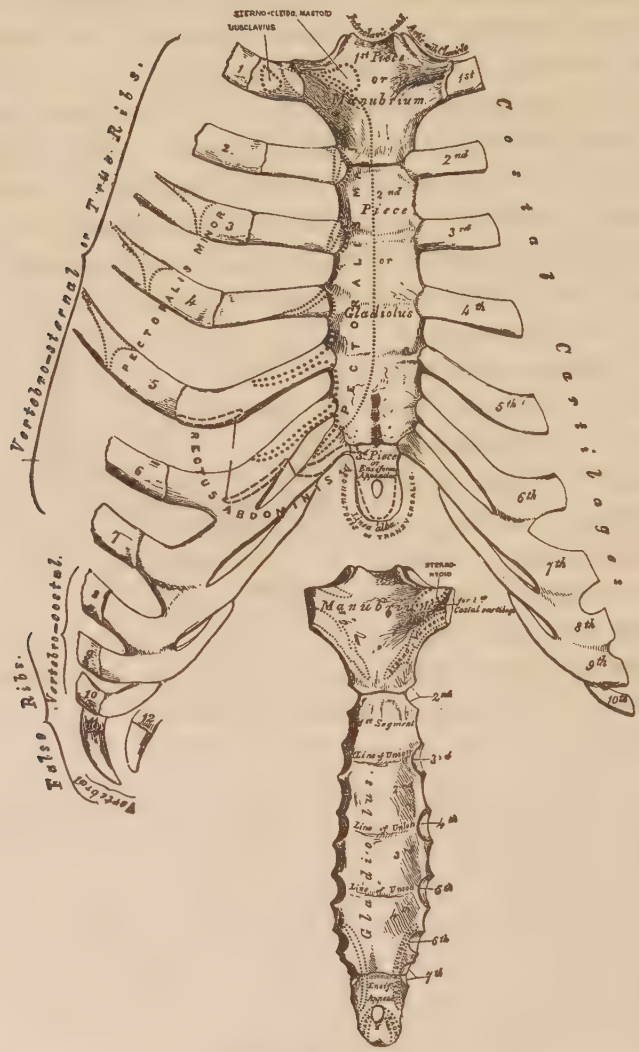

FIG. 45.—STERNUM AND COSTAL CARTILAGES.

and inferior or ensiform appendix. The manubrium is a heavy, flattened, trilateral plate of bone, which pre-

sents for examination an anterior and posterior surface; superior, inferior, and lateral borders. The anterior surface, convex from side to side, gives attachment to the fibres of the pectoralis major and sterno-mastoid muscles. The posterior surface, flat, gives origin to the sterno-thyroid and sterno-hyoid muscles. The superior border is thick, notched and rounded, and presents, at the angles of the superior and lateral borders, the concave articular surfaces for the clavicles. The lateral border presents, above, the articular facet for the first costal cartilage; this border then passes downward and inward, presenting at the angles with the inferior border a half-facet for the articulation with the second costal cartilage. The inferior border is rough and covered with cartilage, by which it articulates with the second piece of the sternum,—the gladiolus. The gladiolus, four to five inches long, one and one-half inches broad, one-third of an inch thick, is a flat plate of bone, presenting anteriorly four transverse ridges, which mark the original division of the bone into five pieces; the lower ridge is faintly developed. From this surface arise the fibres of the pectoralis major muscle. The posterior surface also presents the transverse ridges, but less marked. It presents a number of foramina for the passage of vessels. The lateral borders present four complete and superior and inferior half-notches. These notches are at the ends of the transverse ridges, and serve for the articulation of the costal cartilages. Between them the bone is concave and rounded. The superior border articulates with the manubrium, and presents at each angle the half-notch. The inferior border articulates with the ensiform appendix, and presents at each angle also a half-facet.

The ensiform appendix, largely cartilaginous in char-

acter, is thin, often curved, and terminates in a blunt point, which is sometimes bifid. Occasionally a foramen perforates the appendix. At each superior angle is a half-facet for articulation with the costal cartilage of the seventh rib. The ensiform appendix affords attachment below to the linea alba, posteriorly to some fibres of the diaphragm.

The sternum is developed by six centres: one for the manubrium, four for the gladiolus, and one for the upper part of the ensiform appendix.

THE COSTAL CARTILAGES

are arranged in ten pairs, of which the upper five are true costal cartilages and the lower five false. The true costal cartilages are those which pass directly from the sternal extremity of the rib to the sternum; the false costal cartilages are those which are more or less connected together. They are highly elastic, cartilaginous structures, which seldom undergo ossific change. The cartilages are flattened, the upper ones rather less, being oval on section. They increase in length from the first to the seventh; the upper four are directed nearly horizontally inward, the fifth and those below pass upward and inward; the sixth and seventh are connected by a single broad piece of cartilage; the eighth is attached to the seventh, and is also inserted into its inferior border about an inch external to the sternum; the ninth and tenth are similarly arranged. The anterior extremities of the eleventh and twelfth ribs articulate with short, spur-like pieces of cartilage, the apices of which are free.

THE RIBS.

The ribs consist of twelve pairs of flat bones, which assist in forming the posterior, lateral, and anterior wall of the chest. They are divided into five true, five false,

and two floating. The upper five are the true ribs; they arch outward from the vertebral column, and are continued to the sternum, each by a single piece of costal cartilage (the true costal cartilages). The false ribs are the sixth, seventh, eighth, ninth, and tenth, and are

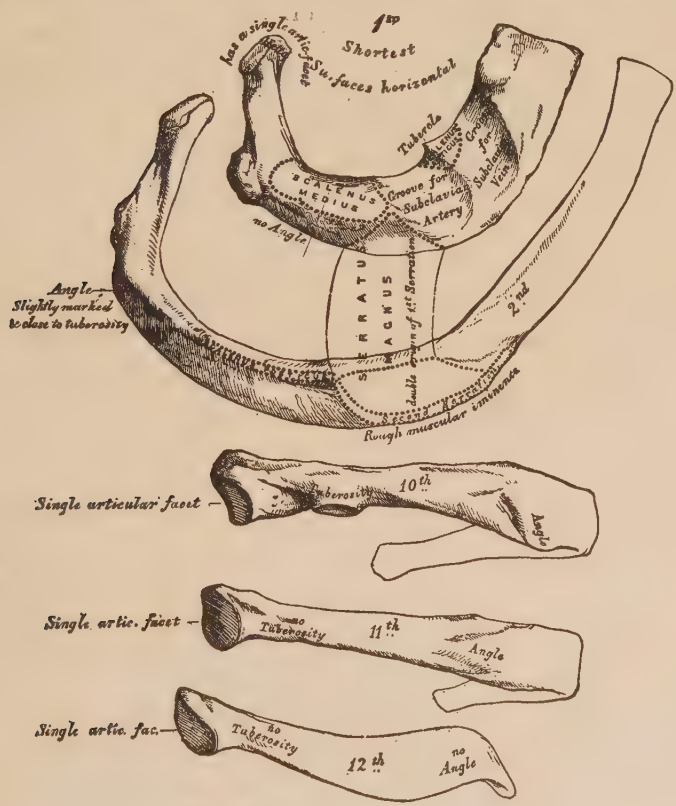

FIG. 46.—THE PECULIAR RIBS.

articulated anteriorly with the sternum through the medium of the false costal cartilages. The eleventh and twelfth are the floating ribs. A rib presents for examination a head, a neck, a tuberosity, shaft, angle and sternal extremity. The head, flattened, reniform in outline, presents two articular facets,—an upper smaller and

a lower larger, separated by a well-defined horizontal ridge. The neck, flattened antero-posteriorly, is rough for the attachment of ligaments and muscles. It is about one inch long, and lies in front and above the transverse process of the vertebra below. At the posterior inferior part of the neck, at the junction of the neck with the shaft, is the tuberosity,—a rough elevation of bone, well marked in the upper ribs. It presents an articular surface for articulation with the extremity of the transverse process of the vertebra below. The shaft is a flat, curved portion of the bone, which arches forward to the costal cartilage. It presents for examination an external and internal surface, superior and inferior borders, an angle and sternal extremity. The external surface, convex from above downward, curved from behind forward, presents, external to the tuberosity, the angle, at which the shaft makes an abrupt bend forward and downward. The angle becomes gradually farther removed from the tuberosity in passing from the second to the tenth rib. It is an oblique ridge, which affords attachment to the dorsal aponeurosis. The inner surface of the shaft is convex from above downward, and presents some small foramina for the nutrient vessels to the bone. The superior border is smooth and rounded; the inferior border is sharp and grooved along the inner surface for the passage of a branch of the intercostal artery and nerve. The sternal extremity is oval, concave, covered with cartilage, and articulates with the convex head of the costal cartilage. The ribs, with some exceptions (eleventh and twelfth), are developed by three centres,—one for the head, one for the tuberosity, and one for the shaft. The first, second, tenth, eleventh, and twelfth ribs are peculiar. The first rib differs in that its vertebral end, or head, has but one articular surface; it has no

angle; the shaft is flattened from above downward, and presents on its upper surface two shallow grooves,—the inner for the subclavian vein and the outer for the subclavian artery. Between these grooves, at the inner border, is the tubercle for the insertion of the scalenus anticus muscle. The under surface has no groove for the intercostal vessels. It is not twisted on its axis, and rests on a plane which both extremities and the shaft touch. The second rib has a slight angle, is but little twisted on its axis, and presents an ill-defined groove along its inferior border posteriorly.

The tenth rib has a single articular surface on the head, and the angle is not so strongly marked. The eleventh and twelfth ribs have no tuberosity—a single articular surface; the eleventh a slightly-marked angle, and the twelfth none at all. The eleventh and twelfth ribs have no attachments to the sternum.

THE CHEST.

The chest is an osseo-cartilaginous cage, which in general form may be said to be a truncated cone, flattened antero-posteriorly. It is formed behind by the twelve dorsal vertebræ and the ribs to their angles; laterally, by the shafts of the ribs; anteriorly, by the shafts of the ribs, costal cartilages, and sternum. Its transverse diameter exceeds the antero-posterior at every plane. Its antero-posterior diameter increases decidedly in passing from the upper to the lower part of the chest. This is due to the increasing length of the fourth, fifth, sixth, seventh, and eighth ribs and costal cartilages thrusting the sternum forward as it descends, and to the strong anterior concave curve of the bodies of the dorsal vertebræ. The upper opening of the chest is an osseous ring formed by the first dorsal vertebra, the first ribs and

first costal cartilages, and the manubrium. The lower opening of the chest is irregular and is limited anteriorly by the ensiform appendix, the costal cartilages, the free extremities of the eleventh and twelfth ribs, the twelfth rib, and twelfth dorsal vertebra. Along the median line, posteriorly, are the spines of the dorsal vertebræ, and on either side the chest presents the broad dorsal grooves, which are about one and a half inches in depth close to the spinous processes, but which become

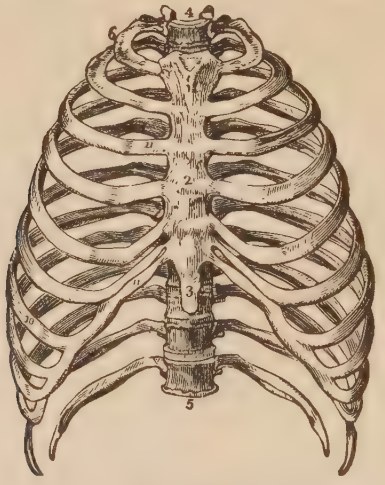

FIG. 47.—THE OSSEOUS THORAX.
1, manubrium; 2, gladiolus; 3, xiphoid appendix; 4, first dorsal vertebra; 5, last dorsal vertebra; 6, first rib.

shallow externally toward the angles of the ribs, which serve to limit the grooves. They lodge the dorsal muscles, especially the fourth and fifth layers. Laterally, the chest is convex from before backward; anteriorly the chest is flattened, though prominent below, due to the advance of the lower part of the sternum. In the lower animals, as a rule, the chest is flattened from side to side, so that naturally they rest upon the side; in man the converse is true, for in conditions of muscular relaxation and at death he gravitates upon his back.

THE UPPER EXTREMITY.

THE SHOULDER.

The shoulder is formed by the clavicle and the scapula, and serves to connect the upper extremity with the trunk.

THE CLAVICLE

is classed among the long bones, although it does not possess a medullary cavity. It is shaped like the letter S, and presents two curves,—a sternal anterior convex and a scapular anterior concave. It articulates with the sternum and acromial process of the scapula, and forms

FIG. 48.—THE LEFT CLAVICLE, UPPER SURFACE.

the only osseous connection of the superior extremity with the skeleton.

It is placed horizontally; its articulations, arthrodial in character, and with the extraordinary elasticity of the bone, preserve the trunk from shock, the result of violence to the shoulder or upper extremity.

Owing to the peculiarities of its position and articulation, it allows of great latitude of motion. It consists of 39 per cent. organic and 61 per cent. inorganic matter. It presents for examination two extremities and the shaft. The outer extremity, including the outer one-third of the shaft, is flattened from above downward, presenting an upper and under surface, posterior and anterior borders, which are marked for the insertion of the trapezius and deltoid, respectively. The under surface presents the

conoid tubercle, which is directly above the coracoid process and gives attachment to the conoid ligament. Running outward and forward from the conoid tubercle is the oblique line. The posterior border is rough and convex; the anterior border is rough and concave. The inner two-thirds is prismoid in form and presents three borders,—anterior, posterior, and superior. The anterior, continuous with the anterior border of the external third, becomes indistinct toward the sternum. The posterior or inferior border is a well-marked ridge, which runs from the conoid tubercle to the rhomboid surface, an elliptical surface at the under part of the sternal end of the clavicle; this border is well marked, and separates

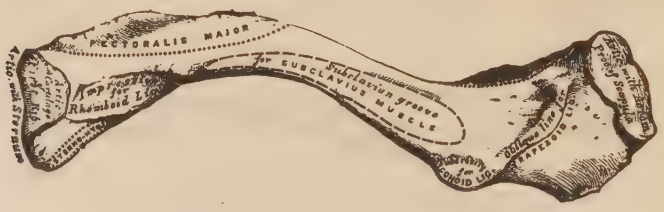

FIG. 49.—THE LEFT CLAVICLE, UNDER SURFACE.

the posterior from the inferior part of the bone. The superior border, continuous with the posterior border of the flat portion, is rough near the sternal end, for the origin of the sterno-mastoid muscle. These borders separate the three surfaces,—anterior, posterior, and inferior. The anterior surface is limited by the anterior and superior borders, and presents the nutrient foramen, which is directed outward. The inferior surface is that surface of the bone between the posterior and anterior borders. It presents near the sternal extremity a triangular facet for articulation with the first costal cartilage. External to this is the elliptical surface, slightly roughened for the attachment of the rhomboid ligament, and passing outward from the surface is the inferior border. The acro-

mial end of the clavicle is flat and presents an articular facet for articulation with the acromion process. The plane of the facet is oblique, the bone being beveled at the expense of the under surface. The sternal end of the clavicle presents a trilateral articular surface continuous with that for the first costal cartilage; it articulates with the sternum by means of an interarticular fibrocartilage. The clavicle develops by two centres,—one for the sternal end, the other for the shaft. A third centre is frequently found close to the articular surface for the scapula.

THE SCAPULA.

The scapulæ, or shoulder-blades, are two flat bones which, with the clavicles, form the osseous shoulder-girdle. Each is triangular in shape and presents for examination an anterior and posterior surface; superior, vertebral, and axillary borders; superior angle, inferior angle, and base. The posterior surface is slightly convex from above downward, and is divided into two fossæ by the spine, a shelf-like plate of bone, which projects at an angle of 50 degrees from the posterior surface of the scapula at its upper third. The spine of the scapula then curves forward and outward, and terminates in a flattened process of bone called the acromion, which articulates with the clavicle. The spine limits the supra-spinous fossa below and the infra-spinous fossa above. It begins at the vertebral border at a flattened surface, gradually becomes broader, and stops about half an inch from the base of the scapula,—in fact, at the neck of the bone. Its upper edge affords attachment to the trapezius muscle, its lower edge to the deltoid. The acromion process is the continuation of the spine; it arches over the glenoid cavity, and presents for examination an upper and lower surface, an anterior and posterior border, and an apex. The

anterior border is roughened for attachment of the trapezius muscle; near the apex is the oblique articular surface for the clavicle. This surface looks upward and forward, and facilitates the upward dislocation of the outer end of the clavicle. The posterior border is

FIG. 50.—THE SCAPULA, POSTERIOR SURFACE.

rough, for the attachment of the deltoid, which is also attached to the apex of the bone. In fracture of the acromion, flattening of the shoulder takes place, owing to the depression of the tip of the acromion. The superior surface is subcutaneous; the inferior surface presents an elevation known as the conoid tubercle, for

the attachment of the coraco-acromial ligaments. The posterior surface of the scapula above the spine forms the supra-spinous fossa; the surface below the spine forms the infra-spinous fossa; it is smooth, and serves for the origin of the infra-spinatus muscle. The anterior surface is concave and shallow, and constitutes the venter of the scapula; it is crossed by two or three curved lines.

FIG. 51.—THE SCAPULA, ANTERIOR SURFACE.

The subscapular muscle arises from the whole extent of this surface. The superior border is thin, concave, and presents at its middle a notch,—the supra-scapular,—which is converted into a foramen by the transverse ligament; it transmits the supra-scapular nerve. Projecting from the outer portion of the superior border at its junction with the base is the coracoid process, a strong, finger-

shaped process of bone which curves upward, forward, and outward above the glenoid cavity; it is rough, for the attachment of muscles and ligaments, and serves also for the protection of the shoulder-joint. The internal or vertebral border is the longest; it is slightly convex, and presents two well-marked lips, anterior and posterior, the anterior giving attachment to the serratus magnus muscle, the posterior to the supra- and infra- spinous muscles. The external or axillary border is thick and strong and corded in appearance; it is slightly concave, but irregular. It commences above at the base of the scapula and terminates at the inferior angle, and affords attachment to the triceps above, and to some of the fibres of the teres minor, teres major, and subscapular muscles. The superior angle is at the junction of the superior with the vertebral border; it is thin, and serves for the attachment of the levator anguli scapulæ and some of the fibres of the serratus magnus. The inferior angle at the junction of the vertebral with the axillary border is a blunt, triangular portion of bone, which gives attachment posteriorly to the teres major and some fibres of the latissimus dorsi, anteriorly to the fibres of the serratus magnus. The inferior angle is crossed posteriorly by the fibres of the latissimus dorsi; in extreme muscular action this muscle may slip beneath the inferior angle. The base, situated at the junction of the superior with the axillary border, supports the glenoid cavity, which is a shallow, oval-shaped depression for articulation with the head of the humerus. The glenoid cavity looks outward and slightly upward, and extends from the base of the coracoid process to the beginning of the axillary border. Its long diameter is vertical. It is broader below than above, and presents a well-marked rim, to which the glenoid ligament is attached. Just

behind the glenoid cavity the bone is constricted, forming the neck, to which is attached the capsular ligament. The base is the strongest part of the bone, and, owing to the large quantity of cancellous tissue here present, it is commonly the first part invaded by diseases affecting this bone.

The scapula develops by six centres,—one for the base, one for the coracoid process, two for the acromion, one for the inferior angle, and one for the posterior surface and vertebral border.

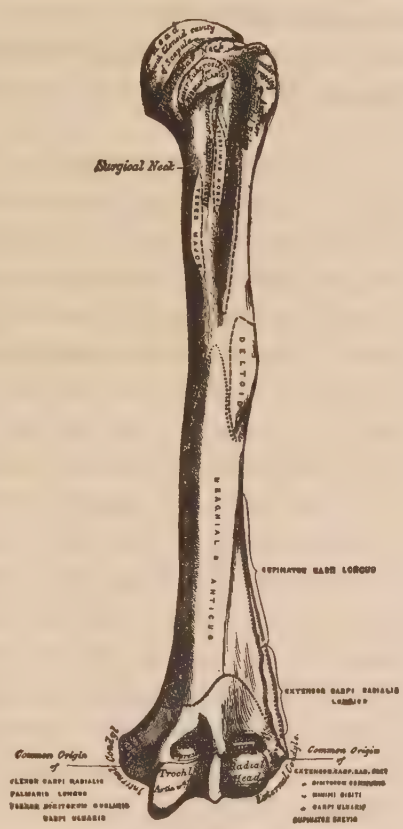

FIG. 52.—THE HUMERUS, ANTERIOR SURFACE.

THE HUMERUS.

The humerus belongs to the class of long bones. It is the longest and largest bone of the upper extremity, and presents for examination a shaft and two extremities. The upper extremity presents a scant, hemispherical head, which articulates with the glenoid cavity of the scapula; behind the head is a slight constriction, the anatomical neck, to which is attached the capsular ligament. External to the neck, on the anterior surface, are two blunt elevations of bone, the greater, or outer, and the lesser, or inner, tuberosities, separated by a deep groove, which

lodges the long tendon of the biceps muscle; it is called the bicipital groove. The greater tuberosity presents three facets, to which are attached the supra-spinous, infra-spinous, and teres minor muscles,—external rotators. To the lesser tuberosity is attached the subscapularis, an internal rotator muscle. Just below the tuberosities the bone presents a constriction, called the surgical neck, on account of the frequency of fracture at this place.

The shaft is cylindrical above, becomes prismoid below. It presents on its outer surface, about the middle, a shallow groove, which winds spirally from behind downward and forward; it lodges the musculo-spiral nerve and superior profunda artery, and is called the musculo-spiral groove. On the outer surface, at about the middle, is the deltoid surface, for the attachment of the deltoid muscle. The lower half of the shaft is very much flattened from before backward, presents three borders—external, internal, and anterior—and three surfaces. The external border begins below the deltoid surface, and terminates at the external epicondyle; it is blunt and rounded above and sharp below. The internal border begins at the middle of the bone, below a roughened surface, which serves for the attachment of the coraco-brachialis muscle; it runs downward, becomes sharp and crest-like, and terminates at the internal epicondyle, a prominent triangular projection of bone, which affords attachment to the flexor muscles of the forearm. The anterior border is slightly marked, and passes downward from the deltoid surface toward the coronoid depression. The external surface is between the anterior and external borders; it is somewhat rough, for the attachment of the brachialis anticus. The internal surface, smaller than the external, lies between the anterior and internal bord-

ers; it also gives attachment to the fibres of the brachialis anticus. The posterior surface of the humerus is divided obliquely by the musculospiral groove; it gives attachment to the triceps muscle. The lower extremity of the humerus is flattened from before backward; it is limited at the sides by the external and internal borders, which terminate in the internal and external epicondyles; below these are the articular surfaces for the radius and ulna. The external border is sharp, and serves for the attachment of the supinator longus above and the extensor muscles below. It terminates in the external epicondyle, which is the common origin of the extensor muscles of the hand and fingers. The inner border is sharp, and longer than the outer; it terminates below in a projecting mass of bone called the internal epicondyle, or, briefly, the internal condyle; it affords attachment to the tendons of origin of the flexor muscles of the forearm. The anterior surface presents two depressions—one, the coronoid depression, the larger, is just above the articular surface for the ulna, and accommodates the coronoid process; the other, the smaller, is above the radial head. These two depressions are separated by a well-marked ridge of bone. The posterior



Fig. 53.—The Humerus, Posterior Surface.

surface presents a deep, triangular depression for the accommodation of the olecranon process of the ulna; it is separated from the coronoid depression by a thin, translucent partition-plate of bone.

The lower end of the humerus presents the articular surfaces for the radius and ulna; the outer is the radial head; it is rounded anteriorly and below for articulation with the head of the radius; the inner articular surface is saddle-like, and curves around the inferior extremity of the humerus from the coronoid to the olecranon fossa; it articulates with the greater sigmoid cavity of the ulna.

The humerus develops by eight centres,—one for the head, one for each tuberosity, one for the shaft, one for the radial head, one for the articular surface for the ulna, and one for each condyle.

THE ULNA.

The ulna is the inner bone of the forearm. It presents for examination an upper and lower extremity and a shaft. The upper extremity is the larger, and articulates with the trochlear surface of the humerus. It presents the olecranon process,—a large, cuboidal process of bone which projects upward from the shaft. On its anterior aspect is a deep, hemispherical cavity,—the greater sigmoid,—for articulation with the humerus. This cavity terminates below in the coronoid process, and firmly grasps the trochlear surface of the humerus. At the side of the greater sigmoid cavity is a slightly concave articular surface,—the lesser sigmoid cavity,—for articulation with the head of the radius. The coronoid process has a strong base, and contributes in a great measure to the firmness of the elbow-joint. Attached to it is the tendon of the brachialis anticus muscle. The shaft is prismoid in form, and presents three borders—

outer, anterior, and posterior—and three surfaces—anterior, inner, and posterior. The outer border is sharp,

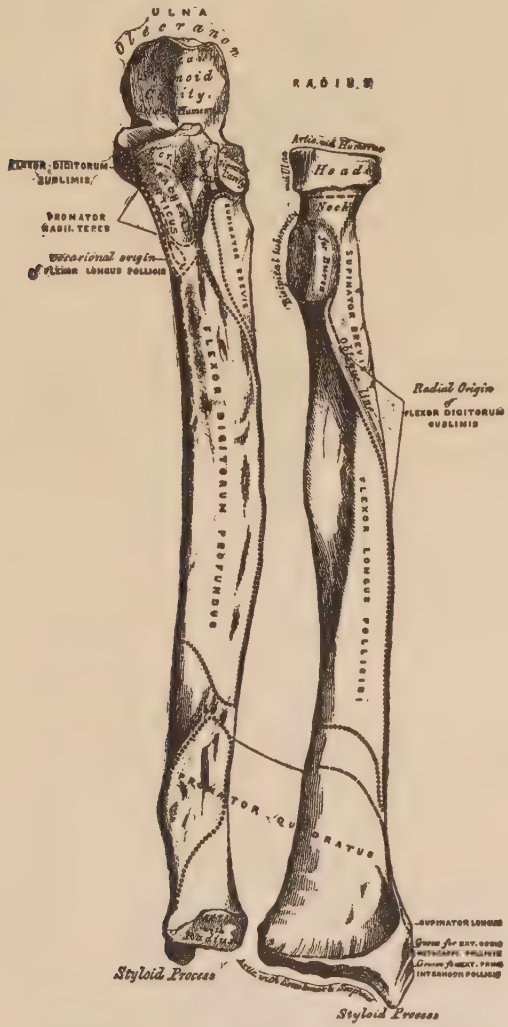

FIG. 54.—ULNA AND RADIUS, ANTERIOR ASPECT.

and looks toward the radius. It serves for the attachment of the interosseous ligament. The anterior border is rounded, and terminates below at the styloid process.

The posterior border is rounded and slightly twisted. It begins at the olecranon process, and is subcutaneous in the upper half of its extent. The anterior surface is flat, slightly concave, and broad. The posterior surface is slightly concave, and crossed by several lines. The inner surface is rounded, and subcutaneous in the lower part. These surfaces afford attachment to the muscles in this region.

The inferior extremity of the ulna is small, and presents an articular head and a styloid process. The head is rounded, and articulates below with the triangular cartilage. It presents a lateral articular surface for articulation with the inner surface of the lower extremity of the radius. The styloid process projects downward from the inner surface. It is about one-fourth of an inch long, blunt and strong, and serves for the attachment of the interarticular fibro-cartilage.

The ulna develops by three centres,—one for the olecranon, one for the shaft, and one for the inferior extremity. A secondary centre is often found in the coronoid process.

THE RADIUS.

The radius is the outside bone of the forearm. It is a long bone, and presents for examination an upper extremity, a shaft, and a lower extremity. The upper extremity presents the head,—a flattened, concave, shallow cylinder of bone, which articulates above with the outer or radial head of the humerus. The surface is slightly cup-shaped, about five-eighths inch in diameter. It is continuous with the lateral articular surface, which is an articular ribband of cartilage, deficient only at the outer fourth of the head of the bone. It articulates with the lesser sigmoid cavity. Immediately below the head is the neck, a marked constriction of the bone;

below this, anteriorly and to the inner side, is the tuber-

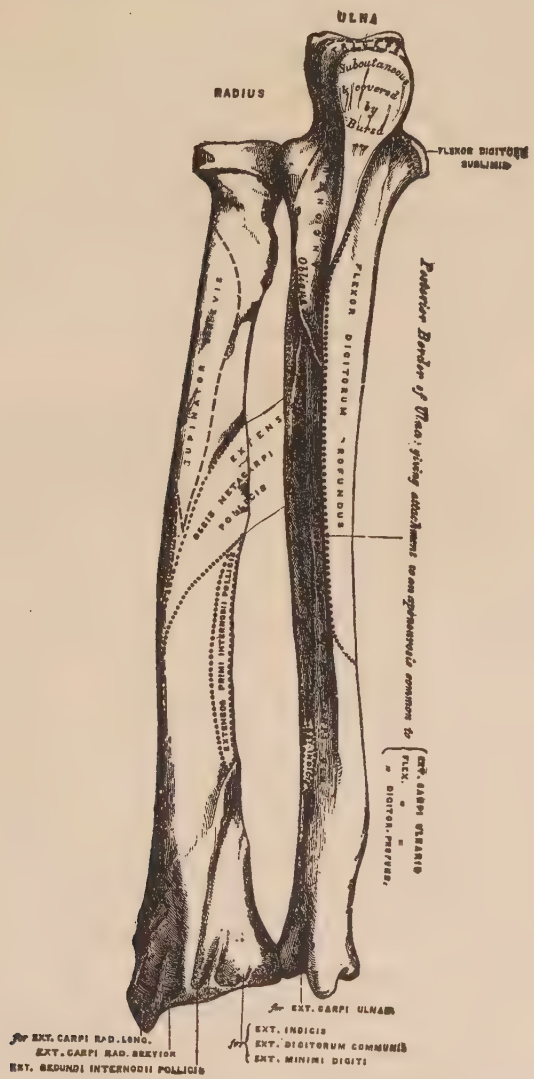

FIG. 55.—RADIUS AND ULNA, POSTERIOR ASPECT.

osity, a rough mass of bone, which affords attachment to the biceps tendon. The shaft is prismatic, presenting

three borders—anterior, posterior, and internal—and three surfaces—anterior, posterior, and external. The anterior border, also called the oblique line, starts below the tuberosity and terminates at the styloid process; the posterior border, rounded, terminates below in the posterior portion of the styloid process; the internal border is sharp, and affords attachment to the interosseous ligament. The surfaces afford attachment to muscles. The lower end of the radius is a cuboidal mass of bone, which presents a posterior, an outer, an anterior, an inner, and an inferior surface. The posterior surface, quadrilateral in form, is convex from side to side, and from above downward. It presents three grooves, which run in the direction of the axis of the bone. They are an outer, broad and shallow, which lodges the tendons of the extensor carpi radialis longior and brevior; the middle groove, narrow and deep, for the tendon of the extensor secundi internodii pollicis; the inner groove, broad and shallow, for the extensor tendons of the index and little fingers and the common extensors.

The outer surface is narrow and triangular, and terminates below in a strong, conical process of bone,—the styloid process. It presents two grooves,—an anterior, for the tendon of the extensor ossis metacarpi pollicis, and a posterior, for the tendon of the extensor primi internodii pollicis. The anterior surface is broad, concave from above downward, flattened from side to side; it serves for the attachment of the pronator quadratus muscle. The inner surface, quadrilateral and flattened, presents a slight concave, articular surface for the side of the head of the ulna. This articular surface is called the sigmoid cavity of the radius. The inferior surface is entirely articular, and triangular in outline. Its base is at the inner surface and its apex at the styloid process;

it is concave from before backward, strongly so from side to side, and presents a slight ridge dividing the surface into two articular facets, the outer for the scaphoid and the inner for the semilunar. It is seen that the articulation at the wrist is formed by the radius above and the scaphoid and semilunar below, the ulna being blocked out of the articulation by the interarticular fibrocartilage.

The radius develops by three centres,—one for the upper extremity and head, one for the shaft, and one for the lower extremity.

THE CARPUS, OR WRIST.

The carpus, or wrist, is made up of eight short bones, arranged in two rows. The first or proximal row are the scaphoid, semilunar, cuneiform, and pisiform. Those of the second or distal row, the trapezium, trapezoid, os magnum, and unciform. Each bone is cuboidal in form, and presents six surfaces. The anterior or palmar and the posterior or dorsal surfaces are rough, and serve for the attachment of ligaments. Together they form a series of close articulations, admitting of but little movement. Each bone is developed by one centre, except the unciform, which has two,—one for the unciform process and one for the rest of the bone. The pisiform is a sesamoid bone developed in the tendon of the extensor carpi ulnaris.

THE SCAPHOID

The scaphoid articulates above with the radius, below with the trapezium and trapezoid, and internally with the semilunar and os magnum. The internal surface, small and tuberculated, gives attachment to the external lateral ligaments of the wrist-joint; the dorsal surface enters into the formation of the dorsum of the wrist; the

palmar surface, rough and grooved, helps to form the osseous palm.

THE SEMILUNAR.

The semilunar articulates above with the radius, ex-

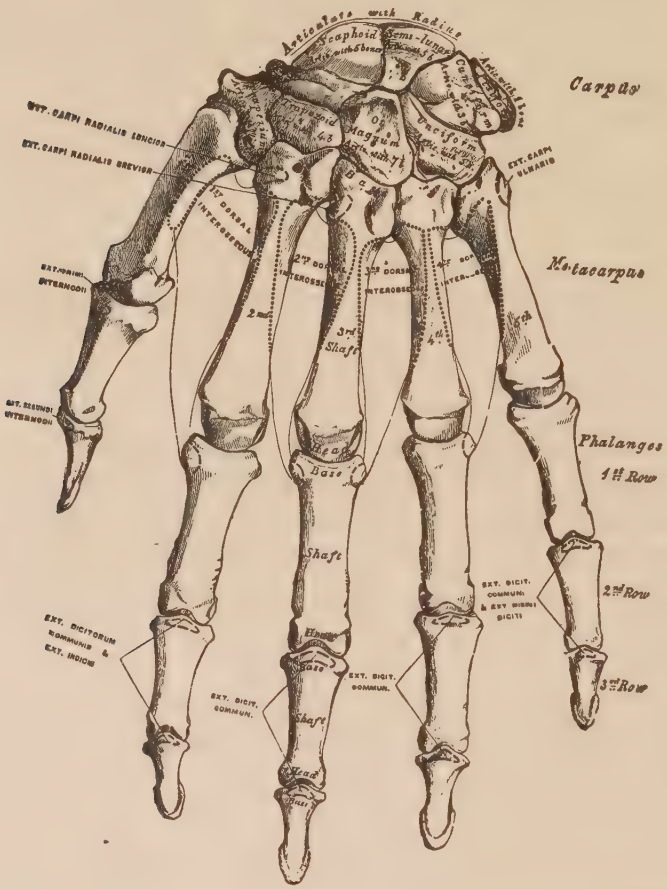

FIG. 56.—CARPUS, METACARPUS, AND PHALANGES, DORSAL SURFACE.

ternally with the scaphoid, internally with the cuneiform, inferiorly with the os magnum and unciform. The palmar surface is the larger and is rough; the dorsal, rough for ligamentous attachment.

THE CUNEIFORM.

The superior surface of the cuneiform is rough and non-articular; the inferior surface articulates with the unciform; the external surface articulates with the semilunar above and the unciform below. The internal surface projects and affords attachment to the external lateral ligament of the wrist. The dorsal surface is rough for the attachment of ligaments. The anterior or palmar surface presents an articular facet for the pisiform bone.

THE PISIFORM.

The pisiform, about the size of a large pea, is conoidal in form; its base presents an articular surface for articulation with the cuneiform.

THE TRAPEZIUM.

The trapezium articulates superiorly with the scaphoid, inferiorly with the first metacarpal bone, internally with the trapezoid and base of the second metacarpal bone. The palmar surface is grooved for the tendon of the flexor carpi radialis. The dorsal surface is rough.

THE TRAPEZOID.

The superior surface of the trapezoid articulates with the scaphoid; the inferior surface articulates with the second metacarpal; the external surface articulates with the trapezium; the internal surface articulates with the os magnum; the anterior and posterior surfaces are rough.

OS MAGNUM.

The os magnum is placed in the centre of the osseous palm; the superior surface articulates with the semilunar; the inferior surface with the third metacarpal principally, also slightly with the second and fourth; the external

surface articulates with the trapezoid; the internal surface articulates with the unciform; the palmar surface is broad and flat; the dorsal surface is broad, flat, and rough, for the attachment of ligaments.

THE UNCIFORM.

The unciform articulates above with the semilunar, below with the fourth and fifth metacarpals, externally with the os magnum, and internally with the cuneiform. The posterior surface is rough; the anterior surface presents the hook-like, unciform process; it projects downward from the junction of the palmar borders of the external and inferior surfaces; the anterior annular ligament is attached to it.

These carpal bones, together with the five metacarpals, form the osseous palm. The carpus proper, consisting of the two rows of bones, is convex from side to side on the dorsal aspect and concave from side to side on the palmar surface, where it presents prominences along both the external and internal borders for the attachment of the anterior annular ligament, which is attached externally to the scaphoid and trapezium, internally to the unciform process and the pisiform bone.

THE METACARPUS.

The metacarpus is made up of five long bones, each of which develop by two centres. The first metacarpal articulates with the trapezium and the first phalanx of the thumb; it presents a base, shaft, and head. The base is cuboidal and fits firmly against the trapezium; the shaft is prismoidal in form, convex on the dorsal surface, concave on the palmar. The head is broad and presents two condyles for articulation with the first phalanx of the thumb. It is the shortest, thickest and strongest metacarpal bone.

The second metacarpal articulates above with the trapezoid, and laterally with the trapezium, os magnum, and third metacarpal; its distal extremity articulates

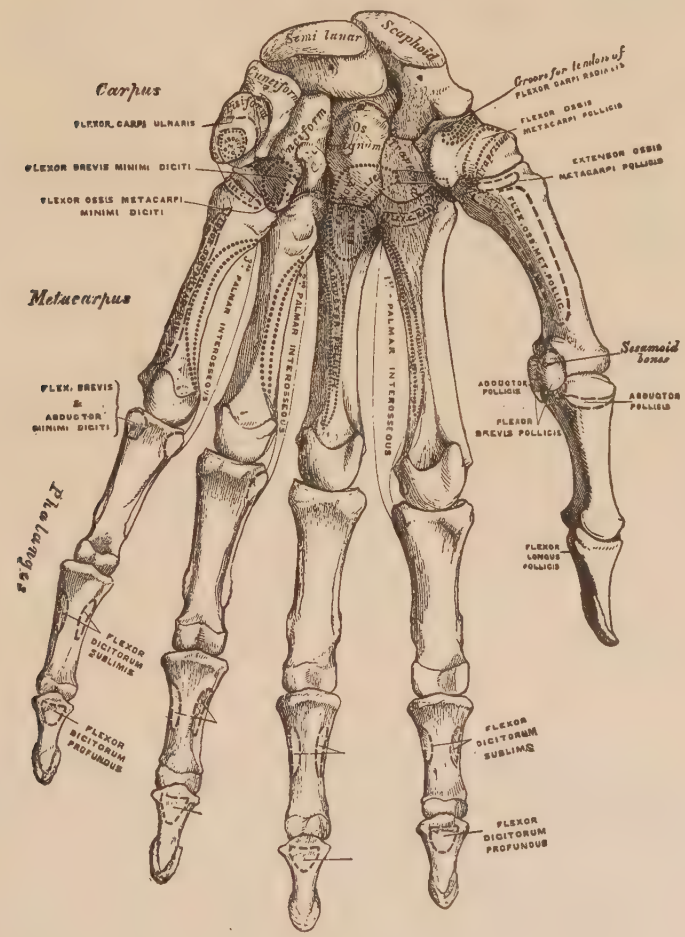

FIG. 57.—CARPUS, METACARPUS, AND PHALANGES, PALMAR SURFACE.

with the first phalanx of the index finger. Its base is large, cuboidal; the shaft long, prismoid, presenting a dorsal and two lateral surfaces; the head is rounded; the articular surface, as in the other metacarpal bones,

extends some distance on the anterior surface of the head, terminating in the inner and outer tubercles for the attachment of the lateral ligaments.

The third metacarpal articulates with the os magnum and second and third metacarpals; the distal extremity articulates with the first phalanx of the middle finger.

The fourth metacarpal articulates at the carpus with the unciform, slightly with the os magnum, and also with the third and fifth metacarpals; its distal end articulates with the first phalanx of the ring-finger.

The fifth metacarpal bone is the smallest and articulates above with the unciform and fourth metacarpal, below with the first phalanx of the little finger.

All these metacarpal bones are prismoid, having a posterior or dorsal surface and two anterior lateral surfaces. Each bone is bowed, concave on the anterior surface from end to end, and convex posteriorly. Their distal extremities, or heads, are rounded, and form the knuckles in flexion of the phalanges. Together with the bones of the carpus they make the osseous palm, which is convex posteriorly and concave anteriorly.

THE PHALANGES.

The phalanges are fourteen in number,—two for the thumb and three for each of the fingers. They are long bones, each developed by two centres. Each bone presents a base, shaft, and head, or distal extremity.

The phalanges of the first row are strong, cylindrical, flattened, and each presents a broad base for articulation with the head of a metacarpal. The shaft is flattened. The heads present two feebly-marked condyles for articulation with the bones of the second row.

The phalanges of second row are similar to those of the first, but smaller; the thumb has no second phalanx.

The phalanges of the third row are the smallest; on the anterior surface of the distal extremity they present the elliptical pulp plates,—rough surfaces which support the pulp. The distal phalanx of the thumb is the largest.

THE LOWER EXTREMITY.

THE OS INNOMINATUM.

The os innominatum, an irregular bone, forms, with its fellow, the anterior and lateral walls of the pelvis. It develops in three separate pieces, which become solidified into one bone at about the twentieth year.

The upper portion is called the ilium; the anterior portion, the pubes; the inferior portion, the ischium.

The ilium is the broad, flattened, and expanded portion of the bone; the two ilia form the false pelvis, and support the abdominal viscera.

The ilium presents for examination an outer and inner surface, a superior border or crest, an anterior and posterior border. The outer surface looks outward, downward, and backward. It is smooth, convex in front, concave behind, and is marked by three curved lines,—the superior, middle, and inferior. The superior is short, begins about an inch anterior to the posterior superior spine, and curves downward and backward. The middle curved line begins about an inch behind the anterior superior spine, and terminates near the great sacro-sciatic foramen. The inferior curved line begins near the anterior inferior spine, and terminates near the lower part of the great sacro-sciatic foramen. Below the inferior curved line is a depression for the attachment of the reflected tendon of the rectus.

The inner surface is bounded above by the crest, anteriorly by the anterior border, posteriorly by the posterior border, and below by a prominent ridge called the ilio-

pectineal line. This surface is smooth and concave for the anterior three-fourths of its extent, and is called the venter of the ilium. Posteriorly it is flattened, rough above for the attachment of ligaments; below it presents an ear-shaped, articular surface, called the auricular sur-

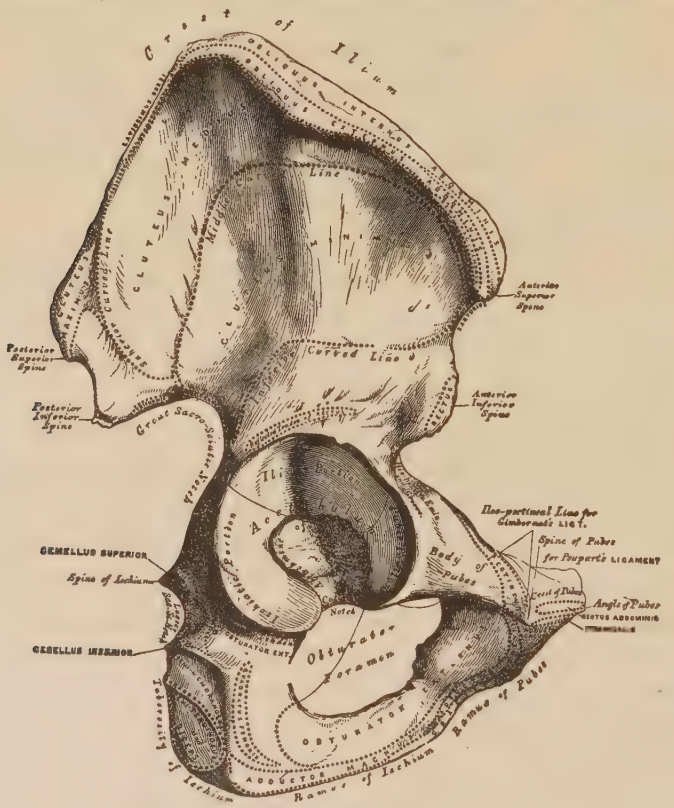

FIG. 58.—OS INNOMINATUM, OUTER SURFACE.

face, for articulation with the sacrum. The crest, or superior border, presents a double curve; it terminates anteriorly in the anterior superior spine, posteriorly in the posterior superior spine, and presents two lips,—outer and inner; also, an intermediate surface for the attachment of muscles. The anterior border presents the two

spinous processes, superior and inferior, separated by the superior notch; below the inferior spine is the inferior notch. The spinous processes are about one and one-half to two inches apart; they serve for muscular attachment. The posterior border presents the superior and inferior spines, separated by a notch; below the inferior spine is a deep notch, called the greater sacro-sciatic. The posterior inferior spine is prominent and strong, and gives attachment to ligaments.

The pubic portion of the os innominatum makes the anterior part of the pelvis; it presents a body and descending ramus. The body presents four surfaces—superior, inferior, anterior, and posterior—and an inner and outer extremity. The anterior surface is rough, for the attachment of muscles; the posterior surface is smooth and makes the upper part of the anterior wall of the pelvis; the superior surface presents, about three-fourths of an inch from the inner extremity, a conical elevation of bone, called the spine. Running inward from the spine is the crest for attachment of the rectus muscle. Passing outward from the spine is the beginning of the ilio-pectineal line, which runs outward and backward, becoming strongly marked; it limits the venter of the ilium, and, in the articulated pelvis, divides the upper, or false, from the lower, or true, pelvis. The inferior surface is smooth, and forms part of the upper boundary of the obturator foramen and presents a shallow groove for the passage of the obturator nerve and vessels. The inner extremity presents an oval surface; its long diameter is directed vertically; it is roughened, and affords attachment to the interarticular fibro-cartilage, interposed between the two pubic bones.

Passing downward and outward from the inner extremity of the body is the descending ramus. The outer

extremity is continuous with the ilium and ischium, the lines of union passing through the acetabulum,—a large, cup-like, articular cavity on the outer side of the os innominatum. Of the acetabulum the ilium makes two-fifths, the pubes one-fifth, and the ischium two-fifths.

The descending ramus, broad above, becomes thinner, and forms the inner boundary of the obturator foramen.

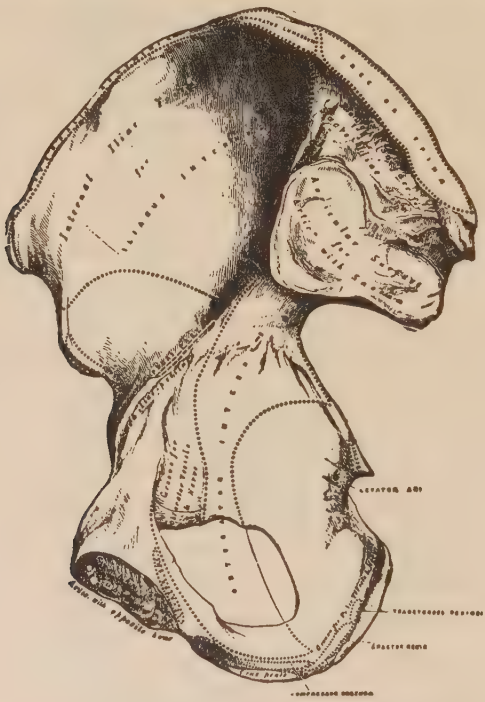

FIG. 59.—OS INNOMINATUM, INNER SURFACE.

Its anterior surface is rough, for the attachment of muscles; posteriorly it is smooth, and enters into the formation of the anterior wall of the pelvis. Its inner border presents the pudic groove,—a shallow groove formed by the eversion of the anterior margin of the ramus; it accommodates the pudic vessels and nerve. Its outer border is sharp, and forms part of the circumference of the obtu-

rator foramen; it affords attachment to the obturator membrane. The inferior extremity of the ramus is continuous with the ascending ramus of the ischium.

The ischium is the most inferior part of the os innominatum. It consists of two parts,—the body and the ascending ramus. The body, placed vertically, is a wedge-like mass of bone, presenting three surfaces,—external, internal, and posterior; a superior portion, which enters into the formation of the acetabulum; and an inferior, broad, expanded part, called the tuberosity. The external surface is rough, for the attachment of muscles; at its upper part is the prominent rim of the acetabulum, of which the ischium makes two-fifths. The internal surface is a smooth plane of bone, which descends vertically from the ilio-pectineal line, and forms the lateral wall of the pelvis; it is called the plane of the ischium. The posterior surface begins practically at the posterior inferior spine of the ilium, beneath which is a deep notch, the greater sacro-sciatic, formed into a foramen by the lesser sacro-sciatic ligament, which is attached to the spine of the ischium,—a spur-like projection from the posterior border of the bone, about three and one-half inches below the posterior inferior spine. The spine of the ischium projects directly backward, as a rule, in the female, while in the pelvis of the male sex it not unfrequently curves strongly inward; it varies in length from one-half to three-fourths of an inch. Below the spine of the ischium is the lesser sacro-sciatic notch, converted into a foramen by the greater sacro-sciatic ligament. The foramen thus formed is about an inch in diameter, and transmits the tendon of the internal obturator muscle, the internal pudic vessels and nerve. Below the lesser sacro-sciatic notch the posterior surface presents two depressions for the origin of the ham-string muscles. The

inferior portion of the ischium is called the tuberosity (in German, the "Sitz-beine," as the tuberosities support the weight of the body in the sitting posture). It presents an outer and inner border and an intermediate surface of bone. To the outer lip is attached the quadratus femoris and adductor magnus muscles. The inner lip presents a sharp crest, for the attachment of the great sacro-sciatic ligament; above this is the groove for the internal pudic vessels and nerve; it affords attachment also to the transversus perinei and erector penis muscles. The intermediate surface is rough, for the attachment of muscles. The ascending ramus of the ischium is slender and flattened, and joins the descending ramus of the pubes, completing the obturator foramen. Its external surface is rough, for muscular attachment; internally it is smooth and forms part of the anterior wall of the pelvis; at its inferior part is the continuation of the groove for the pudic vessels and nerve. Its inner border is everted, and affords attachment to the crus penis. The outer border is sharp, and forms part of the circumference of the obturator foramen, and affords attachment to the obturator membrane.

On the outer surface of the os innominatum, near its centre, is a large, cup-like cavity for articulation with the head of the femur. It is called the acetabulum, or cotyloid cavity. It presents a rim and inner surface. The rim is prominent, elevated above the surface of the bone, strong and heavy above, but deficient at its inferior portion, where it presents a notch—the cotyloid—for the passage of vessels and nerves into the hip-joint. The inner surface presents a ribband of articular cartilage, which skirts the inner margin of the cavity. It is about one inch broad and deficient below. The central portion is rough, for the attachment of the round ligament

of the hip-joint. The obturator foramen is a large hole, bounded above by the bodies of the ischium and pubes, below by the rami of the pubes and ischium, and posteriorly by the anterior border of the ischium. It is triangular in form, smaller in the female than in the male, and gives attachment to the thyroid or obturator membrane. Its upper border presents a groove for the obturator vessels and nerve.

The os innominatum develops by three centres,—one for the ilium, one for the ischium, and one for the pubes; in addition, there are four or five secondary centres. The three segments unite in the condyloid cavity, of which the ilium forms the upper two-fifths, the ischium the posterior and lower two-fifths, and the pubes the anterior and lower one-fifth. The rami of the ischium and pubes unite about the seventh year.

THE PELVIS.

The pelvis is formed by the two ossa innominata, sacrum, and coccyx. It is a ring of bone, through which the weight of the trunk, head, and upper extremities is transmitted to the lower extremities. It consists of two parts,—an upper, expanded portion, the false pelvis; an inferior, cylindrical part, the true pelvis. The false pelvis is deficient anteriorly; laterally and posteriorly it is formed by the expanded ilia and lumbar vertebræ. It is separated from the true pelvis by the ilio-pectineal ridge or line, which begins at the spine of the pubes and terminates at the promontory of the sacrum.

The inlet to the true pelvis, called the superior strait, is formed by the ilio-pectineal ridge. It is elliptical in outline, somewhat encroached upon posteriorly by the promontory of the sacrum. The true pelvis is a curved cylinder of bone, longer posteriorly than anteriorly, and

terminates at the outlet or inferior strait, which is very irregular, and formed laterally by the tuberosities of the ischia and posteriorly by the tip of the coccyx. Between the tuberosities of the ischia anteriorly is the pubic arch, formed by the rami of the ischia and pubes. The superior strait measures about five inches transversely and about four inches antero-posteriorly. The true pelvis is about four and a half inches in diameter. The inferior strait measures about four inches transversely and about four and a half inches antero-posteriorly. The depth of the true pelvis is about two inches anteriorly, about four and a half inches posteriorly. The axis of the true pelvis is a line equidistant between the anterior and posterior walls of the pelvis. The pelvis is tilted upward and forward, so that the promontory of the sacrum is about four inches higher than the upper border of the

FIG. 60.—THE PELVIS.

A A, antero-posterior diameter; B B, transverse diameter; C C, two oblique diameters; 1, sacro-iliac ligament; 2, anterior or lesser sacro-sciatic ligament; 3, posterior or great sacro-sciatic ligament.

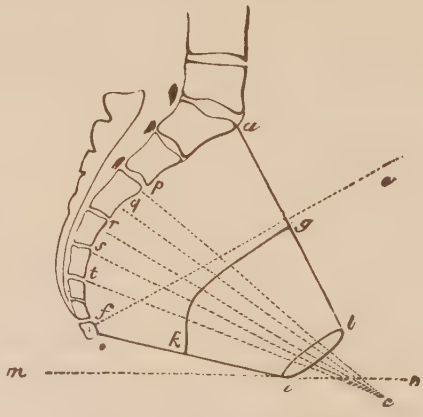

FIG. 61.—THE AXIS OF THE PELVIS.

a b, plane of the superior strait (brim); *o i*, plane of the inferior strait (outlet); *c*, the point where these two planes would meet, if prolonged; *m n*, a horizontal line; *e f*, axis of brim; *g k*, axis of cavity: *p q r s t*, various points taken on the sacrum to show the plane of the cavity at each point.

pubes. The plane of the superior strait forms an angle of about 60 degrees; the plane of the inferior strait varies, but approximates the horizontal. The pelvis presents some sexual differences; thus, in the vigorous adult—

MALE.	FEMALE.
1. The bones are heavy.	1. Comparatively light.
2. Osseous processes and margins are strongly developed.	2. Comparatively slight.
3. Ilia compressed.	3. Ilia expanded.
4. Diameter through the cotyloid cavities contracted.	4. Broader.
5. The diameters less than stated above.	5. More than stated above; pelvis more capacious.
6. The pelvis is deep.	6. Shallow.
7. Diameters of inlet and outlet irregular.	7. Diameters of inlet and outlet uniform and larger.
8. The ischia approach each other.	8. The ischia are everted.
9. The pubic angle or arch acute.	9. The pubic angle or arch obtuse.
10. The spines of the ischia are strong, often turned in.	10. The spines of the ischia small, point backward.
11. Large obturator foramen.	11. Smaller and triangular.

THE FEMUR.

The femur, or thigh-bone, is the longest and strongest bone in the body. It consists of a shaft and two extremities. The upper extremity presents a head, neck, and greater and lesser tuberosities. The head is globular, and makes three-fifths of a sphere. It is rough and dimpled at its summit, for the attachment of the round ligament. It is slightly compressed antero-posteriorly. Its axis is directed upward and inward. The neck is strong and flattened antero-posteriorly. Its upper

border is rounded and slightly concave; the lower border arched, rough, and thick, and terminates at the lesser trochanter. The anterior surface is convex, and presents many foramina for transmission of nutrient vessels; the posterior surface is convex and smooth. At birth the neck is nearly continuous with the axis of the shaft; in the adult it forms an angle of about 115 degrees; in old age it decreases, being often a right angle, or even less. The great trochanter is a cuboidal mass of bone, which projects upward from the upper end of the shaft. It presents an external and internal surface; anterior, superior, and posterior borders. The external surface is rectangular in outline and rough, for the attachment of muscles. The internal surface is small, and presents the digital fossa,—a depression which affords attachment to the tendon of the external obturator muscle. The superior border presents several facets for the attachment of muscles. The anterior border is rough and continuous with the anterior intertrochanteric line; the posterior border is prominent and rounded, and is continuous with the posterior intertrochanteric line. The lesser trochanter is a conical projection of bone from the poste-



FIG. 62.—THE FEMUR, ANTERIOR SURFACE.

rior internal portion of the base of the neck of the femur. It gives attachment to the conjoined tendon of the iliacus and psoas magnus. The anterior intertrochanteric line is rough, and serves for the attachment of the capsular ligament of the hip-joint. It runs obliquely downward and inward from the greater to the lesser trochanter. The posterior intertrochanteric line is very strongly marked, concave above, and affords attachment to the capsular ligament. It runs from the posterior border of the greater trochanter to the lesser trochanter. Passing down the posterior part of the shaft from the middle of the posterior intertrochanteric line is the quadrate line, a rough surface, one-fourth inch wide and about two inches long. It gives attachment to the tendon of the quadratus femoris muscle.



FIG. 63.—THE FEMUR, POSTERIOR SURFACE.

The shaft of the femur is cylindrical. It presents posteriorly the linea aspera, which runs the entire length of the shaft. It presents two well-marked lips, an inner and outer, and an inter-

mediate surface. The outer lip begins at the outer part of the great trochanter, and curves downward and inward, and then outward, to the outer epicondyle. The inner lip begins at the lesser trochanter and terminates at the inner epicondyle. At the lower fourth of the femur the divergence of the inner and outer lips of the linea aspera leaves a triangular, flat space, called the popliteal space. The linea aspera serves for the attachment of muscles. The shaft of the femur is cylindrical and slightly bowed forward. The inferior extremity is the most expanded portion of the bone, and presents the inner and outer condyles for articulation with the tibia. They are separated by the intercondyloid notch posteriorly, and, to some extent, below. The condyles project behind the plane of the posterior surface of the femur for nearly one inch. Their anterior surface is in the same plane as the anterior surface of the shaft. The inner condyle is the longer and larger; the outer condyle is the shorter and thicker. The articular surface passes upward some distance on the anterior surface of the condyles, but higher over the external than over the internal condyle.

FIG. 64.—SECTION OF THE HEAD OF FEMUR, SHOWING LAMELLÆ.

The fibres, A, by their rigidity, and the fibres, B, by their tenacity, tend to the support of the weight, while the latter fibres interlace with the arciform fibres, F.

Just above each condyle is a prominent tubercle,—the inner and outer epicondyles; to the inner is attached the tendon of the great adductor; to the outer epicondyle are attached the lateral ligaments of the knee-

joint. The inner epicondyle is the larger and most marked.

The shaft of the femur is a cylinder of compact or dense bone; the extremities are bulky, containing cancellated tissue covered by a thick shell of dense bone. The structure of the femur is such as to give the greatest longitudinal resistance for the quantity of bone it contains. The cancellated contents of the upper extremity are disposed in a series of curved plates, thus increasing the elasticity and carrying power of the head and neck of the bone.

The femur develops by five centres,—one for the shaft, one for the condyles, one for the head, and one for each of the trochanters.

THE PATELLA.

The patella is situated at the front of the knee-joint, and is the fulcrum over which the common extensor

(Anterior surface.) (Posterior surface.)

FIG. 65.—THE RIGHT PATELLA.

muscle of the thigh acts. It is a sesamoid bone which remains cartilaginous up to the third or fourth year, the earliest indication of a centre of ossification being seldom met with before the twentieth month. It is shaped somewhat like a horse-chestnut, and presents an anterior and posterior surface,—an upper broad portion, the base, and a lower, somewhat pointed, called the apex. The

anterior surface is ridged, convex, and presents many foramina leading into the bone. The posterior surface presents an oval articular surface divided into two unequal facets,—the outer, large for articulation with the external condyle of the femur; the inner, smaller for articulation with the inner condyle. The base presents upward, and has attached to it the four-headed extensor muscle. The apex is bluntly pointed, and serves for the attachment of the anterior ligament of the knee-joint, called the ligamentum patellæ.

The patella develops by one centre; it belongs to the class of irregular bones. Its cancellous tissue is often arranged with the lamellæ disposed transversely. The outside, compact shell is dense and rather thick.

THE TIBIA.

The tibia, or shin-bone, is the inner bone of the leg; it belongs to the class of long bones, and presents a shaft and an upper and lower extremity. The shaft is thick, strong, and prismatic in form; has three borders,—anterior, inner, and outer; and three surfaces,—external, internal, and posterior. The anterior border is long, curved, prominent, and sharp, and constitutes the "shin;" it begins at the outer side of the head of the tibia, and curves downward and inward, then slightly outward, and, finally, by curving strongly inward, terminates at the internal malleolus; for its middle three-fifths it is sharp and subcutaneous. The inner border is rounded and thick; it begins at the inner side of the head and terminates in the internal malleolus. The outer border is rather sharp, faces the inner border of the fibula, and serves for the attachment of the interosseous membrane. The internal surface is smooth and subcutaneous, and looks forward and inward. The external surface is some-

what rough, for the attachment of the tibialis anticus muscle; below, it is slightly twisted so as to present forward. The posterior surface is broad and flattened and presents at its upper part an oblique ridge, which runs from the outer border downward and inward across to the inner border. Just below the oblique line is the nutrient foramen, which passes downward. The inferior portion presents the grooves for the flexor muscles as they pass to the foot.

FIG. 66.—THE TIBIA AND FIBULA, ANTERIOR SURFACE.

The superior extremity or head is cylindroid in form and much expanded; its upper surface is flat and presents two shallow articular surfaces for the condyles of the femur; between these are two blunt, conical processes,—the spines for the attachment of the crucial ligaments. A short distance below the articular surfaces, anteriorly, is the tuberosity of the tibia,—a marked ovoidal mass of bone to which the ligamentum patellæ is attached. Externally, is a small articular facet for the head of the fibula. Posteriorly, the head is flattened and enters into the formation of the popliteal space. The inferior extremity is large and cuboidal; presents an anterior, posterior, internal, and

external surface, and an articular end. The anterior surface, over which the extensor tendons pass, is slightly concave and smooth; the posterior surface presents the grooves for the tibialis posticus, flexor longus digitorum, and flexor longus pollicis. The external surface, convex from before backward, is continued downward as a quadrangular process of bone, called the inner malleolus, which projects about three-fourths of an inch below the articular surface for the upper surface of the astragalus. On the outer side of the internal malleolus is the articular surface for the inner side of the astragalus. The external surface presents a triangular articular surface for the fibula. The inferior surface presents a trilateral articular surface for the astragalus, it is broad externally, smaller where it becomes continuous with the articular surface of the outer side of the inner malleolus.

In structure, the tibia presents a bulky head made of a shell of dense bone, inclosing a large quantity of cancellous tissue, arranged so as to present many large alveolar spaces. The lamellæ of the cancellous tissue are strong and thick, although short, and frequently present the Haversian system of canals. The bone develops by four centres,—one for the shaft, one for the upper extremity, one for the lower extremity, and one for the malleolar process.

THE FIBULA, OR SPLINT-BONE.

The fibula, or splint-bone, is the outer bone of the leg. It is long and slender, and belongs to the class of long bones. It presents a shaft, upper extremity, or head, and lower extremity, or outer malleolus. The shaft is prismoid, slightly twisted, and presents a well-marked inner border for attachment of the interosseous ligament. The posterior border is well-marked; the anterior border is

rounded. The surfaces are slightly rough, for the attachment of muscles. The head is pyramidal in form, presents an inner articular surface for the side of the head of the tibia; the external, anterior, and posterior surfaces are rough, for the attachment of ligaments; from its upper part projects the styloid process, to which is attached the tendon of the biceps muscle. The inferior extremity projects an inch to an inch and a quarter below the inferior surface of the tibia, and forms the outer malleolus. Posteriorly it presents the groove for the tendons of the peroneus longus and brevis. Externally it is subcutaneous; internally it presents the articular surface for the tibia; below is the articular surface for the outer side of the astragalus. The outer malleolus is somewhat pointed below, and serves for the attachment of ligaments.

FIG. 67.—THE TIBIA AND FIBULA, POSTERIOR SURFACE.

The fibula develops by three centres,—one for the shaft, one for the upper, and the other for the lower extremity.

THE TARSUS, OR ANKLE.

The tarsus, or ankle, is composed of seven bones,—astragalus, os calcis, scaphoid, cuboid, external, middle,

and internal cuneiform. Two bones—the os calcis and astragalus—form the posterior part of the tarsus; the

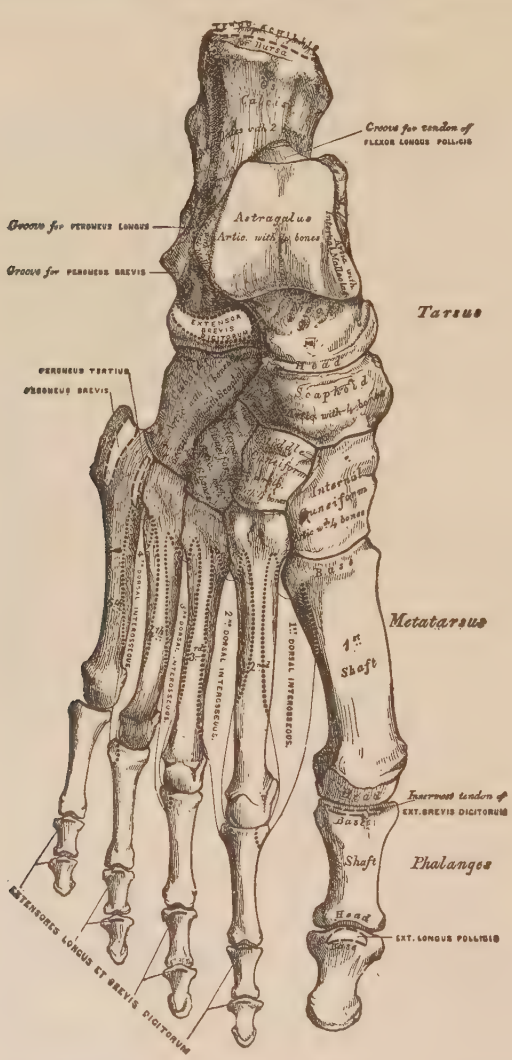

FIG. 68.—THE TARSUS, METATARSUS, AND PHALANGES, DORSAL SURFACE.

other five the anterior portion. They belong to the class of short bones; each develops by a single centre except

the os calcis, which has an additional one, by which the posterior portion is completed. The bones remain cartilaginous for some time after birth; in fact, complete ossification does not occur in some of them before the fifteenth year.

THE ASTRAGALUS.

The astragalus is the uppermost bone of the tarsus. It articulates above with the tibia, and laterally with the malleoli. It presents for examination a head, neck, and superior, inferior, external, internal, and posterior surfaces. The head is in front; it is rounded, and articulates with the scaphoid; behind the head the bone is constricted, and forms the neck. The superior surface presents a quadrilateral articular surface for the inferior extremity of the tibia; it is convex from before backward, and concave from side to side. The internal surface presents an articular surface for the internal malleolus. It is continuous with the articular surface on the superior portion of the bone. The external surface presents an articular facet for the external malleolus continuous with the superior articular surface. This arrangement of the superior and lateral articular surfaces on the astragalus makes a saddle of articular surfaces on the bone. Inferiorly the astragalus presents a large articular surface, divided into a larger posterior and a smaller anterior portion by a deep groove, for the attachment of interosseous ligaments. The anterior articular facet rests on the inferior calcaneo-scaphoid ligament, the posterior on the upper surface of the os calcis. Posteriorly, the astragalus presents a groove for the long flexor of the great toe.

THE OS CALCIS, OR HEEL-BONE.

The os calcis, or heel-bone, is the largest bone of the tarsus. It presents six surfaces,—anterior, posterior,

superior, inferior, internal, and external. The superior is divided into an anterior articular and a posterior free surface. The articular portion is divided by a groove which is opposite to the groove on the inferior surface of the astragalus, and serves for the attachment of interosseous ligaments. The posterior portion of the upper surface is rough, convex from side to side, slightly concave from before backward; it projects behind the astragalus for an inch and a half, and is practically the lever to the posterior surface of which is attached the tendo Achillis. The inferior surface is rough, convex, and somewhat irregular. It presents posteriorly the inner and outer tuberosities; the inner, much the larger, rests directly on the ground. Anterior to the tuberosities the bone is uneven and affords attachment to muscles and ligaments. The internal surface is concave for the passage of the flexor tendons and plantar vessels and nerves to the foot. The external surface is irregular; it presents a tubercle for attachment of the middle fasciculus of the external lateral ligament; also, the grooves for the peroneus brevis (above) and peroneus longus (below). The anterior surface articulates with the cuboid; it is a square facet, placed at right angles with the axis of the bone; at its outer edge is a tubercle, which is located immediately behind the articulation and forms a surgical landmark. The posterior surface gives attachment to the tendo Achillis; it is smooth above, but convex and blunt.

THE SCAPHOID.

The scaphoid articulates posteriorly with the astragalus, anteriorly with the three cuneiform, externally with the cuboid. Its upper surface is convex from side to side, and rough; inferiorly it is rough also for the attachment of ligaments. From its inner side projects a

tubercle, which serves as a guide to the astragalo-scaphoid articulation, externally broad and rough, and presents an articular surface for the cuboid; anteriorly are the three facets for the cuneiform bones; the posterior surface is slightly concave for the head of the astragalus.

THE CUBOID.

The cuboid articulates anteriorly with the fourth and fifth metatarsal, posteriorly with the os calcis, internally with the scaphoid and external cuneiform. The superior surface is slightly convex and rough; the external surface is narrow, and notched by the tendon of the long peroneal muscle; inferiorly it is irregular, and presents at its anterior part a groove, which accommodates the tendon of the peroneus longus muscle in its passage across the sole of the foot; behind the groove is the tuberosity of the cuboid for the attachment of plantar ligaments. The internal surface is rough, but presents two articular facets,—the posterior or smaller for the scaphoid, the anterior or larger for the external cuneiform. The anterior surface presents two articular surfaces, which are practically continuous; the inner, quadrilateral in form, is for the fourth metatarsal; the outer is triangular, and is for the articulation of the fifth metatarsal bone. The posterior surface is large, slightly concave, and articulates with the os calcis.

THE INTERNAL CUNEIFORM.

The internal cuneiform articulates posteriorly with the inner facet on the scaphoid, anteriorly with the first metatarsal bone, externally with the second metatarsal and the middle cuneiform. Its upper surface is convex and rough; internally it is rounded and subcutaneous; inferiorly it is irregular, and presents a tuberosity for the

attachment of the tendon of the tibialis posticus; externally are the two articular surfaces for the middle cunei-

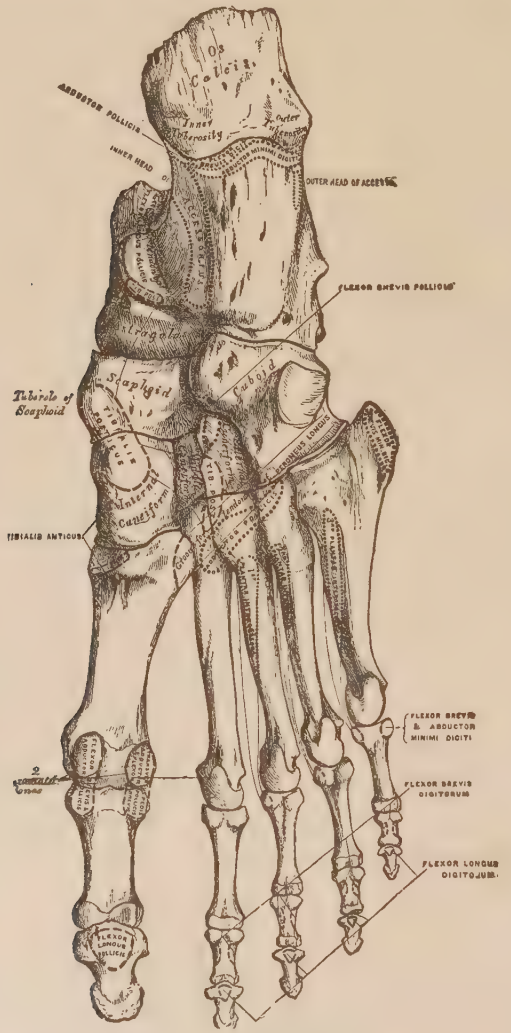

FIG. 69.—THE TARSUS, METATARSUS, AND PHALANGES, PLANTAR SURFACE.

form behind and the second metatarsal in front, separated by a rough surface for the attachment of ligaments.

THE MIDDLE CUNEIFORM.

The middle cuneiform presents five surfaces,—superior, external, internal, anterior, and posterior. The superior surface is quadrilateral and rough; the external presents the surface for articulation with the external cuneiform; the internal presents an articular strip along the superior border for articulation with the internal cuneiform; the posterior surface is triangular, and articulates with the second facet on the scaphoid; the anterior surface articulates with the second metatarsal.

The middle cuneiform is the smallest, and is shorter than either the external or internal, being mortised in between them.

THE EXTERNAL CUNEIFORM.

The external cuneiform articulates posteriorly with the third facet of the scaphoid; externally with the cuboid, and, by a small facet, with the side of the fourth metatarsal; internally with the middle cuneiform, and, by a small facet, with the second metatarsal; anteriorly with the third metatarsal. Its superior surface is rectangular and rough; inferiorly is a rounded border; the internal and external surfaces, in addition to the articular facets, are also rough, for the attachment of ligaments.

THE METATARSAL BONES.

The metatarsal bones are five in number,—first, second, third, fourth, fifth. They are long bones, and present a shaft, two extremities, and a medullary cavity, filled, in the adult, with yellow marrow. The shaft is compressed from side to side and slightly bowed, so as to be convex on the upper surface. The distal extremity is called the head, and is rounded in front; the proximal extremity, or base, is cuboidal, and flattened to articulate with the tarsal bones.

The first metatarsal, or metatarsal of the great toe, is the largest and strongest; the second is the longest, and is wedged in between the internal and external cuneiform bones, and articulates with the middle cuneiform; the fifth metatarsal presents the spine,—a rough, pointed process of bone, which projects outward and backward from the base.

THE PHALANGES.

The phalanges are fourteen in number,—two for the great toe, three for each of the four outer toes. They are minute long bones. The distal row present at the end of their plantar surfaces the pulp plates similar to those on the phalanges of the hand. The metatarsal bones and the phalanges are each developed by two centres.

The foot is thus seen to be composed of twenty-six bones,—fourteen phalanges, five metatarsal, and seven tarsal. These bones are so formed and articulated as to produce a convex superior surface, or dorsum, and a concave plantar surface. The bones at the outer side of the foot touch a plane, upon which they are placed at nearly all points. The inner border is raised or arched. The bones along the outer border of the foot are the os calcis, cuboid, fifth metatarsal, and phalanges; those along the inner border are the os calcis, astragalus, scaphoid, internal cuneiform, first metatarsal, and phalanges. The articulation between the astragalus and scaphoid and os calcis and cuboid are on a line called Chopart's, indicated by a plane passing directly in front of the crest of the tibia, transverse to the long axis of the foot. The tarso-metatarsal articulations are arranged as follows:—

The first metatarsal articulates with the internal cuneiform; the second metatarsal articulates with the middle

cuneiform; the third metatarsal articulates with the external cuneiform; the fourth and fifth metatarsals articulate with the cuboid.

The first metatarsal articulates with the tarsus at a plane most anterior to all these. The metatarso-tarsal articulation forms a curve passing outward and backward, the fifth metatarso-tarsal joint being most posterior; the second metatarsal is mortised in between the internal and external cuneiform bones; its articulation with the middle cuneiform is more than a half-inch posterior to the joint of the internal cuneiform and first metatarsal.

JOINTS AND LIGAMENTS.

1. A joint is a place of normal contact between bones.

2. A joint is a natural breach in the continuity of the skeleton.

3. A joint consists of the approximation of the articular parts of bones, covered by cartilage and held in position by ligaments.

Three elements are found in joints,—bone, cartilage, and ligaments. Bone has been described. Cartilage, or

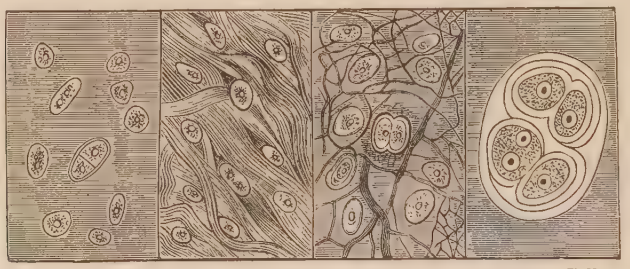

Hyaline Cartilage. Fibro-cartilage. Cartilage Cells.

FIG. 70.—DIAGRAM OF CARTILAGES.

gristle, is a non-vascular structure, divided into two kinds,—temporary and permanent. The temporary cartilage is that which precedes the structure of bone; thus the cartilaginous mold of the femur is first formed, and subsequently converted into or displaced by the bone elements proper. The permanent cartilage is found covering the articular ends of bones, and generally persists as cartilage during the life of the individual.

Cartilage is divided into three classes,—(1) hyaline, (2) fibro-cartilage, and (3) elastic. The hyaline carti-

lages consist of a homogeneous substance of firm consistence, in which there are imbedded a number of groups of cells, each group occupying a cavity lined by a distinct capsule. The temporary, articular, and costal cartilages are of this variety, and all, with the exception of the articular class, are covered by the perichondrium, —a fibrous investing membrane in which ramify the nutrient vessels.

The fibro-cartilages present a blending of the features of the hyaline cartilage with white fibrous tissue; all the interarticular cartilages belong to this class.

The elastic cartilages consist of a mixture of the hyaline cartilage with yellow elastic fibrous tissue; they are limited to the larynx and ear.

Fibrous tissue is of two kinds,—white and yellow. The white is very widely distributed and enters into the formation of the various cellular connective tissues and the fasciæ, and forms the skeletal structures of the various glands. It consists of bundles of fibres which are disposed parallel one to another; they do not run in a straight line, but are wavy or undulate in their course. Each bundle is composed of very delicate fibrillæ measuring $\frac{1}{40000}$ to $\frac{1}{20000}$ inch in thickness. A drop of acetic acid placed upon white fibrous tissue causes it to swell up, become indistinct, and lose its physical characters. It is developed from fusiform cells, which closely pack side by side, become elongated, and split up into the fibrillæ.

The yellow fibrous tissue is elastic and consists of twisted, curling fibres from $\frac{1}{20000}$ to $\frac{1}{4000}$ inch in thickness. Their genesis is by the stellate connective-tissue corpuscles of Virchow. It is probable that only the polar extremities of these cells change into the yellow

fibre. Acetic acid does not affect it. It is found in all elastic ligaments, such as the ligamentum nuchæ, those of the larynx, ligamenta subflava, and the elastic coat of arteries.

Articulations, or joints, are divided into freely movable, partly movable, and immovable. The freely movable are called the diarthrodial, and are divided into four classes:—

1. Arthrodial. These are gliding joints, such as the thyro-cricoid and acromio-clavicular articulations.

2. Enarthrodial. Ball-and-socket joints, such as the shoulder and hip.

3. Ginglymus, or hinge-joint, as the knee and interphalangeal.

4. Diarthrosis rotatoria, or lateral hinge-joints, as the superior radio-ulnar.

The partly-movable joints are called the amphiarthrodial; they are such as the intervertebral.

The immovable articulations are divided into three classes:—

- 1. Sutura.
  - (A) Sutura vera (true sutures); articulate by interlocking processes.
    - (*a*) Dentata; by tooth-like processes.
    - (*b*) Serrata; by saw-tooth-like processes.
    - (*c*) Limbosa; by beveled margins and tooth-like processes.
  - (B) Sutura notha (false sutures); articulate by apposition.
    - (*a*) Squamosa; by beveled margins.
    - (*b*) Harmonia; by abutting surfaces.

2. Schindylesis, or groove-and-tongue articulation, as the ethmoidal spine with the ethmoid, and the articulation of the vomer with the rostrum of the sphenoid.

3. Gomphosis, or socket-like joint, as the teeth.

ARTICULATIONS OF THE HEAD.

The only movable articulation is the temporo-maxillary; all the other bones of the head are immovably articulated together.

Temporo-maxillary.

BONES: Condyles of inferior maxillary and glenoid cavity.

LIGAMENTS:

CAPSULAR.

Origin—Neck of condyle.

Insertion—Circumference of glenoid cavity.

INTERARTICULAR FIBRO-CARTILAGE.

Origin—Capsular ligament and external lateral ligament.

Insertion—Tendon of external pterygoid and capsular ligament.

FIG. 71.—TEMPORO-MAXILLARY ARTICULATIONS.

a, temporal bone; *b*, inferior maxillary bone; *c*, capsular ligament; *d*, stylo-maxillary ligament; *e*, internal lateral ligament.

EXTERNAL LATERAL.

Origin—Tubercle of zygoma.

Insertion—Below neck of inferior maxillary and posterior border.

INTERNAL LATERAL.

Origin—Spine of sphenoid.

Insertion—Lower border of the inferior dental foramen.

STYLO-MAXILLARY.

Origin—Point of styloid process.

Insertion—Angle of inferior maxillary.

SYNOVIAL MEMBRANES: Two sacs, one above and the other below the interarticular cartilage.

NERVES: From the auriculo-temporal.

ARTICULATIONS OF THE HEAD WITH THE VERTEBRAL COLUMN.

Occipito-atloid.

BONES: Occipital and atlas.

LIGAMENTS:

TWO ANTERIOR.

Origin—Basilar process.

Insertion—Anterior tubercle and anterior arch of atlas.

ONE POSTERIOR.

Origin—Posterior margin of foramen magnum.

Insertion—Posterior arch of atlas.

TWO LATERAL.

Origin—Jugular process of occipital.

Insertion—Transverse process of atlas.

TWO CAPSULAR.

Origin—Circumference of condyles.

Insertion—Circumference of articular surface of atlas.

SYNOVIAL MEMBRANES: One in each joint.

NERVES: Suboccipital and filament from spinal accessory.

Occipito-axoid.

The axis and occipital bones are not in contact; the ligaments simply pass between them.

LIGAMENTS:

OCCIPITO-AXOID.

Origin—Odontoid process, posterior surface.

Insertion—In front of the anterior margin of the foramen magnum.

THREE ODONTOID.

Origin—Apex of odontoid process.

Insertion—Margin of foramen magnum by three slips.

NERVE: Suboccipital.

ARTERIES: From the vertebral.

ARTICULATIONS OF THE VERTEBRAL COLUMN.

(*a*) Ligaments pass between the bodies, (*b*) transverse processes, (*c*) articular processes, (*d*) laminæ, and (*e*) spinous processes.

(*a*) Those of the body:—

LIGAMENTS:

ANTERIOR COMMON.

Origin—Anterior surface of the bodies of vertebræ.

Insertion—From sacrum to axis.

POSTERIOR COMMON.

Origin and Insertion—Extends along posterior surface of the bodies of vertebræ from sacrum to axis.

INTERVERTEBRAL SUBSTANCE.

Origin and Insertion—Biconvex disks of fibro-cartilage interposed cushion-like between bodies of vertebræ.

(*b*) Between the transverse processes are the intertransverse ligaments, strong in the dorsal, absent in the cervical region, and membranous in the lumbar region.

(*c*) Between the articular processes. Capsular ligaments attached to the margins of the articular surfaces above and below.

(*d*) Laminæ: Yellow elastic ligaments passing from the lamina below to that above, the entire length of the spine, from the sacrum to the axis.

(*e*) Spinous processes: Interspinous, those passing between the spines; supraspinous, those attached to the apices of the spines.

ARTICULATIONS BETWEEN THE RIBS AND VERTEBRÆ.

(*a*) Heads of ribs and bodies of the vertebræ.

LIGAMENTS:

ANTERIOR, or STELLATE.

Origin—Neck of rib.

Insertion—By three slips: (1) to vertebra above, (2) to intervertebral disk, and (3) to vertebra below.

INTEROSSEOUS.

Origin—Head of rib.

Insertion—Intervertebral disk.

CAPSULAR.

Origin—Neck of rib.

Insertion—Margin of articular surfaces on vertebræ.

(*b*) Between the neck of the rib and transverse processes.

LIGAMENTS:

ANTERIOR COSTO-TRANSVERSE.

Origin—Neck of rib.

Insertion—Transverse process.

MIDDLE COSTO-TRANSVERSE.

Origin—Neck of rib.

Insertion—Transverse process.

POSTERIOR COSTO-TRANSVERSE.

Origin—Neck of rib.

Insertion—Transverse process.

CAPSULAR.

Origin—Circumference of articular facets.

LIGAMENTS OF THE STERNUM.

ANTERIOR: Three ligamentous bands running the entire length of the sternum.

POSTERIOR: Three ligamentous bands running the entire length of the sternum posteriorly.

COSTO-STERNAL ARTICULATIONS.

The costo-sternal articulations consist of seven pairs of costal cartilages articulated with the sides of the sternum.

LIGAMENTS:

ANTERIOR.

Origin—Anterior surface of sternum.

Insertion—Anterior surface of costal cartilage.

POSTERIOR.

Origin—Posterior surface of sternum.

Insertion—Posterior surface of costal cartilage.

CAPSULAR.

Origin—Surrounds the articular cavity.

ARTICULATIONS OF VERTEBRAL COLUMN AND PELVIS.

In addition to the ligaments between the vertebræ, there are:—

LIGAMENTS:

ILIO-LUMBAR.

Origin—Transverse process of last lumbar.

Insertion—Posterior superior spine and crest of ilium.

SACRO-LUMBAR.

Origin—Transverse process of last lumbar.

Insertion—Posterior part of ilio-pectineal line.

PELVIC ARTICULATIONS.

1, between the sacrum and ilium; 2, between the sacrum and ischium; 3, between the sacrum and coccyx; 4, between the pubes.

1. ARTICULATIONS BETWEEN THE SACRUM AND ILIUM.

LIGAMENTS:

ANTERIOR.

Origin—Anterior surface of sacrum.

Insertion—Anterior portion of ilium and ilio-pectineal line.

POSTERIOR.

Origin—Upper tubercles of sacrum.

Insertion—Rough surface on posterior part of ilium.

OBLIQUE.

Origin—Third tubercles of sacrum.

Insertion—Posterior superior spine of ilium.

2. ARTICULATIONS BETWEEN THE SACRUM AND ISCHIUM.

LIGAMENTS:

GREATER SACRO-SCIATIC.

Origin—Lower transverse tubercles of sacrum, adjoining inferior spine of ilium.

Insertion—Tuberosity of ischium and ramus of ischium; continued as falciform ligament.

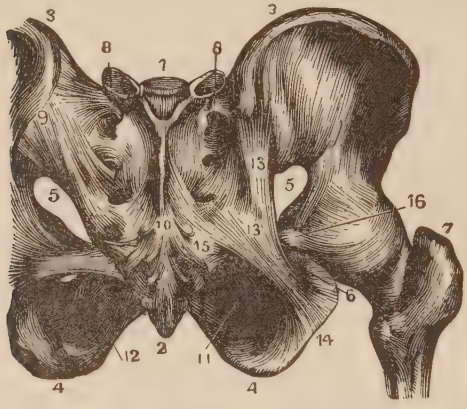

FIG. 72.—SACRO-ISCHIATIC ARTICULATIONS.

1, base of sacrum; 2, coccyx; 3, crest of ilium; 4, tuberosity of ischium; 5, greater sacro-sciatic foramen; 6, capsular ligament of hip-joint; 7, greater trochanter; 8, posterior ilio-sacral ligament; 9 and 10, lumbo-sacral ligaments; 11, oblique ligament; 12, obturator foramen; 13 and 14, greater sacro-sciatic ligament; 15, lesser sacro-sciatic ligament.

LESSER SACRO-SCIATIC.

Origin—Posterior lateral border of sacrum and coccyx.

Insertion—Spine of ischium.

3. ARTICULATIONS BETWEEN SACRUM AND COCCYX.

LIGAMENTS:

ANTERIOR.

Origin and Insertion—Fibres pass from anterior part of sacrum to coccyx.

POSTERIOR.

Origin and Insertion—Fibres pass from posterior part of sacrum to coccyx.

INTERARTICULAR CARTILAGE (sometimes wanting) is a disk of fibro-cartilage.

4. ARTICULATIONS BETWEEN THE PUBES.

LIGAMENTS:

ANTERIOR.

Origin and Insertion—Upper border of pubes interlaced with fibres of external oblique.

POSTERIOR.

Origin and Insertion—Passes across from one pubic bone to the other.

SUPERIOR.

Origin and Insertion—Passes across from one pubic bone to the other.

INFERIOR.

Origin and Insertion—Arches across from one pubic bone to the other, reducing the subpubic angle.

INTERARTICULAR CARTILAGES: Two in number; each is firmly applied by its outer surface to the pubic bone. There is a synovial membrane between the inner (free) surfaces of the cartilages.

STERNO-CLAVICULAR ARTICULATIONS.

LIGAMENTS:

ANTERIOR.

Origin—Anterior surface of manubrium.

Insertion—Anterior surface of the sternal end of clavicle.

POSTERIOR.

Origin—Posterior surface of manubrium.

Insertion—Posterior surface of the sternal end of clavicle.

COSTO-CLAVICULAR, or RHOMBOID.

Origin—Upper inner part of first costal cartilage.

Insertion—Rhomboid depression on inferior surface of clavicle.

FIBRO-CARTILAGE: Flat disk interposed between the bones; attached to costo-sternal articulation of first cartilage; inserted into the upper anterior part of the sternal end of the clavicle.

FIG. 73.—LIGAMENTS ABOUT THE SHOULDER-JOINT.

1, superior acromio-clavicular ligaments; 2, coraco-clavicular ligaments; 3, coraco-acromial ligaments; 4, transverse ligament; 5, capsular ligament; 6, coraco-humeral ligament; 7, tendon of biceps.

ACROMIO-CLAVICULAR ARTICULATIONS.

LIGAMENTS:

SUPERIOR.

Origin—Superior surface of acromion.

Insertion—Superior surface of adjoining end of clavicle.

INFERIOR.

Origin—Inferior surface of acromion.

Insertion—Inferior surface of adjoining end of clavicle.

CORACO-CLAVICULAR, or CONOID.

Origin—Conoid tubercle.

Insertion—Base of coracoid process.

CORACO-CLAVICULAR, or TRAPEZOID.

Origin—Oblique line of clavicle.

Insertion—Base of coracoid process.

SCAPULAR LIGAMENTS.

LIGAMENTS:

CORACO-ACROMIAL.

Origin—Posterior border of coracoid process.

Insertion—Apex of acromion.

TRANSVERSE. Passes transversely across the supra-scapular notch.

LIGAMENTS: SHOULDER-JOINT.

GLENOID.

Origin and Insertion—An ellipse of fibro-cartilage attached to the margin of the glenoid cavity, giving it greater depth.

CAPSULAR.

Origin and Insertion—A loose sac attached to the anatomical neck of the humerus and to the neck of the scapula.

CORACO-HUMERAL.

Origin—Outer border of the coracoid process.

Insertion—To anterior part of the neck of the humerus.

LONG TENDON OF BICEPS.

Origin and Insertion—Lies in the bicipital groove; passes over the head of the humerus; is attached to the upper part of the glenoid cavity.

LONG HEAD OF TRICEPS.

Origin and Insertion—Passes beneath the head of the humerus, and is attached to lower part of the glenoid cavity. Both these tendons pierce the capsular ligament.

FIG. 74.—LIGAMENTS ABOUT THE ELBOW-JOINT.

1, anterior ligament; 2 and 2, anterior and posterior portions of internal lateral; 3. orbicular ligament; 4, oblique; 5, interosseous membrane.

LIGAMENTS: ELBOW-JOINT.

ANTERIOR.

Origin—Above coronoid fossa.

Insertion—Anterior surface of coronoid process.

POSTERIOR.

Origin—Above olecranon fossa.

Insertion—Upper surface of olecranon.

EXTERNAL.

Origin—External epicondyle.

Insertion—Orbicular ligament and outer surface of radius.

INTERNAL.

Origin—Internal epicondyle.

Insertion—Coronoid and olecranon processes.

Passing from the edges of these ligaments is a membranous expansion, converting them practically into a capsular ligament.

RADIO-ULNAR ARTICULATIONS.

LIGAMENTS:

ORBICULAR.

Origin and Insertion—An incomplete fibrous ring; arises from the anterior border of lesser sigmoid cavity of ulna, passes around the head of the radius, and is inserted into the posterior edge of the lesser sigmoid cavity.

OBLIQUE.

Origin—Base of coronoid process.

Insertion—Below the tuberosity of the radius.

INTEROSSEOUS.

Origin and Insertion—Membrane stretched between the radius and ulna; attached to the outer border of the ulna and inner border of radius.

ANTERIOR INFERIOR.

Origin and Insertion—Anterior margin of sigmoid cavity of radius to the head of the ulna.

POSTERIOR INFERIOR.

Origin and Insertion—Posterior margin of sigmoid cavity of radius to the head of the ulna.

TRIANGULAR FIBRO-CARTILAGE.

Origin and Insertion—Styloid process of ulna to edge of bone separating the sigmoid cavity of radius from its carpal articular surface. (This cartilage is interposed between the lower end of the ulna and the carpal bones.)

WRIST-JOINT.

LIGAMENTS:

ANTERIOR.

Origin—Inferior extremities of radius and ulna.

Insertion—Anterior surface of scaphoid, semilunar, and cuneiform. (This ligament is thick, broad, and strong.)

POSTERIOR.

Origin—Posterior border of lower end of radius.

Insertion—Posterior surface of scaphoid, semilunar, and cuneiform

EXTERNAL.

Origin—Styloid process of radius.

Insertion—Outer surface of scaphoid.

INTERNAL.

Origin—Styloid process of ulna.

Insertion—Inner side of cuneiform and pisiform bones.

ARTICULATIONS OF THE CARPUS.

1. Those of the first row.
2. Those of the second row.
3. Those of the two rows together.

Those of the First Row.

LIGAMENTS:

TWO DORSAL. Pass between the scaphoid and semilunar, and cuneiform and pisiform.

TWO PALMAR. Pass between the scaphoid and semilunar, and semilunar and cuneiform.

TWO INTEROSSEOUS. Pass between the scaphoid and semilunar, and semilunar and cuneiform.

Those of the Second Row.

LIGAMENTS:

THREE DORSAL. Pass from bone to bone of the second row.

THREE PALMAR. Pass from bone to bone of the second row.

TWO INTEROSSEOUS. Connect the os magnum with the trapezoid and unciform.

The Two Rows Together.

LIGAMENTS:

ANTERIOR. The fibres pass from the first to the second row.

POSTERIOR. The fibres pass from the first to the second row.

EXTERNAL.

Origin—Scaphoid.

Insertion—Trapezium.

INTERNAL.

Origin—Cuneiform.

Insertion—Unciform.

SYNOVIAL MEMBRANES OF THE WRIST.

The synovial membranes of the wrist are five in number,—one between the head of ulna and triangular cartilage; the second between the inferior surface of the radius and triangular cartilage and the first row of carpal bones; the third between the metacarpal bone of the thumb and trapezium; the fourth between the pisiform and cuneiform bones; the fifth, very extensive,

is placed between the carpal bones. This synovial sac forms, when the thumb is directed to the right, a double letter "D," entirely surrounding the os magnum and trapezoid.



METACARPO-CARPAL ARTICULATIONS.

LIGAMENTS:

DORSAL. Posterior surface of carpus to carpal end of metacarpus.

PALMAR. Anterior surface of carpus to carpal end of metacarpus.

INTEROSSEOUS. Short fibres between the carpus and metacarpal bases.

INTERMETACARPAL ARTICULATIONS.

LIGAMENTS:

ANTERIOR. Pass from base to base.

POSTERIOR. Pass from base to base.

INTEROSSEOUS. Pass between base and base.

METACARPO-PHALANGEAL ARTICULATIONS.

LIGAMENTS:

ANTERIOR. Strong, thick.

Origin—Head of metacarpal.

Insertion—Base of phalanx.

TWO LATERAL. Strong, thick.

Origin—Tubercle at side of metacarpal.

Insertion—Side of base of phalanx.

PHALANGEAL ARTICULATIONS.

LIGAMENTS: Anterior and two lateral, arranged as in the metacarpo-phalangeal articulation.

HIP-JOINT.

LIGAMENTS:

COTYLOID. Fibro-cartilaginous. Attached to the rim

of acetabular cavity, which it deepens; it fits closely about the head of the femur.

TRANSVERSE. A band of strong fibres which passes across the cotyloid notch.

TERES. A conoidal mass of fibres arising from the depression at the floor of the cotyloid cavity and inserted into the head of the femur.

CAPSULAR. Attached to the neck, oftener to the

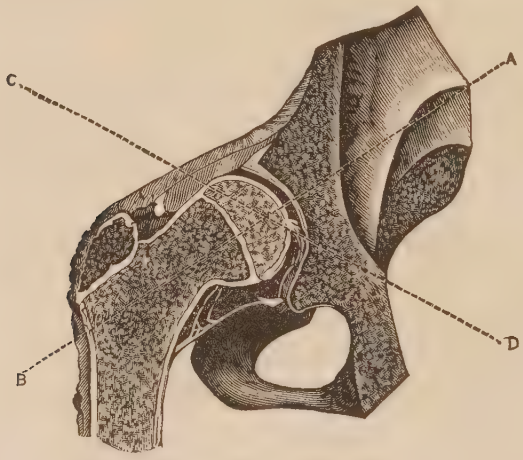

FIG. 75.—VERTICAL SECTION THROUGH HIP-JOINT.

A to B indicates the direction in which the extension here described is made, and C to D the direction in which the head of the femur is carried by extension in a line with the body.

trochanters and intertrochanteric lines, inserted external to the cotyloid ligament.

ILIO-FEMORAL, or Y-SHAPED.

Origin—Anterior inferior spine of ilium.

Insertion—Anterior intertrochanteric line.

KNEE-JOINT.

The knee-joint has internal and external ligaments.

EXTERNAL:

ANTERIOR, or LIGAMENTUM PATELLA.

Origin—Tendon of quadriceps extensor femoris.

Insertion—Tuberosity of tibia.

POSTERIOR, or LIGAMENTUM POSTICUM WINSLOWII.

Origin—Osseous points above and below the articular cartilage, and intimately associated with the tendon of the semimembranous muscle.

INTERNAL LATERAL.

Origin—Inner tuberosity of femur (or inner epicondyle).

Insertion—Inner side of head of tibia.

TWO EXTERNAL LATERAL.

Origin—The long: Outer epicondyle.

Insertion—Head of fibula.

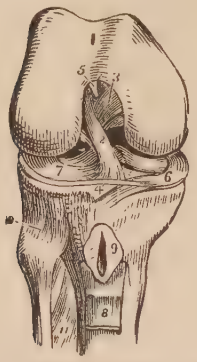

FIG. 76.—KNEE-JOINT LIGAMENTS.

2, anterior crucial ligament; 3, posterior crucial ligament; 4, transverse ligament; 6, 7, internal and external semilunar cartilages; 8, ligamenta patellæ; 9, bursa patellæ; 10, anterior superior tibio-fibular ligament.

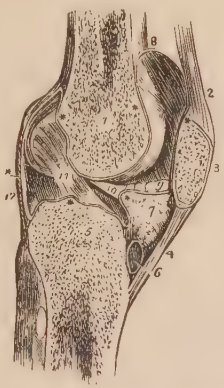

FIG. 77.—KNEE-JOINT LIGAMENTS.

2, quadriceps extensor; 3, patella, 4, ligamentum patellæ; 6, bursa; 7, 8, 9, synovial membrane of knee-joint; 10, anterior crucial ligament.

Origin—The short: Posterior part of outer condyle.

Insertion—Styloid process of fibula.

CAPSULAR. Membranous; continuous with the borders of the other external ligaments.

INTERNAL:

EXTERNAL, or ANTERIOR CRUCIAL.

Origin—Spine of tibia.

Insertion—Inner side of outer condyle of femur.

INTERNAL, or POSTERIOR CRUCIAL.

Origin—Spine of tibia.

Insertion—Outer side of inner condyle.

TWO SEMILUNAR CARTILAGES. Flat below, have concavities above for condyles, attached to crucial and coronary ligaments and head of tibia.

CORONARY. Serves to attach the semilunar cartilages to tibia.

TRANSVERSE. Passes across anteriorly from the inner to the outer semilunar cartilage.

LIGAMENTUM MUCOSUM. A triangular prolongation of synovial membrane behind the patella.

LIGAMENTA ALARIA. The lateral borders of ligamentum mucosum; attached to the patella.

TIBIO-FIBULAR ARTICULATIONS.

ABOVE:

ANTERIOR. Head of tibia to head of fibula.

POSTERIOR. Head of tibia to head of fibula.

INTEROSSEOUS. Extends between the tibia and fibula for the entire length. Is perforated above for the anterior tibial artery.

BELOW:

INFERIOR INTEROSSEOUS. Fibres passing between the tibia and fibula.

TRANSVERSE. From external malleolus; attached above internal malleolus.

ANTERIOR. Between the tibia and fibula anteriorly.

POSTERIOR. Between the tibia and fibula posteriorly.

ANKLE-JOINT.

LIGAMENTS:

ANTERIOR.

Origin—Anterior inferior surface of tibia.

Insertion—Neck of astragalus.

EXTERNAL LATERAL (3 bundles).

Origin—External malleolus.

Insertion—1. Outer side of astragalus. 2. Outer side of os calcis. 3. Posterior part of astragalus.

INTERNAL LATERAL, or DELTOID.

Origin—Inner malleolus.

Insertion—Scaphoid, os calcis, and astragalus.

TARSAL ARTICULATIONS.

1. Between proximal row.
2. Between distal row.
3. Between the two rows.

Between the Proximal Row, or Astragalus and Os Calcis.

LIGAMENTS:

EXTERNAL CALCANEO-ASTRAGALOID.

Origin—Outer side of calcaneum.

Insertion—Outer side of astragalus.

INTERNAL CALCANEO-ASTRAGALOID.

Origin—Upper surface of calcaneum.

Insertion—Posterior side of astragalus.

INTEROSSEOUS. Attached to the groove on os calcis and astragalus.

Between the Distal Row, constituting the Scaphoid, Cuboid, and Three Cuneiform.

LIGAMENTS:

DORSAL. Pass from bone to bone.

PLANTAR. Pass from bone to bone.

FOUR INTEROSSEOUS. Pass between the adjoining bones.

Between the Two Rows.

1. Between the os calcis and cuboid.

LIGAMENTS:

DORSAL, SUPERFICIAL CALCANEO-CUBOID. Passes from os calcis to cuboid.

DORSAL, INTER-CALCANEO-CUBOID. Passes from os calcis to cuboid.

PLANTAR, LONG CALCANEO-CUBOID.

Origin—In front of tubercles of os calcis.

Insertion—Ridge on cuboid and second, third, and fourth metatarsal.

PLANTAR, SHORT CALCANEO-CUBOID.

Origin—Very deep, inferior surface of os calcis, anterior to tubercles.

Insertion—Inferior surface of cuboid.

2. Between the os calcis and scaphoid.

LIGAMENTS:

SUPERIOR.

Origin—Inner side of os calcis.

Insertion—Outer side of scaphoid.

INFERIOR (broad and thick).

Origin—Anterior inferior side of os calcis.

Insertion—Inner surface of scaphoid.

3. Between the astragalus and scaphoid.

LIGAMENTS:

CAPSULAR.

Origin—Neck of astragalus.

Insertion—Margin of articular surface of scaphoid.

TARSO-METATARSAL ARTICULATIONS.

LIGAMENTS:

DORSAL. Pass from the tarsal to the metatarsal bones.

PLANTAR. Pass from the tarsal to the metatarsal bones.

THREE INTEROSSEOUS. Pass between the tarsal and metatarsal bones.

TARSAL SYNOVIAL MEMBRANES.

There are six distinct synovial sacs in the tarsal articulations,—three posteriorly and three anteriorly. The posterior sacs are located as follows: The first between the astragalus and os calcis, behind the interosseous ligament; the second between the astragalus and os calcis, anterior to the interosseous ligament, and passing upward and inward between the astragalus and scaphoid; the

third between the os calcis and cuboid. The anterior sacs are: The fourth, between the cuboid and fourth and fifth metatarsal; the fifth, between the scaphoid and three cuneiform; it extends forward between the middle and external cuneiform, and expands so as to lie between the middle and external cuneiform bones and the second and third metatarsal; the sixth, the smallest, between the internal cuneiform and first metatarsal.

INTERMETATARSAL ARTICULATIONS.

LIGAMENTS:

DORSAL. Pass across the bases of the metatarsal bones.

PLANTAR. Pass across the bases of the metatarsal bones.

INTEROSSEOUS. Pass between the bases of the metatarsal bones.

METATARSO-PHALANGEAL ARTICULATIONS.

LIGAMENTS:

PLANTAR. From the base of phalanx to the head of metatarsal bone.

TWO LATERAL. From the base of phalanx to the head of metatarsal bone, laterally.

PHALANGEAL ARTICULATIONS.

The phalangeal articulations are like the metatarso-phalangeal.

A freely-movable joint is always provided with a capsular ligament. Those joints having an interarticular cartilage generally have two synovial sacs, except in the vertebral articulations and in the knee-joints.

When the synovial sacs and capsular ligaments are greatly distended, the joints are flexed and fixed, simulating a dislocation, thus: the elbow-joint is flexed at right angles; in distension of the hip-joint the thigh is adducted and strongly flexed.

MUSCULAR SYSTEM.

MUSCLES.

MUSCLES are structures attached to movable parts. They are endowed with the property of contractility; that is, when thrown into action they shorten in the direction of their fibres and draw together the parts to which they are attached. This power of contraction is due to the irritability of the muscle, and is exercised within certain limitations as often as the muscle is stimulated to act either normally through nerve impression or through some exterior physical agency, as a blow. Muscles are of two kinds, voluntary and involuntary. The voluntary muscles are transversely striped and are called striated. The involuntary have no transverse markings. They are both made up of bundles of fibres. The voluntary or striated muscles act under the influence of the will; they are composed of a number of delicate prismoidal bundles, which run in the same direction. These bundles are held together by the fibrous sheath of the muscle or external perimysium; each bundle is separately invested by the internal perimysium. A bundle is made up of fibres, and each fibre invested by an exceedingly delicate sheath of connective tissue,—the endomysium or sarcolemma. The fibres run for about an inch, are about $\frac{1}{300}$ inch in thickness, are flattened by mutual pressure, and terminate either in a tendon or another fibre continued in the same direction; they do not branch or inosculate except in the heart. Each fibre is composed of extremely delicate fibrillæ, $\frac{1}{20000}$ inch in thickness, divided into a series of segments $\frac{1}{10000}$ inch

long, and may be likened to a string of beads, each bead $\frac{1}{20000}$ inch thick and $\frac{1}{10000}$ inch long; a great number

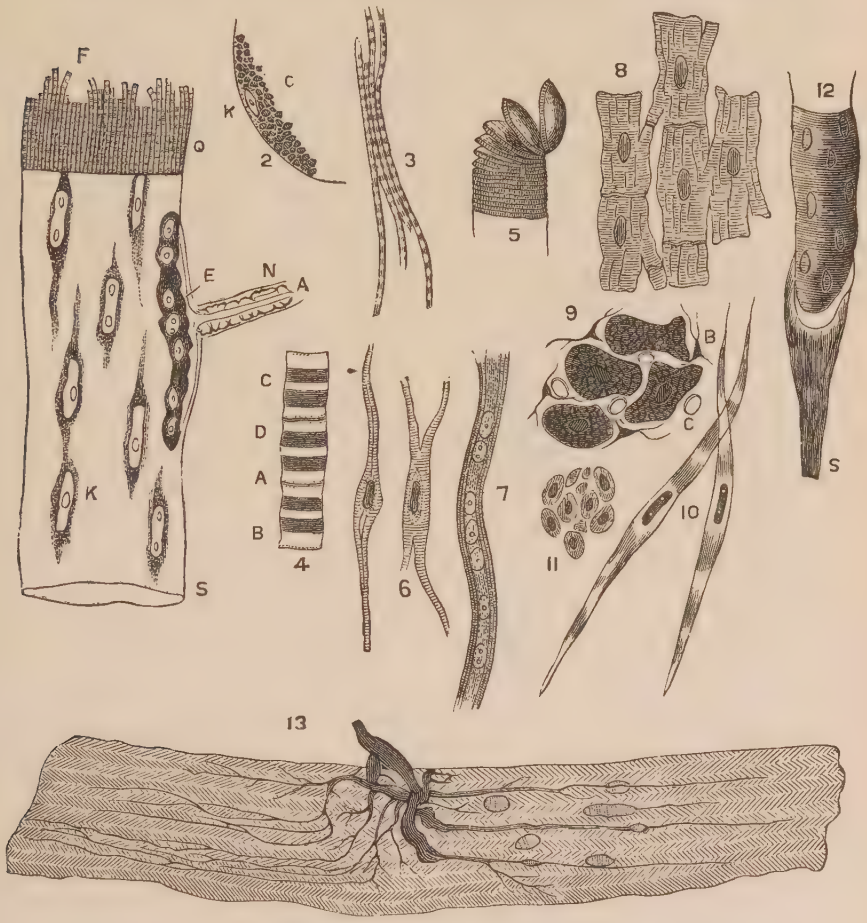

FIG. 78.—MUSCULAR TISSUE.

1, scheme of the different parts of striped muscular fibre; S, sarcolemma; K, nucleus; 2, striation; F, fibrillæ; N, nerve; E, nucleated nerve-plate; 2, part of a cross-section; 3, isolated fibrillæ; 4, highly magnified fibril of insect muscle; A, Krause-Amici's line; B, anisotropic substance; C, central disk; D, isotropic substance; 5, separation of disks; 6, cell of heart-muscle of frog; 7, embryonal development of muscular fibre; 8, cells of heart-muscle; 9, cross-section of heart-muscle; 10, unstriped muscle-cells; 11, cross-section of unstriped muscle-cells; 12, muscular fibre with tendon; 13, interfibrillar muscular nerves.

of such fibrillæ make up a fibre which necessarily exhibits the transverse striæ due to the division of the fibril into the separate segments or beads. A single segment of

the fibril is called a muscle-bead or sarcous element; it is composed of a cell of protoplasm (in the form of a brick having rectangular sides), and devoid of cell-wall or nucleus. A series of such beads end to end constitute the fibril; a bundle of such fibrillæ (a fibre) will exhibit at their points of segmentation the transverse markings or lines or stripes already described. If the fibre be torn across a plate of beads, or sarcous elements or segments which adhere to one another by their sides may be detached, such a plate is called a disk of Bowman, which may be defined as being a single plane of sarcous elements adherent to one another by their sides. If the fibre is viewed entire and with moderate powers, it is observed to present a wavy outline, the convexity being between the lines of segmentation or striation, and which striæ are called the lines of Dobie. Across the convexity of the fibre a clear stripe is seen described accurately by Hensen.

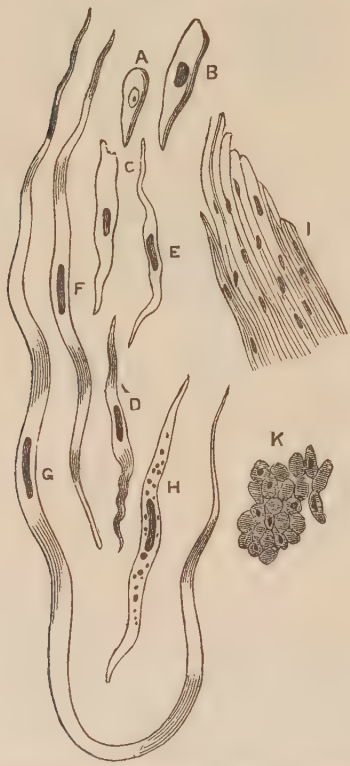

FIG. 79.—UNSTRIPED MUSCULAR TISSUE.

A and B, fœtal cells; C, H, fully formed fibre; I, bundle of fibres; K, cross-section of bundle of pale muscular fibres.

The involuntary muscle consists of nucleated fusiform and spindle-shaped cells arranged in bundles, held together by the perimysium. Each cell is about $\frac{1}{4000}$

inch thick and $\frac{1}{400}$ inch in length. Its nucleus is rod-shaped and placed about the centre of the cell, which is delicately striated longitudinally, and which striations are the fibrillæ. The involuntary muscle is not controlled by the will; it is found in the walls of the hollow viscera, in many ducts and vessels. The muscle of the heart consists of voluntary or striped muscular fibres which branch and interlace. They have but little investing connective tissue,—so little that the existence of even the sarcolemma has been denied. In addition, each fibre has a distinct nucleus. The heart-muscle may be regarded as a blending of the voluntary with the involuntary muscular fibre.

There are about two hundred and fifty pairs of muscles arranged symmetrically and six or seven single muscles in the human body. They are named according to location, as the subclavius and peroneal; or, according to direction, as the recti; or, according to shape, as the trapezius; or, according to attachments, as the sterno-mastoid; or, according to function, as the abductors and flexors.

The origin of a muscle is the fixed point from which it acts, and in the extremities is generally the point of attachment nearest the trunk. Muscles are inserted directly without the intervention of tendons, as in the case of facial muscles; or by tendons and aponeuroses. Tendons are cords of white, fibrous tissue; generally small at their point of attachment; often rounded; sometimes flattened. Aponeuroses are thin planes of white, fibrous tissue, by which certain muscles are attached.

The fasciæ are laminæ of white, fibrous tissue; differently arranged in different parts of the body. The superficial fascia immediately beneath the skin consists

of a loose, net-like arrangement of white, fibrous tissue, presenting many interstices or alveoli, generally filled with fat. The deep fascia, beneath the superficial, consists of a white, dense, aponeurotic arrangement of white, fibrous tissue, free from fat and found investing the muscles of the body.

Connective tissue is the disposition of the fibres of the white fibrous tissue between the different soft structures of the body. Muscles are generally arranged in symmetrical pairs.

MUSCLES OF THE HEAD.

OCCIPITO-FRONTALIS.

Origin—Superior curved line on occipital bone and mastoid portion of temporal bone.

Insertion—It becomes aponeurotic and passes forward over the cranium, and is inserted by a fleshy belly into the soft structures above the orbit.

Nerves—Posterior portion by the small occipital and facial and anterior portion by facial.

ORBICULARIS PALPEBRARUM.

Origin—Internal angular process of frontal, nasal process of superior maxillary and upper edge of tendo oculi.

Insertion—It is a plane of fibres which surround the orbit elliptically, and is inserted into the inferior edge of the tendo oculi and nasal process of superior maxillary.

Nerve—Facial.

CORRUGATOR SUPERCILII.

Origin—Superciliary ridge near the frontal suture.

Insertion—Passes outward, and is inserted in the under surface of the orbicularis palpebrarum and occipito-frontalis.

Nerve—Facial.

LEVATOR PALPEBRÆ SUPERIORIS.

Origin—Inferior surface of lesser wing of sphenoid, in front of the optic foramen.

Insertion—Passes forward and becomes broad and aponeurotic, and is inserted into the upper border of the tarsal cartilage.

Nerve—Motor oculi, or third.

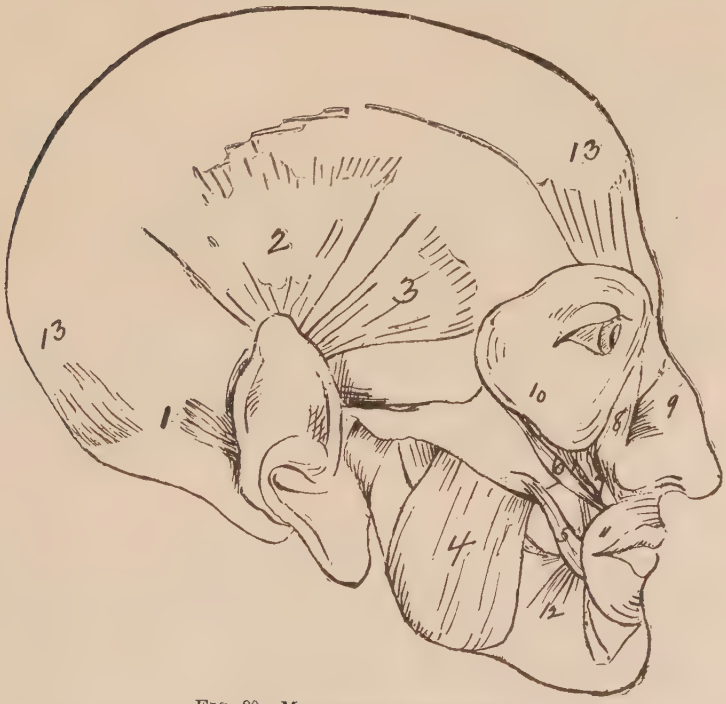

FIG. 80.—MUSCLES OF THE HEAD.

1, retrahens aurem; 2, attollens aurem; 3, attrahens aurem; 4, masseter; 5, zygomaticus major; 6, zygomaticus minor; 7, levator labii superioris; 8, levator labii superioris alæque nasi; 13, occipito-frontalis; 9, compressor nasi; 10, orbicularis palpebrarum; 11, orbicularis oris; 12, depressor anguli oris.

TENSOR TARSI.

Origin—Ridge of lachrymal bone; it is a very thin, short muscle.

Insertion—Tarsal cartilages.

Nerve—Facial.

ATTOLLENS AUREM.

Origin—Rudimentary. Aponeurosis of occipito-frontalis.

Insertion—Upper part of pinna.

Nerve—Small occipital.

ATTRAHENS AUREM.

Origin—Rudimentary. Aponeurosis of occipito-frontalis.

Insertion—Into the helix.

Nerve—Facial.

RETRAHENS AUREM.

Origin—Rudimentary. Mastoid portion of temporal.

Insertion—Posterior part of concha.

Nerve—Posterior auricular branch of facial.

MUSCLES OF THE ORBIT.

SUPERIOR RECTUS.

Origin—Arises just above the optic foramen.

Insertion—Passes forward and becomes aponeurotic, and is inserted into the upper part of sclerotic.

Nerve—Third.

INFERIOR RECTUS.

Origin—Just below the optic foramen.

Insertion—Passes forward and becomes aponeurotic, and is inserted into the lower surface of the sclerotic.

Nerve—Third.

EXTERNAL RECTUS.

Origin—By two heads: first, from outer and lower edge of optic foramen; second, lesser wing above optic foramen.

Insertion—Passes forward and becomes aponeurotic, and is inserted into the outer side of the sclerotic.

Nerve—Sixth.

INTERNAL RECTUS.

Origin—Inner edge of optic foramen.

Insertion—Passes forward and becomes aponeurotic, and is inserted into the inner side of the sclerotic.

Nerve—Third.

SUPERIOR OBLIQUE.

Origin—Above the inner margin of optic foramen.

Insertion—Passes forward and inward; becomes tendinous. The tendon passes through a pulley at upper,

FIG. 81.—MUSCLES OF THE ORBIT.
1, levator palpebræ superioris; 2, superior oblique; 3, superior rectus; 4, external rectus; 5, inferior rectus.

inner, anterior part of orbit; becomes muscular again and passes outward and backward, and is inserted into the upper part of the sclerotic, beneath the superior rectus.

Nerve—Fourth.

INFERIOR OBLIQUE.

Origin—Anterior and inner part of the orbital plate of superior maxillary.

Insertion—Passes outward and slightly backward beneath inferior rectus, and is inserted into outer portion of sclerotic, between inferior and external recti.

Nerve—Third.

PYRAMIDALIS NASI.

Origin—Continuation downward of inner fibres of occipito-frontalis.

Insertion—Compressor nasi.

Nerve—Facial.

COMPRESSOR NASI.

Origin—Incisive fossa of superior maxillary.

Insertion—Blends with its fellow on the bridge of nose.

Nerve—Facial.

LEVATOR LABII SUPERIORIS ALÆQUE NASI.

Origin—Nasal process of superior maxillary.

Insertion—By two slips: one into the wing of nose, the other into the upper lip.

Nerve—Facial.

DILATOR NARIS POSTERIOR.

Origin—Cartilage of wing of nose.

Insertion—Skin at free margin of nostril.

Nerve—Facial.

DILATOR NARIS ANTERIOR.

Origin—Cartilage of wing of nose.

Insertion—Skin at free margin of nostril.

Nerve—Facial.

DEPRESSOR ALÆ NASI.

Origin—Incisive fossa of superior maxillary.

Insertion—Wing of nose.

Nerve—Facial.

COMPRESSOR NARIUM MINOR.

Origin—Cartilage of wing of nose.

Insertion—Skin at free margin of nostril.

Nerve—Facial.

ZYGOMATICUS MAJOR.

Origin—Malar bone.

Insertion—Angle of mouth.

Nerve—Facial.

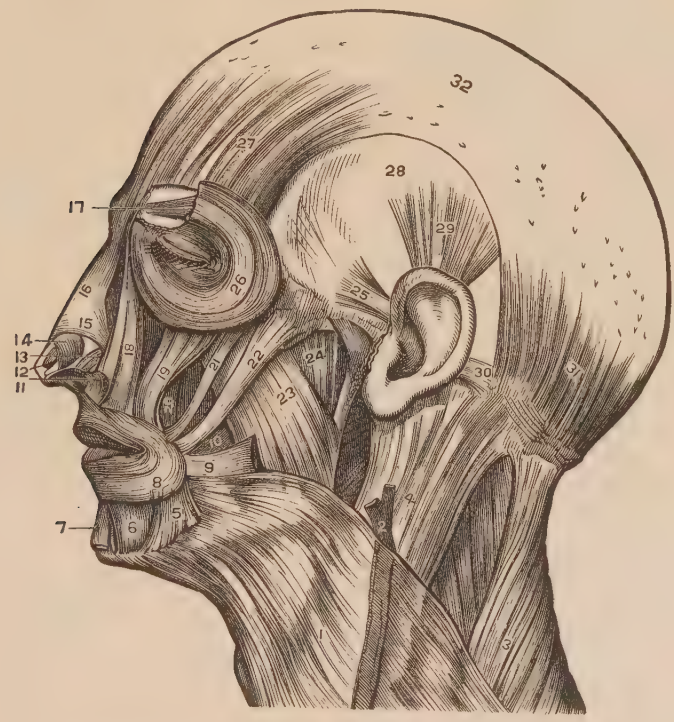

FIG. 82.—MUSCLES OF FACE.

1, platysma myoides; 2, external jugular vein; 3, trapezius; 4, sterno-cleido-mastoid; 5, depressor anguli oris; 6, depressor labii inferioris; 7, levator menti; 8, orbicularis oris; 9, risorius; 10, buccinator; 11, depressor alæ nasi; 12, compressor narium minor; 13, dilator naris posterior; 14, dilator naris anterior; 15, compressor naris; 16, pyramidalis nasi; 17, corrugator supercilii; 18, levator labii superioris alæque nasi; 19, levator labii superioris; 20, levator anguli oris; 21, zygomatic minor; 22, zygomatic major; 23, masseter—superficial portion; 24, masseter—deep portion; 25, attrahens aurem; 26, orbicularis palpebrarum; 27, frontal portion of occipito-frontalis; 28, temporal fascia; 29, attollens aurem; 30, retrahens aurem; 31, occipital portion of occipito-frontalis; 32, tendinous aponeurosis of occipito-frontalis.

ZYGOMATICUS MINOR.

Origin—Malar bone in front of the zygomaticus major.

Insertion—Angle of mouth.

Nerve—Facial.

LEVATOR LABII SUPERIORIS.

Origin—Inferior margin of orbit.

Insertion—Upper lip.

Nerve—Facial.

LEVATOR ANGULI ORIS.

Origin—Canine fossa.

Insertion—Angle of mouth.

Nerve—Facial.

QUADRATUS MENTI.

Origin—External oblique line of inferior maxillary, internal to mental foramen.

Insertion—Lower lip. It is a depressor of lip.

Nerve—Facial.

TRIANGULARIS MENTI.

Origin—External oblique line external to quadratus menti.

Insertion—Angle of mouth. It is a depressor of lip.

Nerve—Facial.

LEVATOR MENTI.

Origin—At each side of septum, incisive fossa below alveolar process.

Insertion—Skin at lower part of chin.

Nerve—Facial.

ORBICULARIS ORIS.

Origin—Sphincter of the mouth. Consists of two thick semi-elliptical planes of muscular fibres, which surround the mouth.

Insertion—A few fibres are attached to the superior maxillary and two conical fasciculi, pass upward to the sides to the anterior nasal spine, and are inserted into the upper lip. The depression between these bundles is immediately below the septum nasi.

Nerve—Facial.

BUCCINATOR.

Origin—Anterior edge of pterygo-maxillary ligament; also, from the alveolar process above and below the molar teeth.

Insertion—Is a bipenniform muscle. The fibres pass forward and are continuous with those of the orbicularis oris.

Nerves—Facial and inferior maxillary.

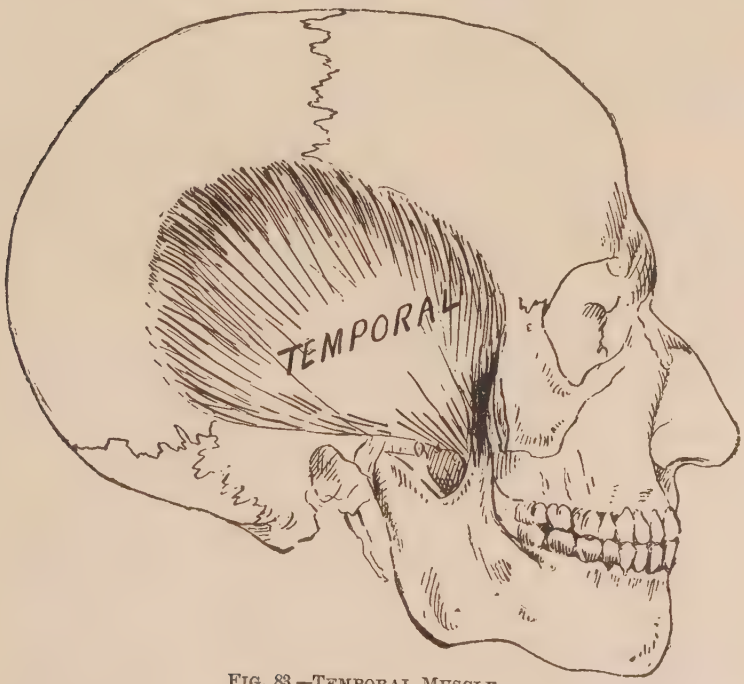

FIG. 83.—TEMPORAL MUSCLE.

RISORIUS.

Origin—Fascia over masseter muscle.

Insertion—Angle of mouth.

Nerve—Facial.

MASSETER.

Origin—Two portions, superficial and deep. Superficial, from inferior border of malar and inferior

border of anterior portion of zygoma; deep portion, from inferior border of zygoma.

Insertion—Angle and external surface of the ramus of the inferior maxillary.

Nerve—Inferior maxillary.

TEMPORAL.

Origin—Temporal fossa.

Insertion—Superior and anterior portion of coronoid process of inferior maxillary.

Nerve—Inferior maxillary nerve.

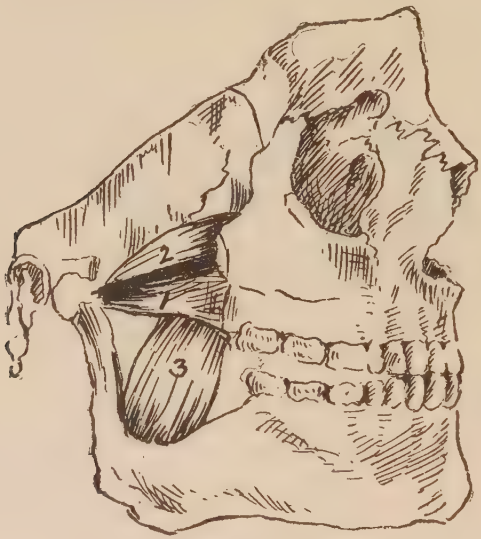

FIG. 84.—PTERYGOID MUSCLES.
1, lower head of external pterygoid; 2, upper head of external pterygoid; 3, internal pterygoid.

INTERNAL PTERYGOID.

Origin—Pterygoid fossa.

Insertion—Inner side of angle of inferior maxillary.

Nerve—Inferior maxillary.

EXTERNAL PTERYGOID.

Origin—Two heads: first, pterygoid ridge and bone below on great wing of sphenoid; second, outer surface of external pterygoid plate.

Insertion—Neck of inferior maxillary, below the condyle.

Nerve—Inferior maxillary.

MUSCLES OF THE NECK.

Platysma Myoides.

Origin—A superficial plane of muscular fibres passing obliquely up the neck from the clavicle between the layers of the superficial fascia.

Insertion—Into the inferior maxillary and fascia of face.

Nerves—Facial and superficial branch of cervical plexus.

Sterno-claviculo-mastoid.

Origin—Two heads, one a round tendon from the sternum. The clavicular origin is fleshy and about one and one-half inches broad.

Insertion—It passes upward and backward, divides the side of the neck into two great triangles, and is inserted on the mastoid portion of the temporal and the occipital bones.

Nerves—Spinal accessory and branches from cervical plexus.

Sterno-hyoid.

Origin—Posterior surface of manubrium and inner end of clavicle.

Insertion—Inferior border of anterior part of os hyoides.

Nerve—Descendens noni.

Sterno-thyroid.

Origin—Posterior surface of manubrium.

Insertion—Oblique line on thyroid cartilage.

Nerve—Descendens noni.

Thyro-hyoid.

Origin—Oblique line at side of thyroid cartilage.

Insertion—Body and greater cornu of hyoid bone.

Nerve—Hypoglossal.

OMO-HYOID.

Origin—From the hyoid bone to scapula. Body of hyoid bone. Is a bibellied muscle (having a central tendon).

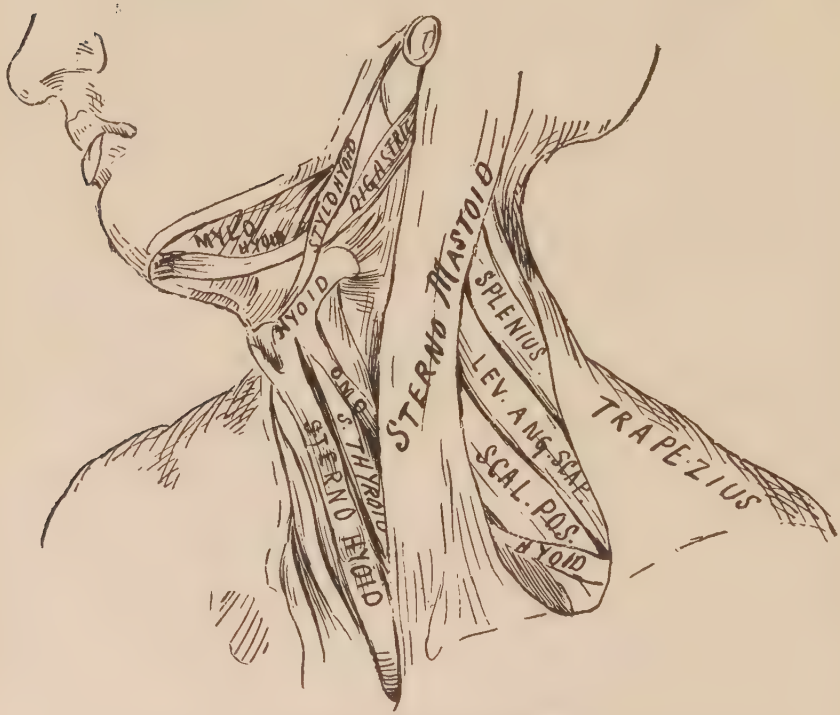

FIG. 85.—MUSCLES OF NECK.

Insertion—Passes downward, sends its tendon through a loop of deep cervical fascia attached to the first rib, then passes across to the transverse ligament of the scapula, to which the fibres are attached.

Nerve—Descendens noni.

DIGASTRIC.

Origin—Also a bibellied muscle. Digastric fossa of the mastoid portion of the temporal. Its tendon

passes through the stylo-hyoid muscle, by which it is held against the hyoid bone.

Insertion—Is inserted into the digastric depression of the posterior surface of the symphysis menti.

Nerves—Inferior maxillary and facial.

STYLO-HYOID.

Origin—Styloid process.

Insertion—At junction of body and greater cornu of hyoid.

Nerve—Facial.

GENIO-HYOID.

Origin—Inferior genial tubercle.

Insertion—Central part of body of hyoid.

Nerve—Hypoglossal.

MYLO-HYOID.

Origin—Mylo-hyoid ridge for its entire length.

Insertion—Body of os hyoides and central raphe.

Nerve—Inferior dental.

GENIO-HYOGLOSSUS.

Origin—Superior genial tubercle; body of hyoid near the centre; it spreads out fan-like.

Insertion—Inserted into the under surface of tongue, from tip to base.

Nerve—Hypoglossal.

HYOGLOSSUS.

Origin—Side of body, lesser cornu, and full length of greater cornu of hyoid bone.

Insertion—Inserted into the under surface of the side of the tongue.

Nerve—Hypoglossal.

LINGUALIS.

Origin and Insertion—Runs along under surface of tongue from base to tip; lies between the hyoglossus

and genio-hyoglossus. It is a bundle of muscular fibres about as thick as a lead-pencil.

Nerve—Chorda tympani.

STYLOGLOSSUS.

Origin—Styloid process and stylo-maxillary ligament.

Insertion—Side of tongue into hyoglossus and lingualis.

Nerve—Hypoglossal.

PALATOGLOSSUS.

Origin—Forms anterior pillar of fauces, from soft palate on each side of uvula.

Insertion—Arches outward and forward, and is inserted into the side of tongue.

Nerve—Meckel's ganglion.

LEVATOR PALATI.

Origin—Quadrilateral rough surface of petrous portion of temporal bone.

Insertion—Passes obliquely downward and inward, and is inserted into the soft palate.

Nerve—Vidian, from facial.

TENSOR PALATI.

Origin—Scaphoid fossa and Eustachian tube. Its central tendon winds around the hamular process.

Insertion—It then passes inward at right angles, becomes fleshy, and is inserted by a broad aponeurosis into the soft palate.

Nerve—From otic ganglion.

AZYGOS UVULÆ.

Origin—Two fasciculi pendent from the posterior nasal spine.

Insertion—Soft palate.

Nerve—Vidian, from facial.

PALATO-PHARYNGEUS.

Origin—Forms posterior pillar of fauces; arises from soft palate.

Insertion—Arches downward, outward, and backward; inserted into sides of pharynx and thyroid cartilage.
Nerve—Meckel's ganglion.

FIG. 86.—CONSTRICTOR MUSCLES OF PHARYNX.
1, orbicularis oris; 2, buccinator; 3, superior constrictor; 4, middle constrictor; 5, inferior constrictor; 6, mylo-hyoid; 7, hyoglossus.

SUPERIOR CONSTRICTOR.

Origin—Internal pterygoid plate, hamular process, tendon of tensor palati, posterior edge of pterygo-maxillary ligament and mylo-hyoid ridge.

Insertion—The fibres pass backward, upward, and inward; they meet those of the opposite muscle behind the pharynx, and are inserted into the tendinous raphe of the pharynx, which is at-attached to the pharyngeal spine of basilar process of occipital.

Nerve—Glosso-pharyngeal.

MIDDLE CONSTRICTOR.

Origin—Greater and lesser cornu of hyoid bone and stylo-hyoid ligament.

Insertion—Passes outward and backward and meets the muscle of opposite side, and is inserted into the tendinous vertical raphe.

Nerve—Glosso-pharyngeal.

INFERIOR CONSTRICTOR.

Origin—Side of thyroid and cricoid cartilages.

Insertion—Passes outward and backward and meets fibres of opposite muscle, and is inserted into the tendinous vertical raphe.

Nerves—Glosso-pharyngeal and external laryngeal.

STYLO-PHARYNGEUS.

Origin—Styloid process.

Insertion—Sides of pharynx between superior and middle constrictors.

Nerve—Glosso-pharyngeal.

RECTUS CAPITIS ANTICUS MAJOR.

Origin—Anterior tubercles of transverse processes of third, fourth, fifth, and sixth cervical vertebræ.

Insertion—Basilar process of occipital.

Nerve—Suboccipital.

RECTUS CAPITIS ANTICUS MINOR.

Origin—Lateral mass of atlas.

Insertion—Basilar process.

Nerve—Suboccipital.

RECTUS LATERALIS.

Origin—Transverse process of atlas.

Insertion—Jugular process of occipital.

Nerve—Suboccipital.

LONGUS COLLI.

Origin—Three portions: (1) superior oblique, from anterior tubercles of transverse processes of third, fourth, and fifth cervical vertebræ; (2) inferior oblique, from anterior tubercles of transverse processes of fifth and sixth cervical vertebræ; (3) vertical portion, from bodies of upper three dorsal vertebræ and lower two or three cervical.

Insertion—Superior oblique portion passes upward and is inserted into anterior tubercle of atlas. Inferior oblique portion passes downward, and is inserted into the bodies of first and second dorsal vertebræ. Vertical portion, into the bodies of the second, third, and fourth cervical.

Nerves—Cervical and brachial plexuses.

SCALENUS ANTICUS.

Origin—Anterior tubercle of the transverse process of the third, fourth, fifth, and sixth cervical vertebræ.

Insertion—Passes downward and outward, and is inserted on the tubercle on the first rib, between the grooves for the subclavian vein and artery.

Nerve—Cervical plexus.

SCALENUS MEDIUS.

Origin—Posterior tubercles of transverse process of all the cervical vertebræ except the atlas.

Insertion—On first rib, behind groove for subclavian artery.

Nerves—Cervical and brachial plexuses.

SCALENUS POSTICUS.

Origin—Posterior tubercles of sixth and seventh cervical vertebræ.

Insertion—Posterior part of second rib.

Nerve—Brachial plexus.

MUSCLES OF THE THORAX.

ELEVEN EXTERNAL INTERCOSTALS.

Origin—Inferior border of rib, above.

Insertion—Superior border of rib, below.

Nerves—Intercostals.

ELEVEN INTERNAL INTERCOSTALS.

Origin—Inferior border of rib, above.

Insertion—Superior border of rib, below.

Nerves—Intercostals.

The external intercostals pass downward and forward, and extend from tubercle of the ribs to costal cartilages.

The internal intercostals pass upward and inward, and begin anteriorly at the sternum and extend backward to the angle of ribs.

TWELVE LEVATORES COSTARUM.

Origin—Apices of transverse processes of dorsal vertebræ.

Insertion—Pass downward and outward, and are inserted posterior to angles of ribs.

Nerve—Intercostals.

INFRACOSTALES.

Origin—Fibres arise from inner surface of rib.

Insertion—Into ribs below.

Nerve—Intercostal.

TRIANGULARIS STERNI.

Origin—Lower part of inner surface of sternum and costal cartilages.

Insertion—Costal cartilages of third, fourth, and fifth ribs.

Nerve—Intercostal.

DIAPHRAGM.

The diaphragm is a fibro-muscular partition be-

tween the thoracic and abdominal cavities. It arises posteriorly by two crura, which are flat, ligamentous bands attached to the anterior surface of the bodies of the lower four lumbar vertebræ; also, it arises from the ligamenta arcuata interna and externa, which are fibrous arches thrown over the psoas magnus and quadratus lumborum muscles, the ligamentum arcuatum internum being attached to the side of the body of the first lumbar vertebra and attached to the base of the transverse process

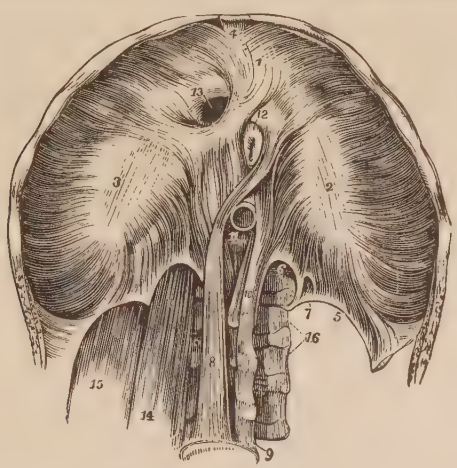

FIG. 87.—THE DIAPHRAGM.

1, 2, 3, central cordiform tendon; 4, middle leaflet; 5, ligamentum arcuatum externum; 6, ligamentum arcuatum internum; 8, right crus; 10, left crus; 11, aortic opening; 12, œsophageal opening; 13, opening for vena cava; 14, psoas magnus; 15, quadratus lumborum.

of the second lumbar vertebra; it is continuous with the crus. The ligamentum arcuatum externum extends from the base of transverse process of second lumbar vertebra to the apex of the last rib. The diaphragm also arises by a number of digitations from the inferior circumference of the chest; therefore, from the tip of the eleventh rib, the costal cartilages of the false ribs, and the tip of the ensiform cartilage. From these points of origin the fibres pass inward to the central tendon, which consists of a trefoil aponeurosis of white, fibrous tissue.

There are three important openings in the diaphragm: 1. The aortic, bounded posteriorly by the bodies of the vertebræ, latterly and anteriorly by the crura, which are continuous along their inner borders, forming a fibrous margin or arch, beneath which passes the aorta. 2. The œsophageal opening, in front of the aortic, is elliptical in form; it is made by the decussation of the planes of muscular fibres attached to the crura; the muscular fibres from the right crus pass to the left; those from the left crus pass to the right, and two inches in front of this again decussate, making an elliptical opening for the passage of the œsophagus and pneumogastric nerves. This arrangement of decussating fibres makes a sphincter for the lower end of the œsophagus, or cardiac end of stomach. 3. To the right of the œsophageal opening, in the right leaflet of the central tendon, is the quadrate opening for the passage of the ascending vena cava. It is so constructed that traction on the tendon of the diaphragm will enlarge it. The opposite is true of the œsophageal opening. The diaphragm is supplied by the two phrenic nerves from the cervical and brachial plexuses, arches well into the chest, but approximates a plane when in a state of marked contraction.

MUSCLES OF THE BACK.

The muscles of the back are disposed in five layers.

Muscles of the First Layer.

TRAPEZIUS.

Origin—Ligamentum nuchæ, superior curved line of occipital bone, spine of seventh cervical vertebra, spines of all dorsal vertebræ.

Insertion—Into upper border of spine of scapula, outer one-third of posterior border of clavicle.

Nerve—Spinal accessory.

LATISSIMUS DORSI.

Origin—Spines of six lower dorsal vertebræ, spines of all the lumbar vertebræ, spines of all the sacral vertebræ.

Insertion—Passes upward and outward, and is inserted

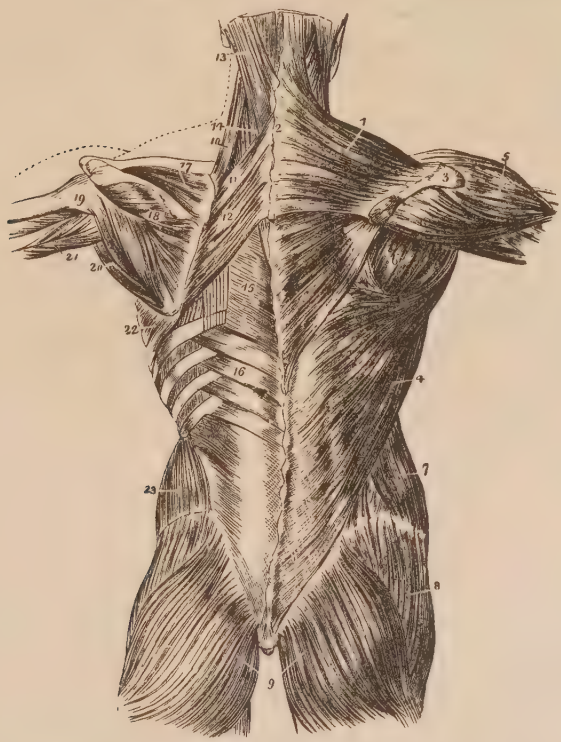

FIG. 88.—MUSCLES OF THE BACK.

1 and 2, trapezius; 3, spine of scapula; 4, latissimus dorsi; 5, deltoid; 6, infra-spinatus; 7, external oblique; 8 and 9, gluteal muscles; 10, levator anguli scapulæ; 11, rhomboideus minor; 12, rhomboideus major; 13 and 14, splenius capitis et colli; 15, vertebral aponeurosis; 16, serratus posticus inferior; 17, supra-spinatus; 18, infra-spinatus; 19, teres minor; 20, teres major; 21, triceps; 22, serratus magnus.

into the posterior lip of bicipital groove of the humerus, with the tendon of the teres major.

Nerve—Subscapular of the brachial plexus.

Muscles of the Second Layer.

LEVATOR ANGULI SCAPULI.

Origin—Posterior tubercles of transverse process of

the first, second, third, and fourth cervical vertebræ.

Insertion—Superior angle of scapula and posterior border for one inch.

Nerve—Brachial plexus.

RHOMBOIDEUS MAJOR.

Origin—Spines of the first, second, third, and fourth dorsal vertebræ.

Insertion—Passes downward and outward, and is inserted into the vertebral border of scapula.

Nerve—Brachial plexus.

RHOMBOIDEUS MINOR.

Origin—Lower part of ligamentum nuchæ and spine of seventh cervical.

Insertion—Passes outward and downward, and is inserted into the vertebral border of the scapula above the rhomboideus major.

Nerve—Brachial plexus.

Muscles of the Third Layer.

SERRATUS POSTICUS SUPERIOR.

Origin—Lower part of ligamentum nuchæ, spine of last cervical and spines of upper two dorsal vertebræ.

Insertion—Passes downward and outward, and is inserted into the posterior surfaces of the second, third, fourth, and fifth ribs, beyond their angles.

Nerves—Posterior branches of cervical.

SERRATUS POSTICUS INFERIOR.

Origin—Spines of eleventh and twelfth dorsal and first and second lumbar vertebræ.

Insertion—Passes outward and upward, and is inserted into the posterior surface of the ninth, tenth, eleventh, and twelfth ribs.

Nerves—Dorsal.

SPLENIUS CAPITIS ET COLLI.

Origin—Lower half of ligamentum nuchæ, spine of seventh cervical, spine of six upper dorsal vertebræ.

Insertion—Passes upward and divides; the outer division is inserted into the mastoid portion of the temporal, the inner into the posterior tubercles of transverse processes of second, third, and fourth cervical vertebræ.

Nerves—Posterior branches of dorsal and cervical nerves.

Muscles of the Fourth Layer.

ERECTOR SPINÆ.

Origin—The mass of muscle filling in the grooves at the side of the spines of the vertebræ in the lumbo-sacral region. It arises from the sacro-iliac groove, spines of lumbar vertebræ, posterior surface of sacrum, posterior one-third of inner lip of crest of ilium.

Insertion—Passes upward; divides into the sacro-lumbalis and longissimus dorsi.

Nerves—Lumbar and dorsal.

SACROLUMBALIS.

Origin—From erector spinæ (outer division).

Inserted by six tendons into angles of six lower ribs.

Nerves—Dorsal.

ACCESSORY, or MUSCULUS ACCESSORIUS AD SACROLUMBALEM.

Origin—From six tendinous insertions of sacrolumbalis

Inserted by tendons into angles of six upper ribs.

Nerves—Dorsal.

CERVICALIS ASCENDENS.

Origin—From four upper tendons of insertion of the accessory muscle.

Insertion—Into the posterior tubercles of third, fourth, and fifth cervical vertebræ.

Nerves—Posterior cervical.

LONGISSIMUS DORSI.

Origin—Inner division of erector spinæ.

Insertion—To transverse processes of lumbar and dorsal vertebræ and into the eight upper ribs by the long tendons between neck and angles.

Nerve—Dorsal.

TRANSVERSALIS COLLI.

Origin—From transverse processes of third, fourth, fifth, and sixth dorsal vertebræ. Is a continuation of the longissimus dorsi.

Insertion—Inserted by five tendons into the transverse processes of third, fourth, fifth, sixth, and seventh cervical vertebræ.

Nerves—Posterior cervical.

TRACHELO-MASTOID.

Origin—Transverse processes of third, fourth, fifth, and sixth dorsal vertebræ and from three or four lower cervical.

Insertion—Mastoid process of temporal.

Nerves—Posterior cervical.

SPINALIS DORSI.

Origin—Spines of first and second lumbar and spines of eleventh and twelfth dorsal.

Insertion—Spines of second, third, fourth, fifth, sixth, and seventh dorsal vertebræ.

Nerves—Posterior dorsal.

SPINALIS COLLI.

Origin—Spines of fifth, sixth, and seventh cervical and first and second dorsal vertebræ.

Insertion—Spine of the axis.

Nerves—Posterior cervical.

COMPLEXUS.

Origin—By six or seven tendons from transverse processes of fifth, sixth, and seventh cervical and first, second, and third dorsal.

Insertion—Between superior and inferior curved lines of occipital by broad insertion.

Nerves—Posterior cervical.

BIVENTER CERVICIS.

Origin—From transverse processes of third, fourth, and fifth cervical vertebræ.

Insertion—Superior curved line of occipital to the inner side of complexus.

Nerves—Posterior cervical.

Muscles of the Fifth Layer.

SEMISPINALIS DORSI.

Origin—Transverse processes of sixth, seventh, eighth, ninth, tenth, eleventh, and twelfth dorsal vertebræ.

Insertion—Into the spinous processes of the first, second, third, and fourth dorsal vertebræ and sixth and seventh cervical.

Nerves—Posterior dorsal.

SEMISPINALIS COLLI.

Origin—Transverse processes of first, second, third, and fourth dorsal vertebræ and articular processes of lower three cervical vertebræ.

Insertion—Spinous processes of the second, third, fourth, and fifth cervical vertebræ.

Nerves—Posterior dorsal.

MULTIFIDUS SPINÆ.

Origin—Lies in the groove at the side of the spinous processes attached to the spinous, articular, and transverse processes from sacrum to axis.

Insertion—The tendons pass upward and inward, and

are inserted into the laminæ and spines of the vertebræ above.

Nerves—Posterior cervical, dorsal, and lumbar.

ROTATORES SPINÆ.

Origin—Eleven on each side of the spines of the dorsal vertebræ. Each arises from upper and back part of transverse process.

Insertion—Into the lower border of the vertebræ above.

Nerves—Posterior dorsal.

RECTUS CAPITIS POSTICUS MAJOR.

Origin—Spine of axis.

Insertion—Inferior curved line of occipital.

Nerves—Suboccipital.

RECTUS CAPITIS POSTICUS MINOR.

Origin—Posterior tubercle on atlas.

Insertion—Anterior to the inferior curved line of occipital.

Nerve—Suboccipital.

OBLIQUUS SUPERIOR.

Origin—Transverse process of atlas.

Insertion—Passes upward and is inserted below the superior curved line of occipital.

Nerve—Suboccipital.

OBLIQUUS INFERIOR.

Origin—Tip of the spine of the axis.

Insertion—Apex of transverse process of atlas.

Nerve—Suboccipital

SUPRASPINALES.

Origin—Fibres of muscles which pass between the apices of the spines of the cervical vertebræ.

Nerves—Posterior cervical.

INTERSPINALES.

Origin—Six on each side in the cervical region, two

or three in the dorsal region, four in the lumbar region, one between the last lumbar and sacrum.

Insertion—Small bundles of muscular fibres, arranged in pairs, which pass between the spinous processes.

Nerves—Dorsal.

EXTENSOR COCCYGIS.

Origin—Posterior surface of sacrum; it is rudimentary.

Insertion—Posterior surface of coccyx.

Nerves—Posterior sacral.

INTERTRANSVERSALES.

Origin—Six pairs on each side in the cervical region, three or four in the dorsal region, four in the lumbar region.

Insertion—Pass between the transverse processes in the cervical region; the bundles are separated by a distinct interval.

Nerves—Dorsal.

MUSCLES OF THE ABDOMEN.

EXTERNAL OBLIQUE.

Origin—Eight inferior ribs by eight fleshy digitations interdigitating with the pectoralis major and the serratus magnus.

Insertion—Inserted into the anterior one-third of the crest of the ilium, and into Poupart's ligament, which is the reduplicated inferior edge of the aponeurosis attached to the anterior superior spine of the ilium and the spine of the pubes. The muscle, by its aponeurosis, is also inserted into the linea alba for its entire length. The aponeurotic tendon passes entirely in front of the sheath of the rectus muscle. Just above the point of insertion of Poupart's ligament, the fibres of the aponeurosis of the external oblique diverge, leaving a triangular opening

with its base toward the linea alba; this is the external inguinal ring.

Nerves—Ilio-lumbar and ilio-hypogastric.

INTERNAL OBLIQUE.

Origin—Outer half of Poupart's ligament, anterior half of crest of ilium, and lumbar fascia.

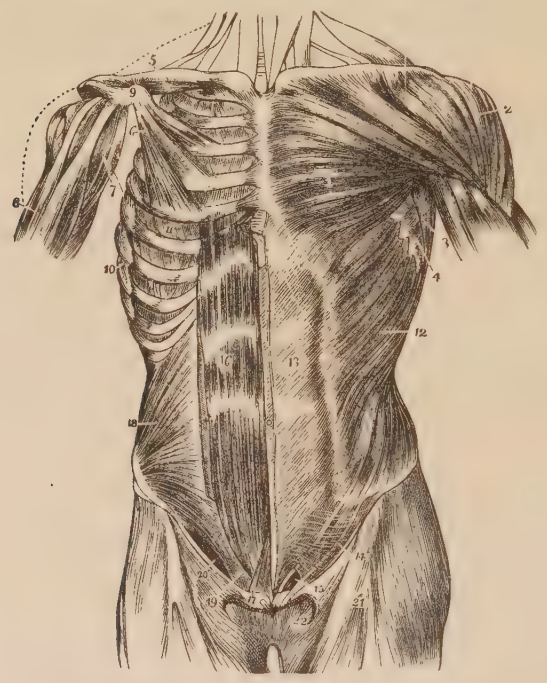

FIG. 89.—MUSCLES OF THE ABDOMEN.
12, external oblique; 16, rectus abdominis; 17, pyramidalis; 18, internal oblique; 19, quadratus lumborum.

Insertion—The iliac fibres are inserted into the three lower ribs; those from Poupart's ligament pass upward and inward, become aponeurotic, the aponeurosis reaches the outer border of the rectus muscle and splits, forming the sheath for the rectus (one leaflet passing in front, the other behind). The inner or lower fibres arch upward and outward, become aponeurotic; the aponeurosis joins

that of the transversalis and passes entirely in front of the rectus, forming the conjoined tendon of the external oblique and transversalis.

Nerves—Ilio-lumbar and ilio-hypogastric.

TRANSVERSALIS.

Origin—Outer one-third of Poupart's ligament, two-thirds of inner lip of crest of ilium, inner surfaces of cartilages of the six lower ribs, interdigitating with the fibres of the diaphragm, and from the lumbar fascia connected with the spines of the lumbar vertebræ.

Insertion—It passes transversely across the abdomen, becomes aponeurotic, the aponeurosis being attached to the linea alba; it passes behind the sheath of the rectus except for its lower one-fourth, where it joins the aponeurosis of the internal oblique, forming the conjoined tendon which passes down in front of the rectus and is attached to the upper border of the pubes.

Nerves—Ilio-inguinal and ilio-hypogastric.

RECTUS ABDOMINIS.

Origin—Passes from the ensiform cartilage to pubis. Arises from cartilages of fifth, sixth, and seventh ribs and ensiform cartilage.

Insertion—Passes downward, becoming narrower, and is inserted on crest of pubis. This muscle shows four or five transverse tendinous intersections.

Nerve—Ilio-hypogastric.

PYRAMIDALIS.

Origin—Superior border of pubis and anterior pubic ligament.

Insertion—Passes upward in front of rectus, and is inserted into linea alba below umbilicus.

Nerve—Ilio-inguinal.

QUADRATUS LUMBORUM.

Origin—Ilio-lumbar ligament, posterior part of crest of ilium, and upper border of transverse process of third, fourth, and fifth lumbar vertebræ.

Insertion—Into the last rib and by tendons into the transverse processes of third, fourth, and fifth lumbar.

Nerves—Ilio-hypogastric and lumbar.

The lumbar fascia is made by the division of the transversalis fascia into the three leaflets which are attached to the vertebræ. The anterior leaflet is attached

FIG. 90.—TRANSVERSE SECTION OF ABDOMEN, SHOWING THE ARRANGEMENT OF THE LUMBAR FASCIÆ.

to the anterior surface and base of the transverse processes of the lumbar vertebræ, and to the lower border of the last rib. The middle layer is attached to the apices of the transverse processes, and the posterior leaflet is attached to the apices of the spinous processes. Between the anterior and middle leaflets is the quadratus lumborum muscle, and between the middle and posterior leaflets is the erector spinæ mass of muscles. The sheath of the rectus muscle is formed by the separation of the aponeurosis of the internal oblique into an ante-

rior and posterior leaflet, except at the lower fourth of the rectus, where the entire aponeurosis passes in front of the muscle, with the aponeurosis of the transversalis making the conjoined tendon of the transversalis and internal oblique.

The linea alba, or white line, extends along the median line from the ensiform cartilage to the pubis. It is formed by the union of the aponeuroses of the abdominal muscles, and presents about its centre the umbilical foramen for the transmission of the structures of the umbilical cord in the fœtus. In the adult it is obliterated, the cicatrix being firmly adherent to the skin. The linea alba is traversed by very few vessels and nerves. The outer border of the rectus corresponds to the shallow, semilunar grooves known as the semilunar lines.

Muscles of the Upper Extremities.

Pectoralis Major.

Origin—Inner half of clavicle, outer half of sternum, cartilages of true ribs.

Insertion—Passes upward and outward, and is inserted into the anterior lip of the bicipital groove on the humerus.

Nerve—Anterior thoracic, from brachial plexus.

Pectoralis Minor.

Origin—Anterior surface of third, fourth, and fifth ribs.

Insertion—Coracoid process of scapula.

Nerve—Anterior thoracic, from brachial plexus.

Subclavius.

Origin—Cartilages of first rib.

Insertion—Under surface of the clavicle, about its centre.

Nerve—Posterior thoracic of brachial plexus.

SERRATUS MAGNUS.

Origin—By nine fleshy digitations from eight upper ribs, about one and one-half inches from the articulation of rib with costal cartilage.

Insertion—Posterior or vertebral border of scapula.

Nerve—Posterior thoracic of brachial plexus.

DELTOID.

Origin—External half of anterior border of clavicle, outer border of acromion, lower border of spine of scapula.

Insertion—Deltoid surface on outer side of humerus, about its middle.

Nerve—Circumflex, from brachial plexus.

SUBSCAPULAR.

Origin—Subscapular fossa.

Insertion—Lesser tuberosity of humerus.

Nerve—Subscapular, from brachial plexus.

SUPRA-SPINATUS.

Origin—Supra-spinous fossa.

Insertion—Highest facet on great tuberosity of humerus.

Nerve—Subscapular.

INFRA-SPINATUS.

Origin—Infra-spinous fossa.

Insertion—Middle facet on tuberosity of humerus.

Nerve—Subscapular.

TERES MINOR.

Origin—Upper two-thirds of dorsal surface of axillary border of scapula.

Insertion—Lowest facet on tuberosity of humerus.

Nerve—Circumflex.

TERES MAJOR.

Origin—Posterior surface of the inferior angle of the scapula.

Insertion—Posterior lip of bicipital groove of humerus, with latissimus dorsi.

Nerve—Subscapular.

CORACO-BRACHIALIS.

Origin—Coracoid process.

Insertion—Rough surface on inner side of humerus, opposite to the insertion of deltoid.

Nerve—External cutaneus.

FIG. 91.—MUSCLES OF SHOULDER AND ARM.
4, subscapularis; 5, teres major; 6, coraco-brachialis; 7, biceps.

FIG. 92.—TRICEPS MUSCLE.
1, external head; 2, scapular head; 4, insertion.

BICEPS.

Origin—Two heads,—long head from upper part of the glenoid cavity, short head from the coracoid process.

Insertion—Tuberosity of the radius. The tendon gives off a strong fascia at the bend of the elbow, which blends with the deep fascia.

Nerve—External cutaneus.

BRACHIALIS ANTICUS.

Origin—Anterior surface of lower half of humerus.

Insertion—Base of coracoid process of ulna.

Nerves—External cutaneus and musculo-spiral.

TRICEPS.

Origin—Three heads,—long head from lower part of glenoid cavity, middle head from posterior surface of humerus above musculo-spiral groove, short head from posterior surface of humerus below musculo-spiral groove.

Insertion—Olecranon process of ulna.

Nerve—Musculo-spiral.

SUBANCONEUS.

Origin—Posterior surface of lower part of humerus, beneath the triceps.

Insertion—Posterior ligament of elbow-joint.

Nerve—Musculo-spiral.

ANTERIOR MUSCLES OF THE FOREARM.

Superficial Layer.

PRONATOR RADII TERES.

Origin—Two heads,—first from internal epicondyle, second from coronoid process of ulna.

Insertion—Outer side of radius, about its middle.

Nerve—Median.

FLEXOR CARPI RADIALIS.

Origin—Internal epicondyle.

Insertion—Base of metacarpal of index finger.

Nerve—Median.

PALMARIS LONGUS.

Origin—Internal epicondyle.

Insertion—Passes downward in front of annular ligament, and expands into the deep palmar fascia.

Nerve—Median.

FLEXOR CARPI ULNARIS.

Origin—By two heads,—first from internal epicondyle, second from inner side of olecranon and from posterior border of ulna.

Insertion—Pisiform bone and metacarpal of little finger.

Nerve—Ulnar.

FLEXOR SUBLIMIS DIGITORUM.

Origin—Largest of the superficial layer from internal epicondyle, from coronoid process of ulna, from oblique line of radius.

Insertion—Divides into four tendons, which pass beneath the annular ligament and are inserted at the sides of the bases of the second phalanges of the fingers.

Nerve—Median.

Deep Layer.

FLEXOR PROFUNDUS DIGITORUM.

Origin—Upper two-thirds of shaft of ulna, from base of coronoid process, from ulnar half of interosseous membrane.

Insertion—Divides into four tendons, which pass beneath the annular ligament, then perforate the tendon of the flexor sublimis digitorum, and are inserted into the bases of the third phalanges.

Nerves—Ulnar and anterior interosseous of the median.

FLEXOR LONGUS POLLICIS.

Origin—Upper two-thirds of radius, radial half of interosseous membrane, and from base of coronoid process.

Insertion—Base of last phalanx of thumb.

Nerve—Anterior interosseous.

PRONATOR QUADRATUS.

Origin—Lower one-fourth of anterior surface of the ulna.

Insertion—Lower one-fourth of anterior and outer surface of radius.

Nerve—Anterior interosseous.

MUSCLES ON THE RADIAL SIDE OF FOREARM.

SUPINATOR LONGUS.

Origin—Upper half of external condyloid ridge of humerus.

Insertion—Styloid process of radius.

Nerve—Musculo-spiral.

EXTENSOR CARPI RADIALIS LONGIOR.

Origin—From external condyloid ridge of humerus.

Insertion—Posterior surface of the bases of the metacarpal bone of index finger.

Nerve—Musculo-spiral.

EXTENSOR CARPI RADIALIS BREVIOR.

Origin—From external condyloid ridge below the extensor carpi radialis brevior, and external epicondyle.

Insertion—Posterior surface of the base of the metacarpal of the middle finger.

Nerves—Musculo-spiral and posterior interosseous.

POSTERIOR MUSCLES OF FOREARM.

Superficial Layer.

EXTENSOR COMMUNIS DIGITORUM.

Origin—External epicondyle and intermuscular septa.

Insertion—Divides into four tendons, which are inserted on the dorsal and lateral surfaces of the first, second, and third phalanges.

Nerve—Posterior interosseous.

EXTENSOR CARPI ULNARIS.

Origin—External epicondyle of middle one-third of posterior surface of ulna.

Insertion—Dorsal surface of base of metacarpal of little finger.

Nerve—Posterior interosseous.

EXTENSOR MINIMI DIGITI.

Origin—External epicondyle, intermuscular septa.

Insertion—Divides into two tendons on back of hand, one of which communicates with the common extensor tendon, passes forward, and is inserted into the sides and posterior surface of the first, second, and third phalanges.

Nerve—Posterior interosseous.

ANCONEUS.

Origin—External epicondyle.

Insertion—Outer surface of olecranon and upper part of shaft of ulna.

Nerve—Musculo-spiral.

Deep Layer.

SUPINATOR BREVIS.

Origin—External epicondyle, external lateral ligament, orbicular ligament, ridge on outer surface of olecranon and upper part of ulna.

Insertion—Fibres curve around the radius, and are inserted at the anterior and inner border of the radius, about its middle third.

Nerve—Posterior interosseous, which pierces the muscle.

FIG. 93.—POSTERIOR MUSCLES OF FOREARM.

1, biceps; 2, brachialis anticus; 3, triceps; 4, supinator longus; 5, extensor carpi radialis longior; 6, extensor carpi radialis brevior; 7, insertion of extensor radialis longior and brevior; 8, extensor communis digitorum; 9 extensor minimi digiti; 10, extensor carpi ulnaris; 11, anconeus; 12, extensor carpi ulnaris; 13, 14, extensors of thumb; 15, annular ligament.

EXTENSOR INDICIS.

Origin—Posterior surface of ulna, interosseous membrane.

FIG. 94.—EXTENSOR TENDONS OF HAND.

1, extensor primi internodii pollicis; 2, first dorsal interosseous; 3, extensor indicis; 4, extensor communis; 5, extensor communis; this tendon sends lateral processes to the extensor tendons of the middle and little fingers; 6, annular ligament.

Insertion—Into the dorsal surface of second and third phalanges.

Nerve—Posterior interosseous.

EXTENSOR OSSIS METACARPI POLLICIS.

Origin—Posterior surface of shaft of ulna below the anconeus, from interosseous membrane, from middle third of shaft of radius.

Insertion—Dorsal surface of base of metacarpal of thumb.

Nerve—Posterior interosseous.

EXTENSOR PRIMI INTERNODII POLLICIS.

Origin—Lies to the inner side of the metacarpal of the thumb, from lower third of shaft of radius and interosseous membrane.

Insertion—Dorsal surface of base of first phalanx of thumb.

Nerve—Posterior interosseous.

EXTENSOR SECUNDI INTERNODII POLLICIS.

Origin—Posterior surface of shaft of ulna and interosseous membrane.

Insertion—Base of last (or second) phalanx of thumb.

Nerve—Posterior interosseous.

MUSCLES OF THE HAND.

Of the Thumb.

ABDUCTOR POLLICIS.

Origin—Ridge on trapezium and annular ligament.

Insertion—Radial side of base of first phalanx.

Nerve—Median.

OPPONENS POLLICIS.

Origin—From trapezium and annular ligament, external to abductor pollicis.

Insertion—Radial side of metacarpal of thumb for entire length.

Nerve—Median.

FLEXOR BREVIS POLLICIS.

Origin—Two heads,—first, trapezium and annular

ligament; second, from trapezoid, os magnum, and base of third metacarpal.

FIG. 95.—FLEXOR TENDONS AND MUSCLES OF HAND.

1, abductor pollicis; 2, flexor brevis pollicis; 3, abductor minimi digiti; 4, adductor pollicis; 5, lumbricales; 6, 7, tendons of flexor sublimis digitorum; 8, flexor muscles passing beneath annular ligament; 9, annular ligament; 10, flexor longus pollicis.

Insertion—At the sides of the base of first phalanx of thumb.

Nerve—Median.

ADDUCTOR POLLICIS.

Origin—Entire length of metacarpal of middle finger.

Insertion—Inner side of base of first phalanx of thumb.
Nerve—Ulnar.

Of the Little Finger.

ABDUCTOR MINIMI DIGITI.

Origin—Pisiform bone.
Insertion—Ulnar side of the base of first phalanx of little finger.
Nerve—Ulnar.

OPPONENS MINIMI DIGITI.

Origin—Placed deeply, arises from unciform process.
Insertion—Inserted into the whole length of fifth metacarpal along its ulnar side.
Nerve—Ulnar.

FLEXOR BREVIS MINIMI DIGITI.

Origin—From tip of unciform process and annular ligament.
Insertion—Base of first phalanx of little finger with the abductor minimi digiti.
Nerve—Ulnar.

Of the Palm.

PALMARIS BREVIS.

Origin—From annular ligament and fascia.
Insertion—Passes transversely toward the ulnar side, and is inserted into the skin.
Nerve—Ulnar.

LUMBRICALES.

Origin—Four in number, from sides of tendons of deep flexor.
Insertion—Into the aponeurosis of the extensor communis digitorum, at the radial side of the bases of first phalanges.
Nerves—Median and ulnar.

PALMAR INTEROSSEOUS MUSCLES.

Origin—Three in number, from entire length of second, fourth, and fifth metacarpal bones; that of

the second metacarpal comes from the ulnar side, those of the fourth and fifth from the radial side.

Insertion—They are inserted into bases of first phalanges, and are adductors toward the middle finger.

Nerve—Ulnar.

DORSAL INTEROSSEOUS MUSCLES.

Origin—Four in number; they are bipenniform muscles, and arise from the sides of the metacarpal bones: the first, from the sides of the metacarpal of thumb and index finger; the second, from those of the index and middle fingers; the fourth, from those of the ring and little fingers.

Insertion—The first is inserted into the radial side of the base of the first phalanx of index finger; the second, into the radial sides of base of first phalanx of middle finger; the third, on same bone on the ulnar side; the fourth, on base of first phalanx of ring-finger on ulnar side. They are abductors from the middle finger.

Nerve—Ulnar.

MUSCLES OF THE LOWER EXTREMITIES.

PSOAS MAGNUS.

Origin—Transverse processes and sides of bodies of lower two dorsal and all the lumbar vertebræ.

Insertion—On the lesser trochanter.

Nerves—Anterior lumbar.

PSOAS PARVUS.

Origin—Rudimentary, from last dorsal and first lumbar.

Insertion—Iliac fascia, near ilio-pectineal eminence.

Nerves—Anterior lumbar.

ILIACUS.

Origin—From inner surface of ilium, ilio-lumbar ligament, and base of sacrum.

Insertion—Lesser trochanter, by a tendon common to it and the psoas magnus.

Nerve—Anterior crural.

TENSOR VAGINÆ FEMORIS.

Origin—Anterior superior spine of ilium and external lip of anterior one-sixth of crest of ilium.

Insertion—It passes down between the two leaflets of the fascia lata, to which it is attached.

Nerve—Superior gluteal.

SARTORIUS.

Origin—The anterior superior spine of ilium.

Insertion—Passes obliquely across the thigh, and is attached to the inner side of head of tibia.

Nerve—Anterior crural.

RECTUS FEMORIS.

Origin—Two heads,—first, from anterior spine of ilium; second, from just above acetabular cavity.

Insertion—A bipenniform muscle inserted on the upper part of patella, and is continued as the ligamentum patellæ to the tuberosity of tibia.

Nerve—Anterior crural.

FIG. 96.—ANTERIOR FEMORAL REGION.

4, extensor vaginæ femoris; 5, sartorius; 6, rectus; 7, vastus externus; 8, vastus internus; 9, patella; 10, iliacus; 11, psoas; 12, pectineus; 13, adductor longus; 14, adductor magnus; 15, gracilis.

VASTUS EXTERNUS.

Origin—Great trochanter, shaft of femur, whole length of external lip of linea aspera.

Insertion—Folds around the outer surface of the shaft of femur, becomes aponeurotic, and is strongly attached to the tendon of the rectus femoris.

Nerve—Anterior crural.

VASTUS INTERNUS.

Origin—Internal lip of linea aspera for its whole length, and shaft of femur.

Insertion—Folds around the inner side of femur, and is strongly attached to the tendon of the rectus femoris.

Nerve—Anterior crural.

CRUREUS.

Origin—Anterior surface of femur between origin of the vasti.

Insertion—Into the tendon of the rectus femoris.

Nerve—Anterior crural.

SUBCRUREUS.

Origin—Rudimentary, beneath the crureus from the shaft of femur (often absent).

Insertion—Tendon of crureus.

Nerve—Anterior crural.

The rectus, vasti, and crureus are four muscles which have a single tendon of insertion, on the patella. Coming from such an extensive area of origin, the muscle (quadriceps extensor femoris), considered as a whole, is one of great power, sufficient, under certain conditions, even to fracture the patella. The tendon is broad and flat and incloses the patella, the greater mass of the tendinous fibres passing over the anterior surface of the bone, to be inserted on the tuberosity of the tibia.

GRACILIS.

Origin—Anterior surface of ramus of pubes and ischium.

Insertion—Upper inner surface of head of tibia.

Nerve—Obturator.

PECTINEUS.

Origin—Linea ilio-pectinea for about two inches external to Gimbernat's ligament.

Insertion—On line leading from trochanter minor to linea aspera.

Nerve—Obturator.

ADDUCTOR LONGUS.

Origin—Anterior surface of pubes.

Insertion—Middle third of linea aspera.

Nerve—Obturator.

ADDUCTOR BREVIS.

Origin—Anterior surface of body and descending ramus of pubes.

Insertion—Upper fourth of linea aspera.

Nerve—Obturator.

ADDUCTOR MAGNUS.

Origin—Anterior surface of the rami of ischium and pubes.

Insertion—Inner lip of linea aspera for its whole length, and by a rounded tendon into the inner tubercle above the internal condyle.

Nerve—Obturator.

FIG. 97.—ADDUCTOR MUSCLES OF THIGH.

1, obturator externus; 2, adductor longus; 3, adductor brevis; 4, adductor magnus.

GLUTEUS MAXIMUS.

Origin—Posterior part of the dorsum of the ilium

above superior curved line, posterior surface of sacrum and coccyx.

Insertion—Rough line leading from great trochanter to linea aspera and fascia lata.

Nerve—Small sciatic.

GLUTEUS MEDIUS.

Origin—Dorsum of ilium between superior and middle curved lines and crest of ilium.

Insertion — Oblique line on outer surface of the great trochanter.

Nerve—Superior gluteal.

GLUTEUS MINIMUS.

Origin—From dorsum of ilium between middle and the inferior curved lines.

Insertion — Anterior surface of great trochanter.

Nerve—Superior gluteal.

FIG. 98.—DEEP MUSCLES OF GLUTEAL REGION.

1, ilium; 2, sacral spine; 3, attachment of sacro-iliac ligaments; 4, tuberosity of ischium; 5, greater sacro-sciatic ligament; 6, lesser sacro-sciatic ligament; 7, greater trochanter; 8, gluteus minimus; 9, pyriform; 10, superior gemellus; 11, tendon of obturator internus; 12, gemellus inferior; 13, quadratus femoris; 14, adductor magnus; 15, vastus externus; 16, biceps; 17, gracilis; 18, semitendinosus.

PYRIFORMIS.

Origin—From anterior surface of sacrum between the anterior sacral foramina.

Insertion—Passes out of the pelvis by the greater sacro-sciatic foramen, and is inserted into the upper border of the great trochanter.

Nerve—Small sciatic.

OBTURATOR INTERNUS.

Origin—Stretched across the obturator foramen is the

aponeurotic obturator membrane, presenting at its upper part the opening for the obturator vessels and nerve. From the inner surface of this membrane arises the obturator internus muscle; it also arises from the posterior surface of the rami of the ischium and pubes and the margins of the obturator foramen.

Insertion—Passes out of the pelvis by the lesser sacro-sciatic foramen, and is inserted into the upper border of the great trochanter.

Nerves—Small sciatic and sacral plexus.

GEMELLUS SUPERIOR.

Origin—A bundle of muscular fibres above the tendon of the obturator internus; arises from the margin of the lesser sacro-sciatic foramen and spine of ischium.

Insertion—Upper border of great trochanter, with tendon of obturator internus.

Nerve—Sacral plexus.

GEMELLUS INFERIOR.

Origin—Similarly arranged as the gemellus superior; arises from tuberosity of ischium.

Insertion—Great trochanter with obturator internus.

Nerve—Sacral plexus.

OBTURATOR EXTERNUS.

Origin—Outer surface of obturator membrane, rami of pubes and ischium.

Insertion—Digital fossa.

Nerve—Obturator, from lumbar plexus.

QUADRATUS FEMORIS.

Origin—Outer surface of tuberosity of ischium.

Insertion—Quadrate line on femur.

Nerve—Sacral plexus.

BICEPS.

Origin—Two heads,—the long head from lower facet

on external surface of tuberosity of the ischium; short head, from the linea aspera about its middle third.

Insertion—Head of fibula; it is the outer ham-string muscle.

Nerve—Great sciatic.

SEMIMEMBRANOSUS.

Origin—The innermost ham-string; from posterior or upper facet on outer surface, and posterior border of tuberosity of ischium.

Insertion—Inserted by three tendons,—the inner, attached to inner side of head of tibia; the middle, blending with the posterior ligaments of the knee-joint; the outer, inserted above the outer condyle of the femur. This arrangement of the tendons makes, in fact, the posterior ligament of the knee-joint.

Nerve—Great sciatic.

FIG. 99.—POSTERIOR FEMORAL REGION.

1, gluteus medius; 2, gluteus maximus; 3, vastus externus; 4, biceps; 6, semitendinosus; 7, semimembranosus; 8, gracilis.

SEMITENDINOSUS.

Origin—From facets common to it and the biceps.

Insertion—Upper part of inner surface of head of tibia.

Nerve—Great sciatic.

The biceps is the external ham-string; the semimembranosus and the semitendinosus are the two internal ham-strings; they limit the popliteal space laterally.

TIBIALIS ANTICUS.

Origin—Outer surface of shaft of tibia, interosseous membrane.

Insertion—Dorsal and inner side of base of metatarsal of great toe.

Nerve—Anterior tibial.

EXTENSOR LONGUS DIGITORUM.

Origin—Anterior upper part of fibular and interosseous membrane.

Insertion—Divides into four tendons, to be inserted upon the four outer toes similarly to the insertion of the common extensor of the fingers.

Nerve—Anterior tibial.

EXTENSOR PROPRIUS POLLICIS.

Origin—Anterior surface of middle third of fibula and interosseous membrane.

Insertion—Passes down between the tibialis anticus and extensor longus digitorum; inserted at the base of the last phalanx of the great toe.

Nerve—Anterior tibial.

FIG. 100.—ANTERIOR MUSCLES OF LEG.

3, tibialis anticus; 4, extensor longus digitorum; 5, extensor proprius pollicis; 6, peroneus tertius; 7, peroneus longus; 8, peroneus brevis.

PERONEUS TERTIUS.

Origin—Lower fourth of anterior part of fibula and interosseous membrane.

Insertion—Upper surface of the base of metatarsal of little toe.

Nerve—Anterior tibial.

PERONEUS LONGUS.

Origin—Head and upper two-thirds of the outer part of the shaft of fibula.

Insertion—Passes down behind the outer malleolus, lying in the same groove as the peroneus brevis, then through a groove on the inferior surface of the cuboid, and is inserted on the inferior surface of the base of the metatarsal of the great toe.

Nerve—Musculo-cutaneus.

PERONEUS BREVIS.

Origin—From lower two-thirds of the anterior surface of the shaft of fibula.

Insertion—Passes behind the outer malleolus, and is inserted into the outer part of the base of the metatarsal of the little toe.

Nerve—Musculo-cutaneus.

The tendons of the peroneus longus and brevis pass behind the external malleolus.

GASTROCNEMIUS.

Origin—With the soleus forms the calf of the leg; arises by two heads from above the outer and inner condyles of the femur.

Insertion—About the lower third, becomes tendinous and receives the insertion of the soleus, forming the tendo Achillis, which is inserted on the posterior surface of the os calcis.

Nerve—Internal popliteal.

SOLEUS.

Origin—From posterior surface of head of fibula, posterior surface of upper third of shaft of tibia and its oblique line.

Insertion—On the tendon of the gastrocnemius, forming the tendo Achillis.

Nerve—Internal popliteal.

PLANTARIS.

Origin—Rudimentary, from just above the outer head of gastrocnemius.

Insertion—Passes down between the gastrocnemius, forming the tendo Achillis.

Nerve—Internal popliteal.

POPLITEUS.

Origin—Outer side of external condyle.

Insertion—Passes obliquely downward and inward, and is inserted along the inner border of the upper third of tibia.

Nerve—Internal popliteal.

TIBIALIS POSTICUS.

Origin—Arises between the flexor longus digitorum, from posterior surface of interosseous membrane, posterior surface of shaft of tibia, from oblique line, from upper two-thirds of shaft of fibula.

Insertion—Crosses in front of flexor longus digitorum, and is inserted on the tuberosity of scaphoid, internal cuneiform, and base of metatarsal of great toe. The tendon lies in the anterior groove on the posterior surface of the external malleolus.

Nerve—Posterior tibial.

FIG. 101.—POSTERIOR MUSCLES OF LEG.

4, popliteus; 5, gastrocnemius; 6, tendo Achillis; 8, tendons of peroneus longus and brevis; 9, tibialis posticus and flexors.

FLEXOR LONGUS POLLICIS.

Origin—Lower two-thirds of posterior surface of shaft of fibula, a small portion of posterior surface of interosseous membrane.

Insertion—Lies in the posterior groove behind the inner malleolus, in the groove on the astragalus, and is inserted on the base of last phalanx of great toe.

Nerve—Posterior tibial.

FLEXOR LONGUS DIGITORUM.

Origin—Posterior surface of shaft of tibia, below oblique line.

Insertion—Lies in the middle groove on the posterior surface of internal malleolus, passes beneath the arch of the os calcis, and divides into four tendons, which are inserted on the bases of the last phalanges of the four outer toes; these tendons perforate the tendons of the flexor brevis digitorum.

Nerve—Posterior tibial.

MUSCLES OF THE FOOT.

Dorsal Region.

EXTENSOR BREVIS DIGITORUM.

Origin—Outer surface of os calcis, from annular ligament and calcaneo-astragaloid ligament.

Insertion—Passes inward across the foot and divides into four tendons, which are inserted on the dorsal surface of the four inner toes.

Nerve—Anterior tibial.

Plantar Region.

Plantar muscles are divided into four layers:—

First Layer.

ABDUCTOR POLLICIS.

Origin—Inner tubercle of os calcis.

Insertion—Inner side of base of first phalanx of great toe.

Nerve—Internal plantar.

FLEXOR BREVIS DIGITORUM.

Origin—Inner tubercle of os calcis.

Insertion—Divides into four tendons, which are perforated by the tendons of the flexor longus digitorum; inserted on the side of second phalanges.

Nerve—Internal plantar.

ABDUCTOR MINIMI DIGITI.

Origin—Outer tubercle and inferior surface of os calcis.

Insertion—Outer side of base of first phalanx of little toe.

Nerve—External plantar.

Second Layer.

FLEXOR ACCESSORIUS.

Origin—Two heads,—outer, from in front of outer tubercle; inner, from in front of inner tubercle.

Insertion—Posterior edge of the tendon of flexor longus digitorum.

Nerve—External plantar.

FOUR LUMBRICALES.

Origin—From sides of tendons of long flexor.

Insertion—Each muscle is inserted on the inner side of the bases of first phalanges of the four outer toes.

Nerves—Internal and external plantar.

FIG. 102.—SECOND LAYER OF MUSCLES OF FOOT.
1, flexor accessorius; 2, flex. long. digitorum; 3, flex. long. pollicis.

Third Layer.

FLEXOR BREVIS POLLICIS.

Origin—From inner part of cuboid and outer cuneiform, and tendon of posterior tibial.

Insertion—Inserted by two tendons into the inner and outer sides of base of first phalanx of great toe.

Nerve—Internal plantar.

ADDUCTOR POLLICIS.

Origin—Bases of second, third, and fourth metatarsals, and sheath of tendon of peroneus longus.

Insertion—Outer side of base of first phalanx of great toe.

Nerve—External plantar.

FLEXOR BREVIS MINIMI DIGITI.

Origin—Base of metatarsal of little toe and sheath of peroneus longus.

Insertion—Outer side of base of first phalanx of little toe.

Nerve—External plantar.

TRANSVERSUS PEDIS.

Origin—Under surface of head of metatarsal of little toe.

Insertion—Outer side of base of first phalanx of great toe.

Nerve—External plantar.

Fourth Layer.

PALMAR INTEROSSEI.

Origin—Three in number, from base and inner sides of shaft of third, fourth, and fifth metatarsals.

Insertion—Inner side of base of first phalanx of the same toe.

Nerve—External plantar.

The palmar interossei are adductors toward the second toe.

DORSAL INTEROSSEI.

Origin—Four in number, bipenniform muscles from adjoining side of the metatarsal bones.

Insertion—The dorsal interossei are inserted on the inner side of the bases of first phalanges of the second, third, and fourth toes, and on the outer side of the bases of the second, third, and fourth toes.

Nerve—External plantar.

The dorsal interossei are abductors from the second toe. The second toe receives the insertion of two interosseous muscles,—one on the inner, the other on the outer side of the base of the phalanx.

MUSCLES OF THE PERINEUM AND ISCHIO-RECTAL REGION.

In the Male.

ACCELERATOR URINÆ.

Origin—A bipenniform muscle, from central tendon of perineum in front of anus; the tendon lies beneath the urethra, in the median line.

Insertion—The muscular fibres curve around the urethra, encircle the bulb, and are lost on its upper surface.

Nerve—Perineal.

ERECTOR PENIS.

Origin—Inner border of ascending ramus of ischium and ramus of pubes.

Insertion—Ends in aponeurosis, which is inserted into the side and under surface of crus penis.

Nerve—Perineal.

TRANSVERSUS PERINÆI.

Origin—Inner surface of tuberosity of ischium.

Insertion—Passes inward and forward, and is inserted on the central tendon of perineum just anterior to the anus.

Nerve—Perineal.

LEVATOR ANI.

Origin—Attached to the inner sides of the true pelvis,

arises from posterior surface of body of pubes, spine of ischium, and obturator ligament, extending from spine of ischium to posterior surface of pubes. This ligament is formed by the junction of the obturator with the recto-vesical fascia.

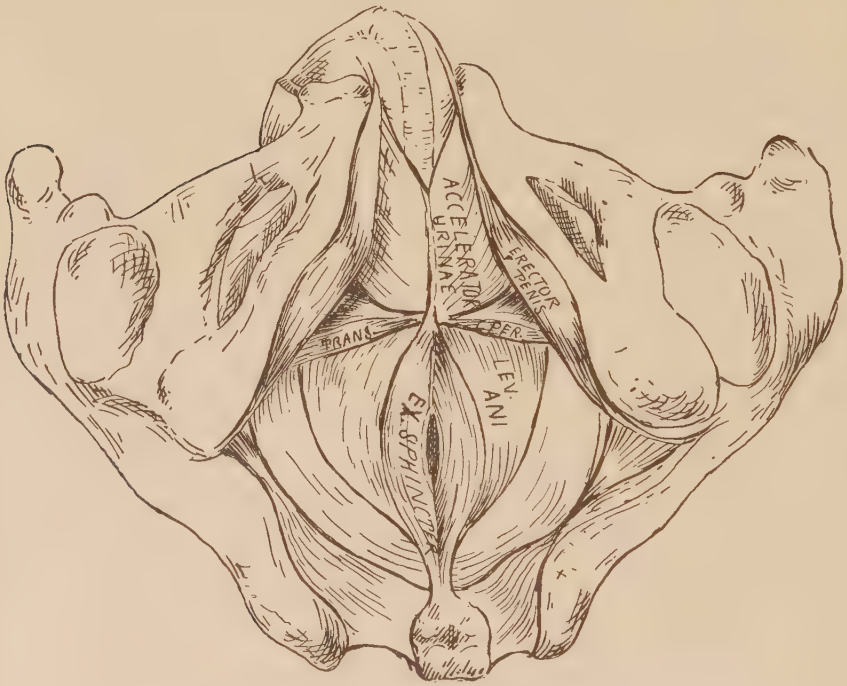

FIG. 103.—MUSCLES OF THE PERINEUM.

Insertion—Into coccyx and sides of rectum and sphincter, side of prostate gland; it forms a sling, which supports the pelvic viscera.

Nerve—Perineal.

COMPRESSOR URETHRÆ.

Origin—From border of ramus of pubes, and passes down and surrounds the membranous urethra.

Nerve—Perineal.

CORRUGATOR CUTIS ANI.

Origin—Subcutaneous fibres of muscular tissue, largely involuntary, which wrinkle the skin around the anus.

Insertion—Skin around anus.

Nerve—Perineal.

EXTERNAL SPHINCTER ANI.

Origin—Plane of muscular fibres subcutaneous and attached to the skin; arises from tip of coccyx.

Insertion—Tendinous centre of perineum after elliptically surrounding the anus.

Nerve—Fourth sacral.

INTERNAL SPHINCTER ANI.

Origin—A ring of muscle around the lower end of the rectum, about one-fourth of an inch thick, three-fourths to one and one-half inches wide.

Insertion—Is a mixture of voluntary and involuntary fibres.

Nerves—Sacral and sympathetic plexuses.

In the Female.

The special muscles in this region are:—

SPHINCTER VAGINÆ. Surrounds the vaginal orifice; it is a continuation of the external sphincter ani, and is inserted anteriorly into the corpora cavernosa clitoridis.

ERECTOR CLITORIDIS. Similar in its attachments to the erector penis.

TRANSVERSUS PERINÆI. Like its attachments in the male.

COMPRESSOR URETHRÆ. Like its attachments in the male.

SPHINCTER ANI, EXTERNAL AND INTERNAL. Like their attachments in the male.

COCCYGEUS. Like its attachments in the male.

LEVATOR ANI. Attached below to sides of rectum and vagina

THE VASCULAR SYSTEM.

ARTERIES.

The arteries are vessels which convey blood from the heart to the tissues and organs. The largest arteries are the aorta and pulmonary. The aorta springs from the left ventricle and transmits oxygenated blood to every part of the body. The pulmonary artery comes from the right ventricle and conveys the blood charged with carbonic oxide to the lungs, there to be oxygenated. An artery, as it follows its course, branches repeatedly, often dichotomously, and forms frequent anastomosis among its branches. Each time an artery gives off a branch its diameter decreases; where an artery such as the abdominal aorta divides into the two large trunks each trunk has an area larger than one-half the area of the main vessel, and the combined area of the two vessels is larger than the area of the main trunk. The combined area of all the ultimate branches of the arterial tree is many times more than the area of the aorta. The arteries are highly elastic, both in diameter and length, and under the impulse of the blood-wave stretch in length and swell in diameter. They are composed of three coats,—external or fibrous, middle or muscular, and internal or serous. The inner and middle coats are closely adherent. The external

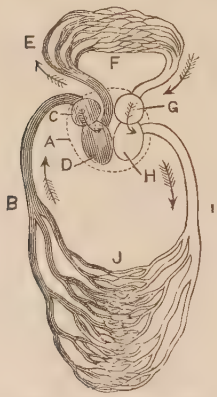

Fig. 104.—Diagram of the Circulation.

A, heart; B, vena cava; C, right auricle; D, right ventricle; E, pulmonary artery; F, pulmonic capillaries; G, left auricle; H, left ventricle; I, aorta; J, systemic capillaries.

coat is cellular in character, composed principally of white fibrous tissues arranged in a reticulated manner; there are also found some elastic and muscular fibres. The middle coat in the aorta and large vessels is a dense, thick cylinder of yellow elastic tissue. As the vessels become smaller in size the elastic fibres become mixed with the involuntary muscular fibres, and in vessels of the size of the ulnar the muscular tissue nearly entirely replaces the yellow elastic fibres. The muscular fibres encircle the vessel, and are also disposed in longitudinal bundles. The internal or serous coat presents, like any other serous membrane or sac, three layers: First, a free or epithelial; second, a middle or basement membrane; third, an outer or fibrous layer. The epithelial consists of a single layer of flat epithelial cells accurately joined together by an intercellular cement-substance resembling gelatin; here and there, however, a slight fissure between the cells can be seen. Second, a basement-membrane consisting of a homegeneous membrane supported by the skeletal, reticulated, connective-tissue cell-layer. Third, a fenestrated membrane composed of white and yellow elastic fibres.

As arteries become much reduced in size they lose some of their physical characters, and when they are very small and but two coats are distinguishable they take the name of arterioles. While capillaries are the smallest radicles of the arterial system, measuring on an average about one three-thousandth of an inch in diameter, they present, as a rule, but a single coat, the inner, and frequently of this only the epithelial layer exists. Thus, in the capillaries of the lungs, brain, and liver the only structure presented by the capillary is a single layer of epithelial cells jointed at their edges.

THE AORTA.

The aorta springs from the base of the left ventricle, curves upward toward the right, then forms an arch the convexity of which is superior; it then passes down the

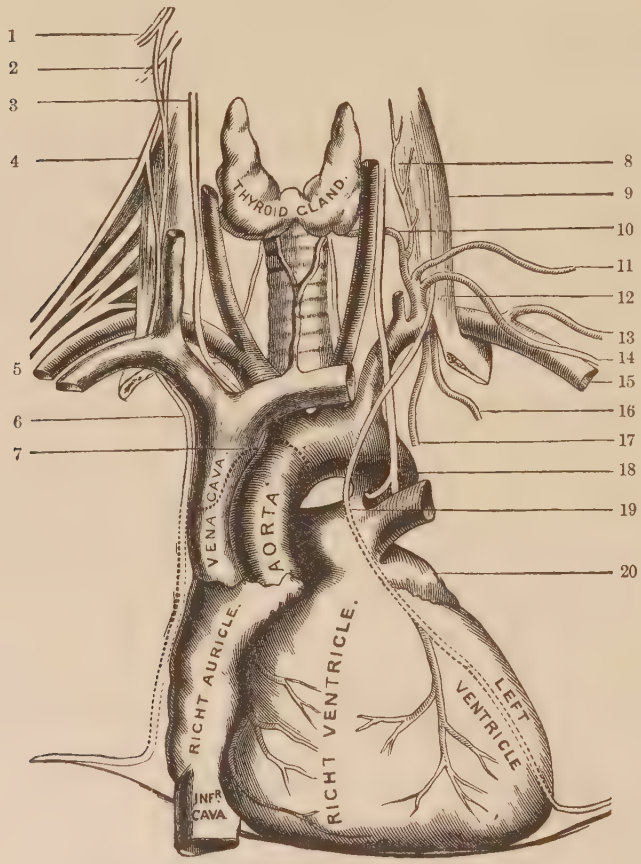

FIG. 105.—THE AORTA.

1, third cervical nerve; 2, fourth cervical nerve; 3, pneumogastric nerve; 4, fifth cervical nerve; 5, brachial plexus; 6, phrenic nerve; 7, lines of reflection of pericardium; 8, cervicalis ascendens artery; 9, scalenus anticus; 10, inferior thyroid artery; 11, superficialis colli artery; 12, phrenic nerve; 13, posterior scapular artery; 14, supra-scapular artery; 15, subclavian artery; 16, superior intercostal artery; 17, internal mammary artery; 18, pneumogastric nerve; 19, phrenic nerve; 20, appendix of left auricle.

left side of the vertebral column through the aortic opening in the diaphragm, and divides at the fourth lumbar vertebra into the two common iliacs. The aorta is divided

into an arch, the thoracic portion and the abdominal portion. The arch of the aorta is horseshoe-shaped. It begins at the left ventricle of the heart (about the level of the fourth dorsal vertebra), curves upward, forward, and to the right on a level with the second right costal cartilage, forming the ascending portion of the arch. It then curves transversely backward and to the left to the lower border of the second dorsal vertebra, forming the transverse portion; then descends to the left of the vertebral column to the fifth dorsal vertebra, whence it is continued down the spine under the name of the thoracic aorta. The arch of the aorta sends off five branches.

From the ascending part of the arch are the right and left coronary:—

Right Coronary.—Branch from the aorta immediately above its origin; lies in right auriculo-ventricular groove; sends a branch down posterior interventricular groove.

Left Coronary.—Branch from the aorta immediately above its origin; lies in the anterior interventricular groove and anastomoses with the descending branch of the right coronary.

From the transverse part of the arch are the innominate, left carotid, and left subclavian:—

Innominate.—From superior part of right side of arch. The largest branch of the arch passes upward to the right sterno-clavicular joint, where it divides into the right subclavian and right common carotid.

Left Carotid.—Passes upward behind the manubrian and terminates in the neck on a level with the thyroid cartilage, where it divides into the external and internal carotids. The common carotid give off no branches.

Left Subclavian.—The last vessel from the arch of the aorta curves into the root of the neck and terminates at the lower border of the first rib.

THE SUBCLAVIAN ARTERY.

The subclavian artery curves up into the root of the neck, and at the lower border of the first rib becomes the axillary. As the scalenus anticus muscle passes over the subclavian to be inserted on the tubercle on the first rib, it divides the innominate into three parts, the first part being internal to the inner border of the scalenus anticus, the second part behind the scalenus anticus, the third external to the scalenus anticus. The branches of the subclavian are four in number,—two ascending and two descending; the ascending are the vertebral and thyroid axis from the first part of the subclavian; the descending are the internal mammary and superior intercostal; of these the internal mammary comes from the second part of the subclavian; there are no branches from the third part.

THE VERTEBRAL ARTERY.

The vertebral artery passes up along the side of the cervical vertebræ through the foramina in the transverse processes, and passes behind the articular surface on the atlas, enters the skull through the foramen magnum, joins its fellow and forms the basilar artery, which passes forward beneath the pons Varolii, and divides into the posterior cerebral arteries. The vertebral sends off branches as follows:—

In the Neck.

Lateral Spinal.—Seven or eight branches which pass through the intervertebral foramina and divide into anterior and posterior branches.

Muscular.—Distributed to the deep muscles of neck.

In the Cranium.

Anterior Spinal.—From the upper part of the vertebral. It anastomoses with its fellow and forms the

median descending artery, which is continued by anastomosis the entire length of the spinal cord.

Posterior Spinal.—Unites with its fellow and forms through anastomosis the descending median spinal artery.

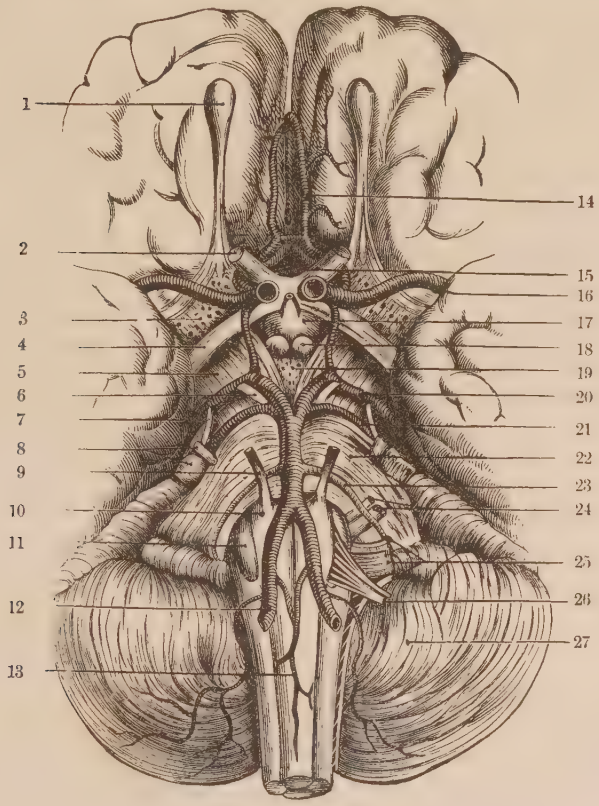

FIG. 106.—BASE OF BRAIN, SHOWING CIRCLE OF WILLIS.

1, olfactory bulb; 2, optic nerves; 3, anterior perforated space; 4, tractus opticus; 5, crus cerebri; 6, third pair of nerves; 7, fourth pair of nerves; 8, fifth pair of nerves; 9, sixth pair of nerves; 10, pyramid; 11, olivary body; 12, vertebral artery; 13, anterior spinal artery; 14, anterior cerebral artery; 15, lamina cinerea; 16, middle cerebral artery; 17, tuber cinereum; 18, corpora albicantia; 19, posterior perforated space; 20, posterior cerebral artery; 21, anterior cerebellar artery; 22, pons Varolii; 23, posterior inferior artery; 24, seventh and eighth pairs of nerves; 25, ninth, tenth, and eleventh pairs of nerves; 26, twelfth pair of nerves; 27, cerebellum.

Posterior Meningeal.—Enters foramen magnum, and is distributed to the meninges.

Posterior Inferior.—Winds around the upper part of medulla and is distributed to the cerebellum.

THE BASILAR ARTERY.

The basilar artery runs along the median line of the under surface of the pons Varolii. It is formed by the union of the two vertebral arteries and sends off:—

Anterior Cerebellar.—Passes to the under surface of cerebellum.

Transverse.—Four to six pairs distributed to inferior surface of cerebellum.

Superior Cerebellar.—Pass around the crura and are distributed to meninges.

Posterior Cerebral.—Two terminal; wind around the crura and anastomose with the middle cerebral.

At the base of the brain is a vascular circle, the circle of Willis. It is formed by nine vessels,—the two posterior cerebral (terminal branches of the basilar), the two posterior communicating (branches of the internal carotid), the two anterior cerebral (branches of the internal carotid), the two internal carotids, and the anterior communicating between the two anterior cerebral arteries within. This anastomosis surrounds the structures of the interpeduncular space.

THE THYROID AXIS.

The thyroid axis sends off:—

Inferior Thyroid.—Supplies the inferior portion of the thyroid gland. It sends off the laryngeal, tracheal, œsophageal, and ascending cervical; the last named passes up the neck and anastomoses with the ascending pharyngeal.

Supra-scapular.—Runs across the neck over the transverse ligament of the scapula and is distributed to the supraspinatus

Transversalis Colli.—Runs transversely across the neck to the vertebral border of the scapula, along

which it runs to anastomose at the inferior angle with the subscapular.

The Internal Mammary.—Runs along the posterior surface of the anterior wall of the chest and sends off:—

Phrenic.—Accompanies the phrenic nerve.

Anterior Costal.—Five to seven branches to intercostal spaces.

Mediastinal.—To anterior mediastinum.

Pericardiac.—To outer surface of pericardium.

Perforating.—Perforate the intercostal spaces and are distributed to the mammary gland.

Sternal.—Nutrient to sternum.

Muscular.—To intercostals and triangularis sterni.

Superior Epigastric.—Anastomoses with deep epigastric of the external iliac.

Superior Intercostal.—Distributed to the two upper intercostal spaces. It sends off the profunda cervicis to anastomose with the princeps cervicis of the occipital.

THE AXILLARY ARTERY.

The axillary artery is the continuation of the subclavian; it begins at the lower border of the first rib and becomes the brachial at the lower border of the pectoralis major muscle. It runs midway between the anterior and posterior borders of the axilla and is crossed by the pectoralis minor muscle, which divides it into three parts; from the first part above the pectoralis minor are given off two vessels:—

Superior Thoracic.—Passes inward and supplies the muscles of the chest.

Acromio-thoracic.—A short trunk which divides into the acromial, distributed to the shoulder, and the thoracic, to the pectoral muscles.

From the second part behind the pectoralis minor come off:—

Long Thoracic.—Passes inward along the inferior border of the pectoralis major.

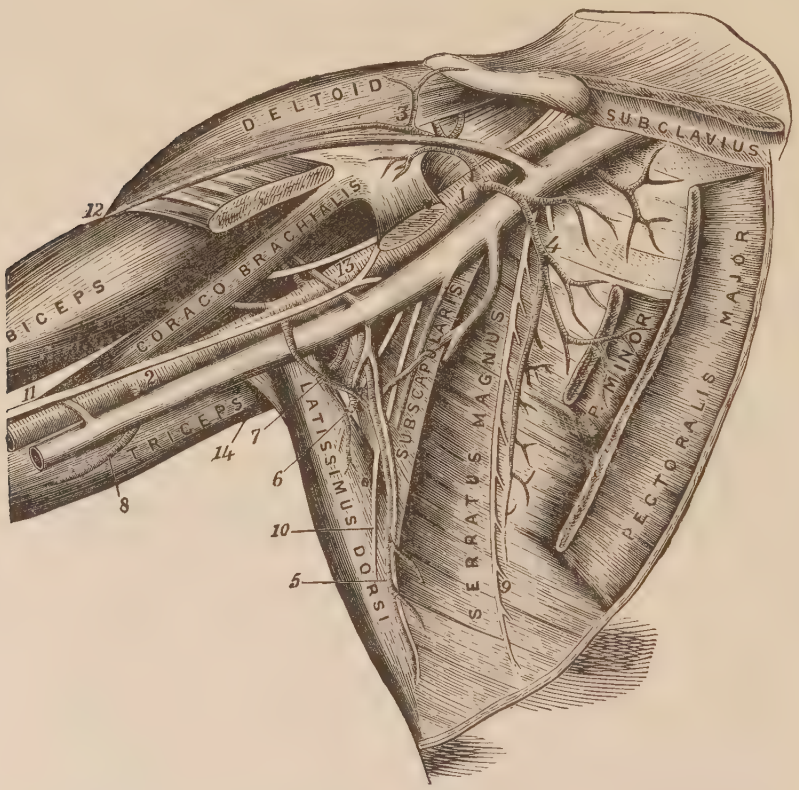

FIG. 107.—DIAGRAM OF AXILLA.

1, axillary artery; 2, brachial artery; 3, acromio-thoracic artery; 4, superior thoracic artery; 5, subscapular artery; 6, dorsalis scapulæ artery; 7, posterior circumflex artery; 8, superior profunda artery; 9, posterior thoracic nerve; 10, long subscapular nerve; 11, median nerve; 12, cephalic vein; 13, musculo-cutaneous nerve; 14, teres major muscle.

Alar Thoracic.—Two or three branches (small) to side of chest.

From the third part, below pectoralis minor, are given off:—

Subscapular.—The largest branch of the axillary runs

along the anterior surface of the subscapular muscle and anastomoses with the posterior scapular.

Anterior Circumflex.—Encircles the neck of the humerus.

Posterior Circumflex.—Encircles the neck of the humerus.

THE BRACHIAL ARTERY.

The brachial artery is a continuation of the axillary, and runs down the inner side of arm and terminates at the bend of the elbow, where it divides into the radial and ulnar. It sends off:—

Superior Profunda.—Runs in the musculo-spiral groove, supplies the muscles, and anastomoses with the recurrent branches at the bend of the elbow.

Inferior Profunda.—Anastomoses with the ulnar recurrent, and is distributed to internal condyle.

Nutrient.—Supplies the humerus.

Anastomotica Magna.—Arises above elbow-joint and anastomoses with the profunda and recurrent arteries.

Muscular.—To muscles of arm.

THE RADIAL ARTERY.

The radial artery, smaller than the ulnar, passes down along the radial side of forearm. It is subcutaneous for its lower third, then passes over the back of the base of the metacarpal of the thumb, and runs down between the two heads of the first dorsal interosseous muscle into the palm of the hand, lying on the bases of the metacarpals, and forms the deep palmar arch. The radial sends off three sets of vessels.

In the Forearm.

Radial Recurrent.—Passes up and anastomoses with the superior profunda.

Muscular.—To the muscles of the forearm.

Superficialis Volæ.—Given off above the muscles of the thumb, which it crosses and anastomoses with ulnar.

At the Wrist.

Anterior Carpal.—To the wrist.

Posterior Carpal.—To the wrist.

Metacarpel.—To first interosseous space.

Dorsalis Pollicis.—One or two vessels along back of thumb.

Dorsalis Indicis.—One or two vessels along back of index finger.

In the Hand.

Princeps Pollicis.—Supplies palmar aspect of thumb.

Radialis Indicis.—Radial side of index finger.

Interosseous.—Three or four that pass forward and anastomose with digital.

Perforating—Anastomoses with dorsal interosseous.

THE ULNAR ARTERY.

The ulnar artery, larger than the radial, passes deeply through the muscles along the ulnar side of the forearm and sends off:—

Anterior Ulnar Recurrent.—Passes up and anastomoses with the anastomotica magna and profunda.

Posterior Ulnar Recurrent.—Passes up and anastomoses with the anastomotica magna and profunda.

Interosseous.—Divides into (*a*) anterior, which runs along the interosseous membrane anteriorly; (*b*) posterior, which runs along the interosseous membrane posteriorly.

Muscular.—To muscles of forearm.

Anterior Carpal.—To muscles of wrist-joint.

Posterior Carpal.—To wrist-joint.

Communicating.—Anastomoses with the radial, completing the deep arch.

Digital.—Four in number; pass to the webs of fingers and divide into two branches, which run along the sides of the fingers and terminate in anastomotic plexuses at the ends of the fingers.

The superficial arch is the palmar continuation of the ulnar; it lies on a line drawn transversely across the hand from the web of thumb; the deep palmar arch formed by the radial lies higher up,—a fact of surgical interest.

THE COMMON CAROTID ARTERY.

The common carotid artery on the right side is a branch of the innominate; on the left side it comes from the arch of the aorta. It divides just below the hyoid bone into the internal and external carotid.

THE EXTERNAL CAROTID ARTERY.

The external carotid artery passes up the neck, giving off large branches that supply the neck, face, and head with blood. It sends off eight branches. They are:

Three Anterior.

Superior Thyroid.—Arises on a level with the hyoid bone, and sends off four branches: the hyoid, sterno-mastoid, crico-thyroid, and superior laryngeal.

Lingual.—Arises above the superior thyroid; sends off the hyoid, sublingual, dorsalis lingua, and ranine.

Facial.—Arises just below the angle of inferior maxillary, runs through the submaxillary gland, crosses the inferior border of inferior maxilla just in front of masseter; it is very tortuous, and gives off ten branches:—

IN THE NECK.

Ascending palatine,
Tonsillar,
Submaxillary,
Submental.

FACIAL BRANCHES.

Muscular,
Inferior labial,
Inferior coronary,
Superior coronary,
Lateral nasal,
Angular.

Two Posterior.

Occipital.—Arises opposite to facial, passes backward, lies in occipital groove, and sends off muscular, auricular, meningeal, and arteria princeps cervicis, which runs down and anastomoses with the profunda cervicis.

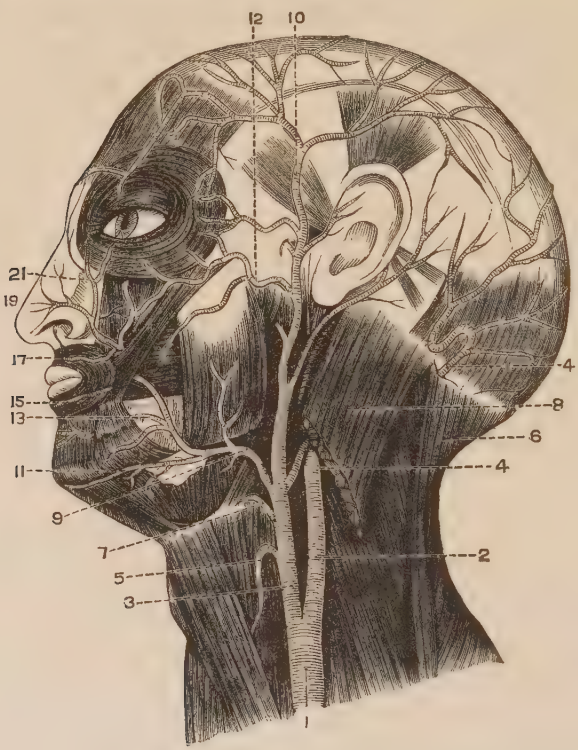

FIG. 108.—ARTERIES OF FACE AND HEAD.

1, common carotid; 2, internal carotid; 3, external carotid; 4, occipital; 5, superior thyroid; 7, lingual; 9, facial; 10, temporal; 11, submental; 12, transverse facial; 13, inferior labial; 15, 17, inferior and superior coronary; 19, lateral nasal; 21, angular.

Posterior Auricular.—Arises in parotid gland, often beneath it, and sends off stylo-mastoid and auricular.

Temporal.—Arises in the parotid gland, crosses the zygoma, and divides into the anterior and posterior terminal branches. The temporal sends off the transverse facial, anterior auricular, and middle temporal.

Internal Maxillary.—Arises in the substance of parotid gland at right angles to the temporal artery, passes behind posterior border of inferior maxillary below condyle, to be distributed to the deep structures of the face. Its branches are divided by the external pterygoid muscle into those of the first, second, and third portions. Those of the first portion are the inferior dental, middle meningeal, small meningeal, and tympanic. Those of the second part are the deep temporal and muscular. Those

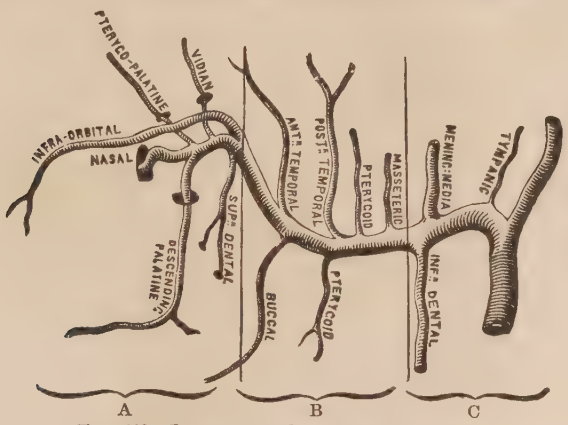

FIG. 109.—INTERNAL MAXILLARY ARTERY.
A, third portion; B, second portion; C, first portion.

from the third part, descending palatine, spheno-palatine, pterygo-palatine, Vidian, infra-orbital, alveolar.

One Ascending.

Ascending.—Arises just above the point of bifurcation of the common carotid, and sends off muscular, pharyngeal, and meningeal branches.

THE INTERNAL CAROTID ARTERY.

The internal carotid artery gives off no branches in the neck. It enters the carotid canal of the petrous part of temporal bone, makes three bends and runs forward in the cavernous groove of the sphenoid. Its

branches in the carotid canal are the tympanic,—one or two small vessels to the middle of the ear. In the cavernous groove are given off the arteriæ receptaculi, the anterior meningeal, and the ophthalmic. The ophthalmic is a large branch passing through the anterior lacerated foramen, and gives off orbital and ocular branches. The orbital branches are:—

Lachrymal.—To the lachrymal gland.

Supra-orbital.—Passes through the supra-orbital foramen.

Posterior Ethmoidal.—To ethmoidal cells.

Anterior Ethmoidal.—To ethmoidal cells.

Palpebral.—To the eyelids.

Nasal.—Anastomoses with the angular of facial.

Frontal.—To frontal region and scalp.

The ocular branches are:—

Muscular.—To orbital muscles.

Ciliary.—Long, short, and anterior to eyeball.

Arteria Centralis Retinæ.—Pierces optic nerve and supplies retina.

The cerebral branches of the internal carotid are:—

Anterior Cerebral.—Passes forward and inward and curves around the anterior portion of corpus callosum lying in the longitudinal fissure; it sends branches to the meninges.

Middle Cerebral.—Lies in the fissure of Sylvius and sends branches to the meninges.

Posterior Communicating.—Passes back to the posterior cerebral.

Anterior Choroid.—Arises external to the posterior communicating. Is distributed to the structures of the descending cornu of lateral ventricle. The two anterior cerebral arteries are connected by a short trunk called the anterior communicating.

THE THORACIC AORTA.

Begins at the left side of the lower border of the fourth dorsal vertebra; at the aortic opening it becomes the abdominal aorta. The thoracic aorta sends off the pericardiac, bronchial, posterior mediastinal, and œsophageal and ten pairs of intercostals to the lower intercostal spaces.

THE ABDOMINAL AORTA.

Commences at the aortic opening of diaphragm and divides at the lower border of the fourth lumbar vertebra into the common iliacs. It sends off:—

Phrenic.—Two or three branches to under surface of diaphragm.

Cœliac Axis.—The cœliac axis divides into three branches: 1. *Gastric*, runs along the lesser curvature of the stomach from cardiac end to pylorus. It anastomoses with the pyloric branch of the hepatic and distributes branches to both sides of the stomach. 2. *Hepatic*, passes to the liver; it gives off the pyloric, gastro-duodenalis, which divides into the pancreatico-duodenal and the gastro-epiploica dextra, and the cystic to gall-bladder. The former anastomoses with the pancreatico-duodenal of the superior mesenteric, and the latter with the gastro-epiploica sinistra of the splenic, forming the anastomoses around the greater curvature of the stomach. 3. *Splenic*, sends off branches to pancreas and the gastro-epiploica sinistra.

Superior Mesenteric.—Supplies small intestine and ascending and transverse colon. It sends off five branches: 1. Inferior pancreatico-duodenal, anastomosing with the vessel of same name from gastro-duodenalis. 2. Colica media, sending branches to the transverse and ascending colon; it anastomoses on the right with the colica dextra, on the left with ascending branch of the

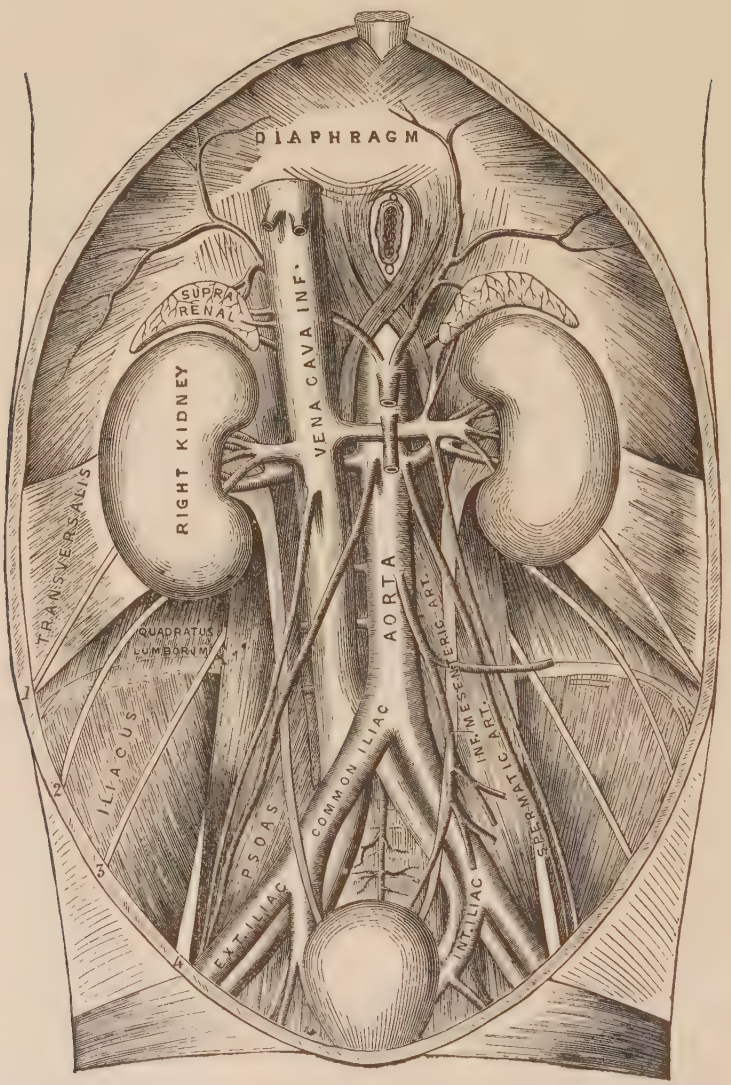

FIG. 110.—DIAGRAM OF THE COURSE AND RELATIONS OF THE ABDOMINAL AORTA AND VENA CAVA INFERIOR AND THEIR BRANCHES.
1, ilio-hypogastric nerve; 2, ilio-inguinal nerve; 3, external cutaneous nerve; 4, anterior crural nerve.

colica sinistra,—a branch of the inferior mesenteric. 3. Colica dextra, to the ascending colon, anastomosing with the colica media and ilio-colic. 4. Ilio-colic, sends

branches to the cæcum and small intestine, anastomosing with the colica dextra and vessels of the small intestine. 5. Vasa intestini tenuis, a number of branches to the small intestine. The arteries to the intestines exhibit a remarkable series of anastomoses; they are not directly distributed, but form arches and loops, and from the convexities of these the branches pass to the intestines.

Inferior Mesenteric.—Supplies the descending colon and sigmoid flexure of the rectum. It sends off three branches: 1. The colica sinistera, supplies the dscending colon and anastomoses above with the colica media, below with the sigmoid. 2. The sigmoid are several branches distributed to the sigmoid flexure of the colon. 3. The superior hæmorrhoidal, the terminal branch, anastomoses freely with the other vessels distributed to the rectum.

Supra-renal.—Are a pair of small branches which pass outward to the supra-renal capsules.

Renal.—Are a pair of large vessels coming off at right angles from the aorta and distributed to the kidneys. Each vessel subdivides into four or five branches.

Spermatic.—A pair of vessels which pass to the testes of the male. They are displaced by the ovarian in the female, and run in the inguinal canal, with the spermatic cord. In the female they are shorter and pass between the layers of the broad ligaments to the ovaries.

Lumbar.—Are four or five pairs which come off at right angles to the aorta and are distributed to the lumbar muscles.

Sacra Media.—A branch which runs down the middle of the sacrum. It is given off from the bifurcation of the abdominal aorta into the two common iliacs.

THE COMMON ILIAC ARTERIES.

The abdominal aorta, on the left side of the body of the fourth lumbar vertebra, divides into the right and left

common iliac arteries, which diverge and, after running downward for two and one-half inches, give off the internal iliacs, which supply the pelvic contents, and the external iliacs, which are the continuation of the common trunks. The common iliac arteries give off no branches.

THE INTERNAL ILIAC ARTERIES.

The internal iliac is about one and one-half inches long and divides into an anterior trunk and a posterior trunk. The anterior trunk sends off seven branches in the male and nine branches in the female:—

In the Male.

1. *Superior Vesical.*—The hypogastric artery in the fœtus carries the venous blood back to the placenta. After birth it is obliterated, that portion running to the bladder only remaining previously, and it supplies the fundus of the bladder.

2. *Middle Vesical.*—Supplies the neck of the bladder.

3. *Inferior Vesical.*—Supplies the neck of the bladder and the vesiculæ seminales.

4. *Middle Hæmorrhoidal.*—Supplies the rectum; anastomoses with the other hæmorrhoidal arteries.

5. *Obturator.*—Passes out of the pelvis by the obturator foramen; supplies the muscles in its course. It may come off with the deep epigastric.

6. *Internal Pudic.*—One of the terminal branches of the anterior trunk; passes out of the pelvis below the pyriformis, crosses the spine of the ischium, and re-enters the pelvis through the lesser sacro-sciatic foramen. It then runs along the rami of the ischium and pubes and finally divides into the dorsal artery of the penis and the artery of the bulb. The internal pudic sends off: (*a*) Inferior hæmorrhoidal, to the lower part of rectum. (*b*) Superficial perineal, to the superficial perineal struc-

tures. (*c*) Transverse perineal, to the muscles; lies on transversus perinei. (*d*) Artery of the bulb, short and thick; runs to the bulb. (*e*) Artery of the corpus cavernosum; pierces the crus penis and is distributed to it. (*f*) Dorsal artery of the penis; supplies prepuce and glans.

7. *Sciatic.*—The other terminal branch of the anterior trunk passes out of pelvis with the internal pudic. It sends off muscular branches, articular branches, and a branch to the sciatic nerve.

In the Female, in Addition.

8. *Uterine.*—Ascends at the side of the uterus between the layers of the broad ligament and is distributed to the uterus.

9. *Vaginal.*—Supplies the lower part of the vagina.

The Posterior Trunk.

The posterior trunk sends off:—

Ilio-lumbar.—Is a recurrent branch that supplies the muscles in the iliac fossa and the lumbar region.

Lateral Sacral.—Two or three branches which enter the anterior sacral foramina and anastomose with the sacra media and the arteries of the spinal canal.

Gluteal.—Passes out of the pelvis above the pyriformis and divides into a deep and superficial branch, which supplies the skin and the gluteal muscles. This vessel forms free anastomoses among its branches.

THE EXTERNAL ILIAC ARTERY.

The external iliac artery is the continuation of the common iliac, which passes beneath Poupart's ligament, and is continued down the thigh as the femoral artery. Just before it passes out of the pelvis, beneath Poupart's ligament, it sends off the

Deep Epigastric.—Runs upward and inward in the

anterior wall of the abdomen, perforates the sheath of the rectus, which it supplies, and anastomoses with the descending branch of the internal mammery. It sends off branches to spermatic cord, to the pubes, and to the muscles. Sometimes it arises in common with the obturator.

Deep Circumflex.—Runs upward and outward between the transversalis and the internal oblique, close to the crest of the ilium. It supplies the muscles of the outer and anterior part of abdomen.

THE FEMORAL ARTERY.

The femoral artery is a continuation of the external iliac. It passes beneath Poupart's ligament midway between the anterior superior spinous process and the spine of the pubes; a line drawn from this point to the inner side of the internal condyle of the femur will overlie the artery. It sends off the following branches:—

Superficial Epigastric.—Arises from the femoral artery half an inch below Poupart's ligament, passes upward and inward, and supplies the integument of the abdomen.

Superficial Circumflex Iliac.—Comes off opposite to the superficial epigastric, passes upward and outward, and is distributed to the integument of the abdomen.

Superficial External Pudic.—Supplies integument of inner side of groin, the scrotum, and integument of penis.

Deep External Pudic.—Supplies the skin of perineum and scrotum and muscles.

Profunda.—Almost as large as the femoral; it passes down deeply and sends off (*a*) the External Circumflex, supplies the structures on anterior and outer part of the thigh; (*b*) the Internal Circumflex, supplies the structures on anterior and inner part of the thigh; these ves-

sels form an anastomosis below the great trochanter of the femur; (*c*) the Three Perforating, perforate the adductor magnus.

Muscular.—To muscles of thigh.

Anastomotica Magna.—Is given off on a level with the lower third of the thigh, just before the femoral enters Hunter's canal, which is an oblique canal through the adductor magnus, close to the inner side of the femur. The anastomotica magna supplies the integument and inosculates with the recurrent tibial. As the femoral passes through the adductor magnus, it becomes the popliteal and runs down through the popliteal space.

POPLITEAL ARTERY.

The popliteal artery is the continuation of the femoral, and begins at the opening in the adductor magnus muscle. It lies deep in the popliteal space, and sends off:—

Superior External Articular.—Winds around the femur, supplies muscles, and forms free anastomoses.

Superior Internal Articular.—Winds around the femur, supplies muscles, and forms free anastomoses.

Inferior External Articular.—Winds around the tibia, supplies muscles, and forms free anastomoses.

Inferior Internal Articular.—Winds around the tibia, supplies muscles, and forms free anastomoses.

Azygos Articular.—Supplies ligaments and synovial sac of knee-joint.

Cutaneous.—Supplies skin of calf of leg.

Muscular.—Supplies muscles of popliteal region. At the lower border of the popliteal muscle the popliteal artery divides into the anterior and posterior tibial.

THE ANTERIOR TIBIAL ARTERY.

The anterior tibial artery passes through the foramen, in the upper part of the interosseous membrane, runs

along its anterior surface to the foot, where it becomes the dorsal artery. The anterior tibial sends off:—

Recurrent Tibial.—Anastomoses with the anastomotica magna and articular branches from popliteal.

Muscular.—To muscles of the anterior region of leg.

Internal Malleolar.—Supplies ankle-joint and anastomoses with the other vessels in that region.

External Malleolar.—Supplies the ankle-joint and anastomoses with the other vessels in that region.

THE DORSALIS PEDIS ARTERY.

The dorsalis pedis artery is the continuation of the anterior tibial. It forms an arch on the dorsum of the foot, and sends off:—

Tarsal.—Supplies extensor brevis digitorum.

Metatarsal.—Passes across foot and gives off three interosseous.

The Interosseous.—Supply the contiguous sides of the dorsal aspect of the toes.

The Communicating.—Perforate interosseous structures and communicate with the plantar.

Dorsalis Pollicis.—Supplies great toe and second toe.

THE POSTERIOR TIBIAL ARTERY.

The posterior tibial artery begins at the lower border of the popliteus muscle, and passes down the leg between the superficial and deep groups of muscles; it then passes behind the internal malleolus, into the sole of the foot. The posterior tibial sends off:—

Muscular.—To the muscles of leg.

Nutrient.—To tibia; this is the largest nutrient artery to any bone.

Communicating.—Passes between posterior tibial and peroneal muscles.

Internal.—Two or three vessels to inner side of heel.

Peroneal.—Arises an inch below origin of posterior tibial artery. It is almost as large as the posterior tibial, and runs down between the superficial and deep group of muscles to the fibular side of the leg. Its branches are the muscular and the nutrient to the fibula. The posterior tibial becomes the plantar artery, which divides into the internal plantar and the external. The internal is small, and supplies the inner side of the foot. The external plantar is large, runs outward to the base of the fifth metatarsal, then curves deeply inward, forming the plantar arch, which is completed by a communicating branch from the dorsalis pedis. The external plantar sends off (*a*) the Perforating, which anastomoses with the dorsalis pedis; (*b*) the Digital, four or five vessels to the toes. Each branch runs forward to the web of the toe, then divides into two branches, which are distributed to the adjoining sides of the toes.

THE PULMONARY ARTERY.

The pulmonary artery, about two inches long, arises from the right ventricle, and carries venous blood to the lungs. It divides into the right and left pulmonary, which pass to the right and left lungs respectively, then divide and subdivide, and finally form plexuses or anastomoses, reticular in character, around the air-cells; they are so arranged that the diameter of the mesh is less than the diameter of the capillary. The pulmonary capillaries are exquisitely delicate, and consist of a single layer of endothelial cells jointed together by an albuminoid cement-substance.

VEINS.

The systemic veins are vessels which carry the venous blood to the heart. They begin in the capillaries, gradually increase in size, and terminate in the ascending and

descending venæ cavæ, which empty into the right auricle. The pulmonary veins, four in number, convey oxygenated blood from the lungs to the left auricle. Veins, like arteries, have three coats. The outer or areolar, the middle or muscular or fibrous, and the inner or epithelial. These coats are relatively thinner than in the arteries; so that a vein, when cut across, will collapse, while an artery remains patulous and cylindrical. Veins intercommunicate freely and often form large plexuses. All veins, with the few exceptions of those in which the blood gravitates to the heart, when the subject is in the erect posture, are supplied with valves, the positions of which can be distinguished on the exterior of the vein by slight constrictions. The area of the venous system is estimated to be two and one-half times as much as the arterial system, owing to the larger size of the veins and the greater number of the venous radicles. In general the veins are erratic in distribution, and anomalies are constantly met with. The smaller arteries, as a rule, have two accompanying veins called the venæ comites; the larger arterial trunks, as the popliteal, femoral, axillary, and subclavian, have but one vein. The veins of the cranium are called sinuses; of these there are two kinds,—those which run in the substance of the bone and those which are formed by a separation of the leaflets of the dura mater.

The veins are classified into those of the head, neck, upper extremities, trunk, and lower extremities. Those of the head and of the neck are the superficial and deep. The superficial set are temporal, facial, internal maxillary, posterior auricular, occipital, and temporo-maxillary. These veins follow the course of the arteries; they freely communicate with each other, and at the angle of the lower jaw unite with more or less regularity, to form

the external jugular. The facial generally empties into the internal jugular.

THE VEINS OF THE NECK.

External Jugular.—Begins in the substance of the parotid gland, runs down the neck from the angle of the inferior maxillary to the middle of the clavicle, and empties into the subclavian.

Posterior External Jugular.—Empties into the external jugular about its middle; comes from posterior part of the neck.

Anterior Jugular.—Formed by the submaxillary veins, passes down the anterior part of the neck, and empties into either the external jugular or subclavian.

Internal Jugular.—Begins at the posterior lacerated foramen, and is the continuation of the great lateral sinus of the brain. It runs deeply down the neck to the outer side of the carotid, and empties into the subclavian to make the innominate.

Vertebral.—Runs down the spine beside the vertebral artery and empties into the innominate.

The deep veins of the head are diploic sinuses, canals in the diploic substance of the cranial bones. The veins in these canals adhere to the walls and remain open on section. The sinuses of the dura mater are a simple separation of the layers of the dura mater, and are lined by endothelium. They are:—

Superior Longitudinal.—Begins at the foramen cæcum, in front of the cristi galli. It runs along the median line of the skull to the internal occipital protuberance, where it divides into the two lateral; the point of division is called the torcular Herophili.

Inferior Longitudinal.—Along the free border of the falx cerebri; terminates posteriorly in the straight sinus.

Straight.—Is the continuation backward of the

inferior longitudinal along the median line of the upper surface of the tentorium cerebelli; it empties into the superior longitudinal.

Lateral.—Formed by the division of the superior longitudinal. Pass horizontally outward on the horizontal grooves of the occipital cross, then curve down behind

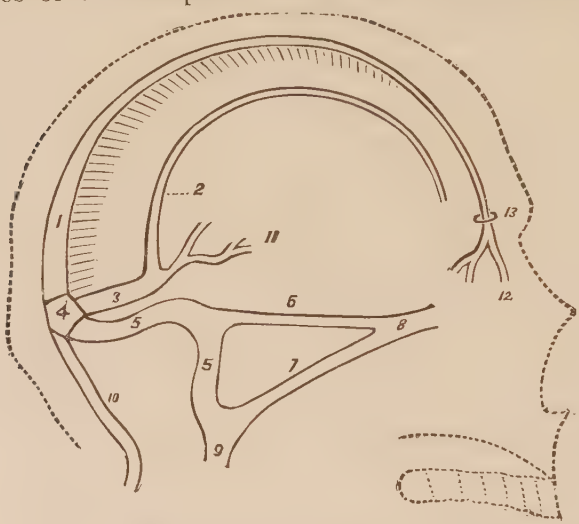

FIG. 111.—DIAGRAM SHOWING THE CEREBRAL SINUSES IN PROFILE.

1, superior longitudinal sinus; 2, inferior longitudinal sinus; 3, straight sinus, deriving blood from 1 and also from the veins of Galèn (11); Nos. 1, 2, and 3 bound the falx cerebri; 4, the torcular Herophili, where four sinuses meet; 5, lateral sinus; 6, superior petrosal sinus, joining the lateral sinus (5) with the cavernous sinus (8); 7, inferior petrosal sinus, joining the cavernous sinus (8) with the jugular vein (9); 8, cavernous sinus; 9, internal jugular vein formed by two sinuses (5 and 7); 10, occipital sinus; 11, venæ Galeni; 12, vein passing to nasal cavity; 13, foramen cæcum.

the petrous bone, and terminate at the posterior lacerated foramina.

Occipital.—Two small sinuses from the sides of the foramen magnum; they empty into the lateral sinuses near the point of their communication with the superior longitudinal.

Cavernous.—Consists of a series of cells opening into one another; lies in the cavernous groove at the side of the body of the sphenoid. It drains the orbit, receiving the ophthalmic vein.

Pituitary, or Circular.—Encircles the sella turcica. It connects the cavernous sinuses.

Transverse.—Connects the two great petrosal sinuses. It is placed at the articulation of the os planum of the sphenoid with the basilar process of the occipital.

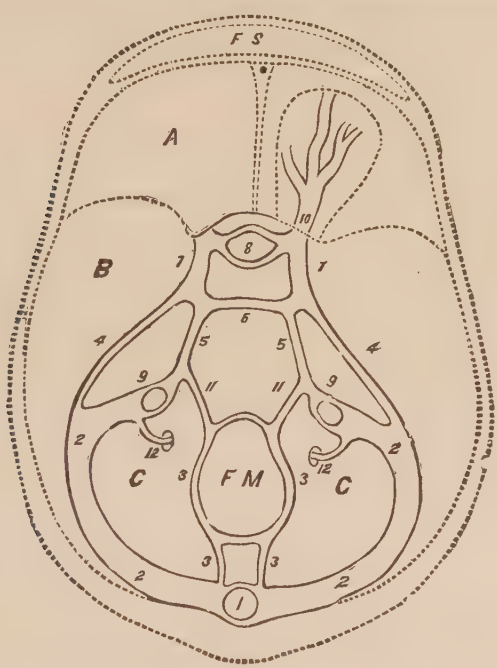

FIG. 112.—DIAGRAM SHOWING THE VENOUS SINUSES OF THE DURA MATER.

A, anterior fossa of skull; B, middle fossa; C, posterior fossa; FS, frontal sinus; 1, torcular Herophili; 2, 2, lateral sinuses; 3, 3, occipital sinuses; 4, 4, superior petrosal sinuses; 5, 5, inferior petrosal sinuses; 6, transverse sinus; 7, 7, cavernous sinuses; 8, circular sinus, 9, opening into internal jugular vein; 10, ophthalmic vein, communicating with cavernous sinus (7); 11, a branch joining the occipital and inferior petrosal sinuses; 12, veins from posterior condyloid foramen to lateral sinus.

Great Petrosal.—Is the continuation backward of the cavernous sinus. It lies in the suture between the petrous part of temporal and the side of the basilar process.

Lesser Petrosal.—Lies in the superior border of the petrous part of temporal and connects the lateral and the cavernous sinuses.

VEINS OF THE UPPER EXTREMITY.

The veins of the upper extremity are superficial and deep. The superficial run in the superficial fascia; are, therefore, subcutaneous, and can be seen as bluish, compressible, linear elevations. The superficial veins are:—

Median.—Formed by the union of small veins on the anterior part of forearm. It runs toward the elbow, bifurcates Y-like, and sends one branch to the basilic and the other to the cephalic.

Ulnar.—Three or four veins which drain the ulnar side of the forearm; it becomes a single trunk, receives the branch from the median, and continues deeply up the arm as the basilic.

Radial.—Drains the radial side of forearm; at the bend of the elbow it receives the branch from the median, and continues up the arm as the cephalic.

Medio-basilic.—The short branch from the basilic to the median. It is crossed by the internal cutaneous nerves, and lies on the brachial artery.

Medio-cephalic.—The other short terminal branch of the median to the cephalic. It is the vein ordinarily selected for phlebotomy.

Cephalic.—Is the continuation of the radial and medio-cephalic. It passes up the outer side of the arm, lies in the groove between the deltoid and pectoralis major, and empties into the axillary.

Basilic.—Formed by the union of the ulnar with the medio-basilic, runs up the inner side of arm, pierces the deep fascia, and empties either into the vena comites of the brachial artery or into the axillary vein.

The deep veins are:—

Vena Comites.—Two veins to each artery; as a rule, one at each side.

Axillary.—The continuation upward of the basilic.

It receives the vena comites and cephalic. At the lower border of the first rib it becomes the

Subclavian.—The large venous trunk which lies anterior to the subclavian artery. It begins at the lower border of the first rib and unites behind the sterno-clavicular articulation with the internal jugular, forming the innominate. It drains the superficial veins of the neck.

VEINS OF THE LOWER EXTREMITY.

Veins of the lower extremity are superficial and deep; the superficial are:—

Long Saphenous.—Begins by a venous arch on the foot, passes up the inner side of the leg, and gradually increases in size. It receives the superficial veins of the lower extremity, passes through the saphenous opening of the fascia lata, and terminates in the femoral.

Short Saphenous.—Begins at the outer side of the foot, runs up the back part of leg, and empties into the popliteal vein.

The arteries of the leg have *vena comites*, which unite at the lower part of the popliteal space and form the

Popliteal Vein.—Receives the deep veins of the leg and knee-joint, runs up to the canal in the adductor magnus muscle, and becomes the

Femoral.—The femoral accompanies the femoral artery. It receives two important tributaries,—the long saphenous and profunda femoris veins.

THE VEINS OF THE TRUNK.

External Iliac.—The continuation of the femoral passes beneath Poupart's ligament, joins the internal iliac, and forms the common iliac vein. It receives the deep epigastric and deep circumflex iliac veins.

Internal Iliac.—Made up of the vena comites of the

gluteal, sciatic, internal pudic, obturator, and other veins which accompany the branches of the internal iliac artery. It also drains the venous plexuses of the pelvis, as the prostatic and hæmorrhoidal. In the female it drains the vesical, vaginal, uterine, and rectal plexuses. The hæmorrhoidal plexus is formed by the anastomoses of the superior middle and inferior hæmorrhoidal veins. This plexus is also drained by the inferior and superior mesenteric veins, which terminate in the portal vein. *The dorsal vein* of the penis consists of two branches which drain the blood from the organ. These two branches unite, form a single trunk, which pierces the suspensory ligament of the penis and the triangular ligament, and empties into the prostatic plexus. *The prostatic plexus* surrounds the neck of the bladder. *The vaginal plexus*, largely composed of erectile tissue, surrounds the lower portion of the vagina. *The uterine plexuses* are at the superior angles and sides of the uterus; they drain the uterine sinuses.

The common iliac veins are formed by the union of the external and internal iliacs, and unite to the right of the fourth lumbar vertebra to form the ascending vena cava. *The vena cava ascendens* passes upward along the right side of the vertebral column, lies in the fissure in the posterior border of the liver, passes through the quadrate opening of the diaphragm, and enters the posterior and inferior portion of the right auricle. Its tributaries are the lumbar veins, the right spermatic, renal, supra-renal, phrenic, and hepatic. The lumbar consists of three or four pairs of veins that drain the structures in the lumbar regions. The spermatic veins arise in the spermatic or pampiniform plexus, at the posterior part of the testicle; they pass through the inguinal canal; the right empties into the ascending vena

cava, the left into the left renal vein. The left spermatic has comparatively few valves. The renal veins return the blood from the kidneys; the supra-renal from the supra-renal capsules.

The portal vein is formed by the superior and inferior mesenteric, the gastric, and splenic. It drains the intestinal tract, enters the liver, breaks up into a system of capillaries, which become confluent, and finally terminate in three hepatic, which empty into the ascending vena cava. At the transverse fissure of the liver the portal vein divides into a right and left branch, which give off the vaginal branches; these send off the interlobular; and the branches of the interlobular are the lobular, which are the smallest branches of the portal system. They pass through the lobule, empty into the central or intra-lobular vein, which empties into the sublobular; these open into the small hepatic, which, by joining together, form the three or five hepatic veins that empty into the ascending vena cava as it lies in the posterior fissure of the liver. The innominate veins, two in number, are formed by the union of the internal jugular and the subclavian of each side. The right is shorter than the left, and joins the left innominate behind the costal cartilage of the first rib on the right side, forming the descending vena cava. The innominate veins receive the internal mammary, inferior thyroid, and superior intercostal veins.

The descending or superior vena cava, formed by the union of the two innominates, is about three inches long, and terminates in the superior posterior part of the right auricle. The superior vena cava receives the vena azygos major, which runs along the right side of the bodies of the dorsal vertebræ and receives the vena azygos minor and the intercostal veins. The veins of

the spine freely communicate with one another; they are very abundant, and are divided into the veins of the cord, those of the bodies of the vertebræ, those of the meninges of the cord, and the external veins.

LYMPHATICS.

Lymphatics, or absorbent vessels, are found in all the tissues of the body except the cartilage, epidermic structures, cornea, and white matter of the brain and cord. They are delicate, transparent vessels, and have three coats,—an outer areolar, middle fibro-muscular, and inner epithelial. They are abundantly supplied with valves. The origin of the lymphatic vessels has been an open question. Most probably they begin in intercellular spaces, which, by communicating, become lymph-sinuses. These sinuses are lined by cells at first irregularly placed, then pavement in character, showing, however, here and there openings between the cells called the stomata. These minute capillaries communicate freely, forming a plexiform anastomosis, from which the lymphatic vessel proper starts. Scattered along the course of the lymphatics are a great number of ovoidal solid bodies, varying in size from a small pea to an almond. These are the lymphatic glands. On section they are seen to be formed of, first, an outer, fibrous capsule, which sends inward a number of septa that divide the gland into alveoli, which constitute the cortical portion. It is light in color and deficient at the hilum, a linear depression at one part of the gland, at which the blood-vessels enter and pass out. The medullary portion is dark in color and granular in appearance. The lymphatic that leaves the gland is called the efferent. It passes out through the hilum, and is connected with the medullary portion. The afferent vessels, those which

run to the gland, penetrate the cortical portion at all points. The alveoli of the cortical portion are filled up with interlacing fibres from the septa, forming a plexiform net-work, and called the alveoli of the alveoli, or secondary alveoli. They are filled up with lymphoid corpuscles,—the proper lymph-gland pulp. The medullary portion is formed of delicate trabeculæ, vessels and cells. The lymphatics are divided into the superficial and deep. The former run in the superficial fascia; the latter accompany the large blood-vessels. Lymphatics are classified into those, first, of the head and neck; second, of the upper extremity; third, of the trunk; fourth, of the lower extremity.

LYMPHATICS OF THE HEAD AND NECK.

The lymphatics of the head and neck run in the superficial fascia and converge about the angle of the jaw, where a number of lymphatic glands are found about the course of the vessels. The deep lymphatics from the nose and mouth communicate with the deep lymphatic glands at the sides of the internal jugular vein. The lymphatics of the cranium pass out through the foramina at the base of the skull and enter the deep lymphatic glands. The lymphatics of the neck are divided into the superficial and deep. The former run in the superficial fascia, from the angle of the jaw to the middle of the clavicle. Just above the clavicle numerous glands are found in the groove between the trapezius and the sterno-mastoid. The deep lymphatics of the neck accompany the carotid artery. They consist of a chain of six or eight glands.

LYMPHATICS OF THE UPPER EXTREMITY.

The lymphatics of the upper extremity are divided into the superficial and deep. The former run in the super-

ficial fascia. At the bend of the elbow, above the internal epicondyle, are two or three glands, which are apt to enlarge after injury or disease of the hand and arm. In the axilla both the deep and superficial sets of lymphatics join and communicate freely with lymphatic glands placed upon the course of the vessels. The lymphatics of the upper extremity empty on the right side into the

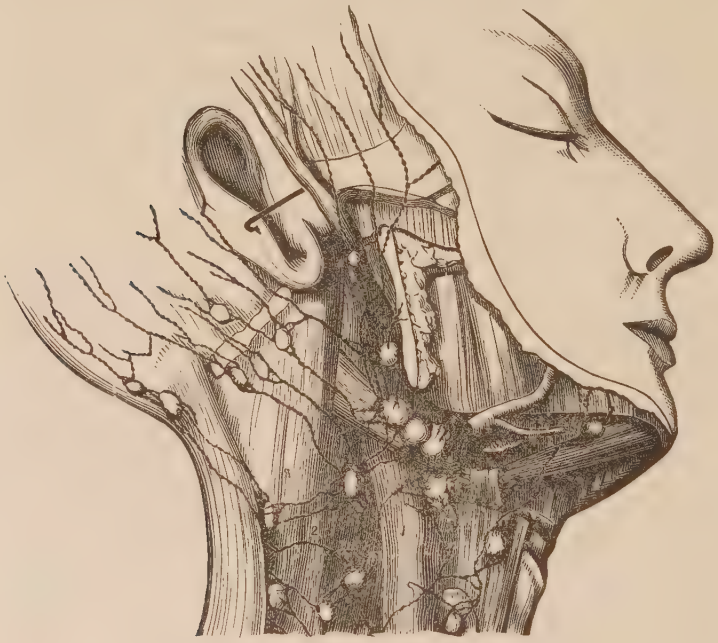

FIG. 113.—LYMPHATICS OF HEAD AND NECK.
1, internal jugular vein; 2, deep cervical glands.

right lymphatic duct; on the left side, into the thoracic duct.

LYMPHATICS OF THE TRUNK.

The glands of the thorax are the anterior and posterior mediastinal. The former are anterior to the pericardium, and lie in the loose areolar tissue above the diaphragm. The posterior mediastinal consist of a

chain of glands at the sides of the aorta. The lymphatic vessels are abundant, and freely communicate with the adjoining glands. The bronchial glands cluster around the bifurcation of the trachea and communicate with the mediastinal. The lymphatics of the heart accompany the blood-vessels. They terminate in a plexus around the aorta, and ultimately enter the thoracic duct. The other glands and lymphatics of the chest are found on the œsophagus, and also following the blood-vessels. They are such as the intercostals and internal mammary. *The right lymphatic duct* is a short trunk, about one-tenth of an inch in diameter; it runs for about one and one-half inches, and terminates at the junction of the right subclavian and internal jugular veins. It receives the lymphatics of the right side of the head and neck, right upper extremity, right chest and contents. *The thoracic duct* is the great lymph-channel of the body. It receives the lymph from all parts of the body except those which communicate with the right lymphatic duct. It is three-sixteenths of an inch in diameter and about twenty inches long, and passes from in front of the second lumbar vertebra to the left subclavian vein, into which it empties. Its lower end is sacculated, about two inches long, three-eighths of an inch in diameter, and is called the receptaculum chyli. It receives the lumbar lymphatics and the trunks of the lacteals, which are the lymphatics of the intestines. It passes into the thoracic cavity through the aortic opening, receives the lymphatics of the left side of the chest and contents, runs along the left side of the vertebral column, and empties into the left subclavian vein near its junction with the internal jugular vein. The lymphatics of the small intestine are called the lacteals. After the digestion of food they are filled with chyle, and appear as white streaks running through

the mesentery. They begin in a plexiform arrangement in the villi of the intestines, unite to form two or three

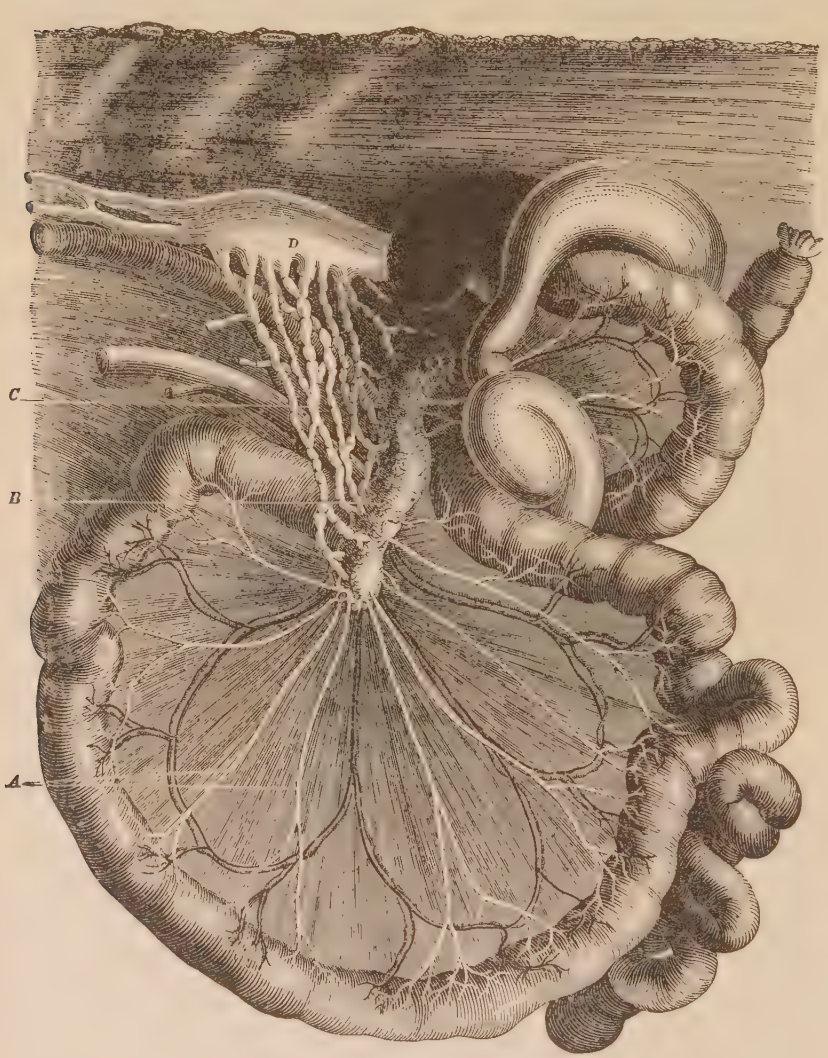

FIG. 114.—LACTEALS DURING INTESTINAL DIGESTION.
A, lacteals of mesentery; B, mesenteric glands; C, efferent chyle-ducts; D, receptaculum chyli.

large trunks, and empty into the thoracic duct. They run between the layers of the mesentery and communi-

cate with the mesenteric glands, which are very numerous. The pelvic lymphatic system consists of three sets of deep layers of lymphatics and glands,—the external iliac, internal iliac, and the sacral. They are formed of chains of glands connected by the lymphatic vessels. The superficial lymphatics of the perineum, scrotum, and penis communicate with the inguinal chain of lymphatics placed over and above Poupart's ligament. The lymphatics of the clitoris and nymphæ are similarly arranged.

LYMPHATICS OF THE LOWER EXTREMITY.

The lymphatics of the lower extremity are divided into the superficial and deep. The superficial lymphatics run in the superficial fascia and accompany the internal saphenous vein. They communicate with the inguinal glands, which are grouped about the saphenous opening and lie below Poupart's ligament. These inguinal glands also communicate with the lymphatics from the side of the penis and scrotum. The superficial lymphatics of the gluteal region accompany the arteries and communicate with the pelvic glands. The deep lymphatics communicate with the glands of the popliteal space and accompany the femoral vein, and enter the pelvic and lumbar glands.

THE NERVOUS SYSTEM.

NERVOUS TISSUE.

NERVOUS tissue is of two kinds,—gray or vesicular, and white or fibrous. These two kinds of tissue, associated in varying amounts and positions, form the essential

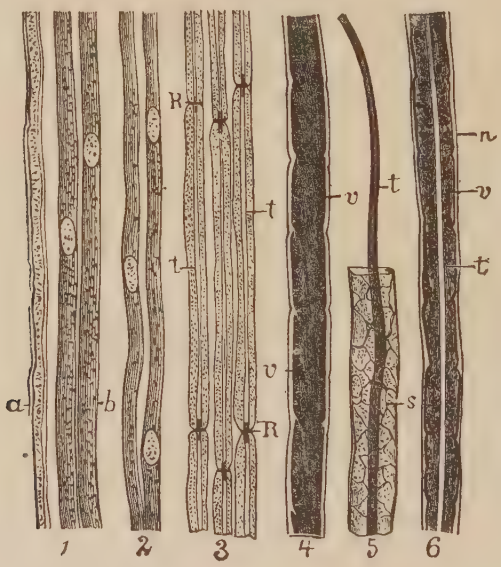

FIG. 115.—NERVE-FIBRES.

1, a, medullated nerve-fibre; b, non-medullated nerve-fibre; 2, non-medullated nerve-fibre; 3, nerve-fibres with Ranvier's nodes; 4, nerve-fibre treated with osmic acid; 5, nerve-fibre showing axis-cylinder; 6, nerve-fibre showing n, neurilemma; v, medullary sheath; t, axis-cylinder.

elements of the nervous system, which is divided into two great systems,—the cerebro-spinal and the sympathetic. The cerebro-spinal axis is contained within the cranium and spinal canal, and sends out a number of pairs of nerves that bring the several parts of the body into close connection with the central axis. The sympathetic sys-

tem consists of a chain of ganglia on each side of the spinal column, connected with each other and with the cerebro-spinal axis. It is the system of organic life, and hence controls the development, growth, and nutrition

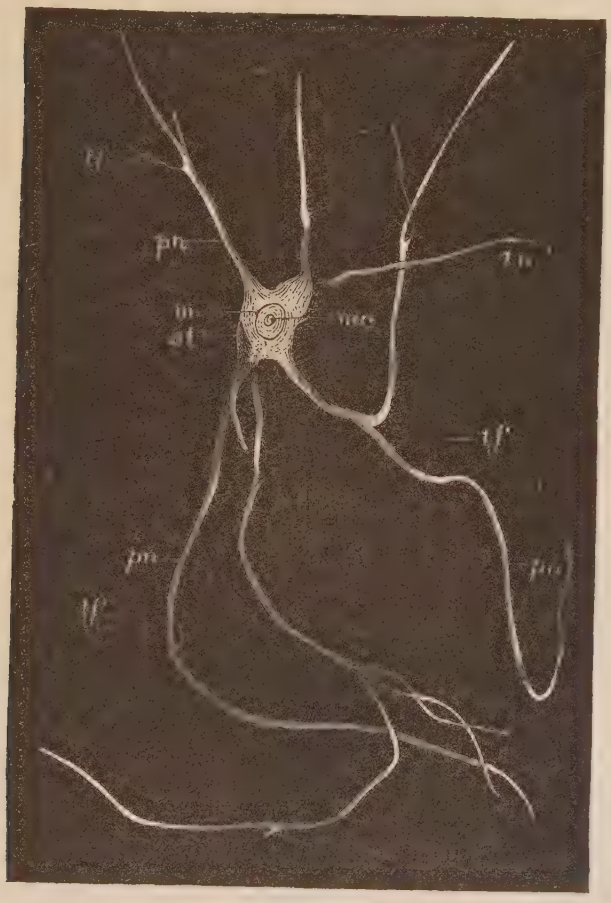

FIG. 116.—GANGLIONIC CELL AND BRANCHING FIBRES.
st, cell body; m, nucleus; mc, nucleolus; pn, protoplasmic prolongations; tf, axis-cylinder fibres; tn, axis-cylinder prolongations.

of the body, while the cerebro-spinal system is the system of animal life and brings the individual into relations with the exterior world through his special senses and the operations of his reason and will.

The gray or vesicular matter consists of vesicles or cells, which vary in size from $\frac{1}{3000}$ to $\frac{1}{300}$ inch in diameter. They are globular, with one, two, or more

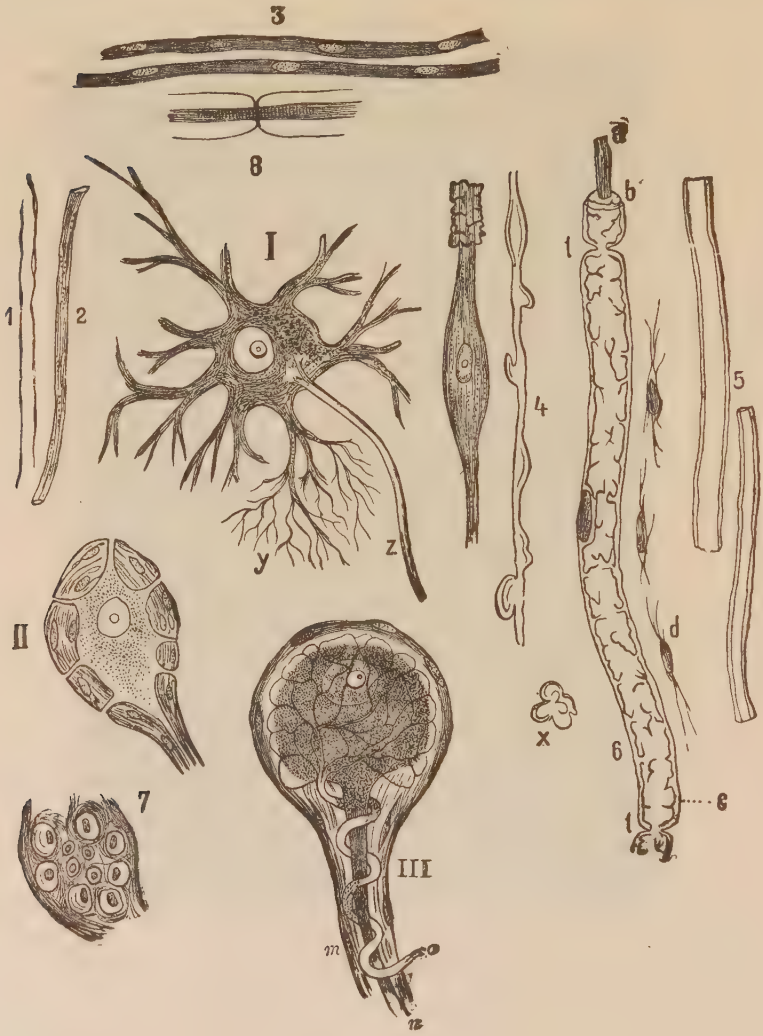

FIG. 117.—STRUCTURE OF NERVE-ELEMENTS.

1, primitive fibrilla; 2, axis-cylinder: 3, Remak's fibres; 4, medullated varicose fibre; 5, 6, medullated fibre, with Schwann's sheath; C, neurilemma; t, t, Ranvier's nodes; b, white substance of Schwann; d, cells of the endoneurium: a, axis-cylinder; x, myelin drops; 7, transverse section of nerve-fibre: 8, nerve-fibre acted on with silver nitrate: I, multipolar nerve-cell from spinal cord; z, axial cylinder process; y, protoplasmic processes —to the right of it a bipolar cell; II, peripheral ganglionic cell, with a connective-tissue capsule; III, ganglionic cell, with *o*, a spiral, and *n*, straight process; *m*, sheath.

branched processes called poles. A cell consists of a granular protoplasm, sometimes slightly pigmented. They contain a distinct, large, and clear nucleus which contains one or two nucleoli.

A cell-wall can at times be distinctly demonstrated and probably always exists. In the cortex of the brain the cells are sustained by a delicate, retiform, connective tissue called the neuroglia.

In the ganglia, which are collections of nerve-cells along the course of the white fibres,—in fact, diminutive centres, —the cells are sustained by the neuroglia and surrounded by a distinct fibrous capsule. The white fibrous nerve-tissue forms the greater part of the nervous system. It consists of fibres which continue uninterruptedly from the centre to their distribution. They neither inosculate nor anastomose. Each fibre consists of a central conducting fibre, the axis-cylinder; an insulating material, the white substance of Schwann; and an investing sheath, the tubular membrane.

The entire fibre is about $\frac{1}{1000}$ inch in diameter; the axis-cylinder, about $\frac{1}{2500}$ inch. The fibre and its component parts vary, however, in size, both absolutely and relatively. The tubular sheath is very delicate, homogeneous, and is formed by the condensation of the white substance of Schwann. In addition to the complete medullated fibre, consisting of axis-cylinder, white substance of Schwann, and tubular membrane, fibres are found which consist only of the axis-cylinder and tubular membrane or the axis-cylinder alone. The fibres of Remak are naked axis-cylinders, much smaller than the axis-cylinder as ordinarily met with. Such fibres are found largely in the sympathetic system. The axis-cylinder consists of very minute fibrillæ. The white substance of Schwann consists of albuminous and fatty matter.

THE BRAIN.

The brain is the organ of the intellect and will. It consists of four parts,—the cerebrum, cerebellum, pons Varolii, and the medulla oblongata,—and is contained within the cavity of the cranium. The brain weighs, in the adult male, about fifty ounces; in the adult female, about forty-five ounces. It increases in weight up to the

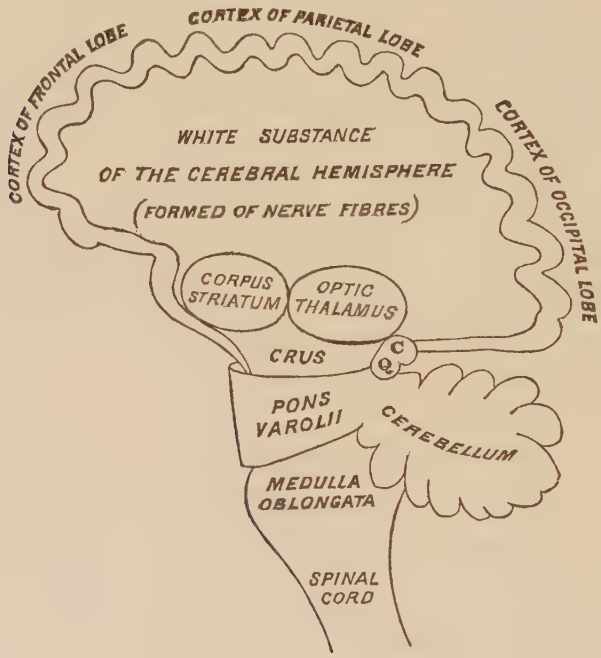

FIG. 118.—DIAGRAM OF BRAIN.

fortieth year. After the sixtieth year it generally decreases, it is estimated, to the extent of an ounce to an ounce and a half in each decade. The brain of the human species is heavier than the brain of any other creature except in the elephant and the whale. The brain of the elephant weighs about eight pounds.

In comparison with the bulk of the body, the brain of some birds and small vertebrates is relatively larger

than the brain of man; but, in comparison with the size of the nerves which come from the base, the human brain is larger than any other. The proportions of the gray to the white matter of the brain in man is relatively many times greater than in any other creature; and, as the gray or vesicular matter is the generator of nerve-force, whether expressed in mind, action, or in thought, it indicates the immense superiority of the human brain. The brain of the new-born male infant weighs about twelve ounces; that of the female, about ten ounces. It increases rapidly in weight and size up to the seventh year, slowly up to the twentieth, and continues to increase in weight up to the fortieth year. The weight of the cerebrum alone is forty-four ounces, the cerebellum five ounces, the medulla and pons one ounce. The relation of the weight of the cerebellum to the cerebrum is about as 1 to 8½. The specific gravity of the brain entire is 1036, the white matter being a trifle the heavier. The brain differs in weight and development in the different races, being greatest in the Xanthochroi, the highest types of the white race, and least in the Negroids of New Caledonia. As a general rule, the greater the development and weight of the brain, the greater the intellectual capacity of the individual. In examining the tables of brain-weights of celebrated men, they indicate an average in excess of the general average weight, thus:—

Cromwell, ...	weight,	82	ounces.
Byron, ...	"	79	"
Cuvier, ...	"	64	"
Abercrombie, . . .	"	63	"
Spurzheim, . . .	"	55	"
Agassiz, ...	"	53½	"
Webster, ...	"	53½	"

On the other hand, a brain-weight in the white adult of less than thirty-five ounces is generally asso-

ciated with idiocy, more or less profound. In the lowest types of mankind a brain-weight of thirty-five ounces is but little below the normal, and consistent with the ordinary mental phenomena of that class. Intellection, in its most exalted expressions, depends also upon the arrangement and development of the gray matter of the brain.

The brain is enveloped by three membranes,—the outer, the dura mater; the middle, the arachnoid; and the inner, the pia mater.

THE DURA MATER.

The dura mater is composed of white, fibrous tissue. It is thick, dense and strong, and forms the endosteum of the cranium. It sends down processes from its under surface to support the brain. Two of these are of great importance: the falx cerebri and the tentorium cerebelli. The falx consists of a vertical, sickle-shaped process, which hangs down from the inner surface of the dura mater along the median line. It is narrow in front, attached to the crista galli, becomes gradually broader, and is attached to the upper surface of the tentorium cerebelli. Along the median line, at the junction of the falx and the dura mater, is the great longitudinal or superior longitudinal sinus, and along the inferior free edge of the falx is the inferior longitudinal sinus. The straight sinus is at the junction of the falx with the tentorium cerebelli. The tentorium cerebelli is a thin, dome-shaped process of dura mater, which projects horizontally forward from that part of the dura mater which is attached to the horizontal limb of the occipital cross. Along the line of its attachment to the dura mater are the lateral sinuses. It is attached anteriorly to the superior border of the petrous part of the temporal bone, inclosing the superior petrosal sinuses, and to the posterior clinoid

processes of the sphenoid. Attached along the median line of its superior surface, nearly at right angles, is the falx cerebri. The inferior surface of the tentorium is concave, and gives attachment to the falx cerebelli, which corresponds to the falx cerebri, but which is comparatively slightly developed. The dura mater also sends tubular prolongations or sheaths around the filaments

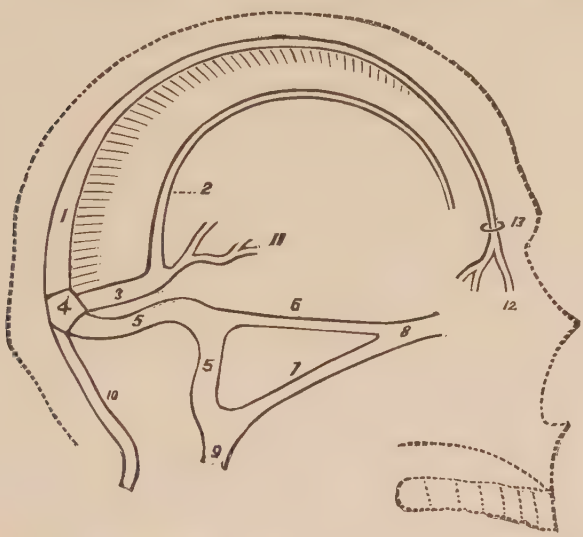

FIG. 119.—THE SINUSES OF THE DURA MATER.

1, superior longitudinal sinus; 2, inferior longitudinal sinus; 3, straight sinus, deriving blood from 1 and also from the veins of Galen (11); Nos. 1, 2, and 3 bound the falx cerebri; 4, the torcular Herophili, where four sinuses meet; 5, lateral sinus; 6, superior petrosal sinus, joining the lateral sinus (5) with the cavernous sinus (8); 7, inferior petrosal sinus, joining the cavernous sinus (8) with the jugular vein (9); 8, cavernous sinus; 9, internal jugular vein formed by two sinuses (5 and 7); 10, occipital sinus; 11, venæ Galeni; 12, vein passing to nasal cavity; 13, foramen cæcum.

of the olfactory, optic, ophthalmic division of the fifth nerves as they pass out of the skull. On the surface of the dura mater are a number of fibrous, split-pea-shaped bodies called the Pacchionian bodies. Arteries are freely distributed to the dura mater.

THE ARACHNOID.

The arachnoid is a serous sac consisting of two layers, —visceral and parietal. The parietal layer lines the inner

surface of the dura mater. Its fibrous structure is but faintly developed, and it adheres intimately to the inner surface of the dura mater. Its visceral layer adheres loosely to the brain, passing from convolution to convolution without dipping down between them. These views are at variance with those now ordinarily received, which deny the existence of the arachnoid as a distinct serous sac. Embryologically, however, the arachnoid exists as such. In young dogs its fibrous and epithelial elements are strongly developed, and leave no question as to its classification among the serous membranes. The space between the two layers of the arachnoid is called the cavity of the arachnoid. The arachnoid is thin and delicate over the convexity of the brain; thicker at the base, where it is separated from the pia mater forming the subarachnoid space. The subarachnoid space contains a varying amount of clear, watery fluid, which consists of 98.5 water and 1.5 parts of solids. As the subarachnoid space communicates with the ventricles of the brain, the office of this fluid is probably to support the ventricular walls and to modify the force of concussions transmitted to the brain.

THE PIA MATER.

The pia mater is a vascular membrane, which closely invests the brain. It is composed of loose connective tissue, containing elastic fibres and supporting plexuses of blood-vessels. It passes through the transverse fissure, and forms the velum interpositum of the third ventricle and the choroid plexuses of the lateral and fourth ventricles. Its outer surface is covered by the visceral layer of the arachnoid. The surface applied to the brain exhibits numerous vessels that come off to pass to the cortical portion of the brain, and, if immersed in water,

give to the under surface of the pia mater a woolly appearance.

THE CEREBRUM.

The cerebrum, arranged in two hemispheres,—the right and the left,—constitutes the great mass of the brain, weighing about seven and a half times as much as the combined weights of the cerebellum, pons, and the medulla. The two hemispheres are divided by a deep fissure, the longitudinal, which lodges the falx cerebri, connected by a great transverse commissure, the corpus callosum. Each hemisphere presents for examination an outer, convex, convoluted surface; an inner, vertical, flat, convoluted surface; and an irregular base. On the outer surface of the brain are a number of rounded elevations, disposed in a linear manner. They are called the convolutions, and are separated by sulci or depressions.

A convolution is an elevation of the cortical layer of the brain, caused by overgrowth. In the fœtus the convolutions are indicated by slightly-marked linear elevations, separated by faint depressions,—the future sulci. The cortex develops and grows with increasing rapidity, and puckers up over the subcortical stem of white matter, forming the folds or convolutions of the cortex. The convolutions are not strictly alike in both hemispheres of the brain. Certain ones are more or less perfectly and symmetrically developed. These are designated primary convolutions. They are generally disposed obliquely, ascending from below upward and backward. Each convolution is about an inch high, rounded and slightly flattened on the summit. A vertical section shows it to be narrower below, where it is attached to the subcortical stem, broader and slightly clubbed near the summit. Microscopically it is seen

to be composed of from three to seven layers of gray or vesicular matter, between which pass communicating and commissural axis-cylinders. Through the middle of the convolution pass the fibres of the corona radiata of the subcortical white matter. The entire thickness of the cortical matter varies in different brains and in the different parts of the same brain. Its average is about three-sixteenths of an inch.

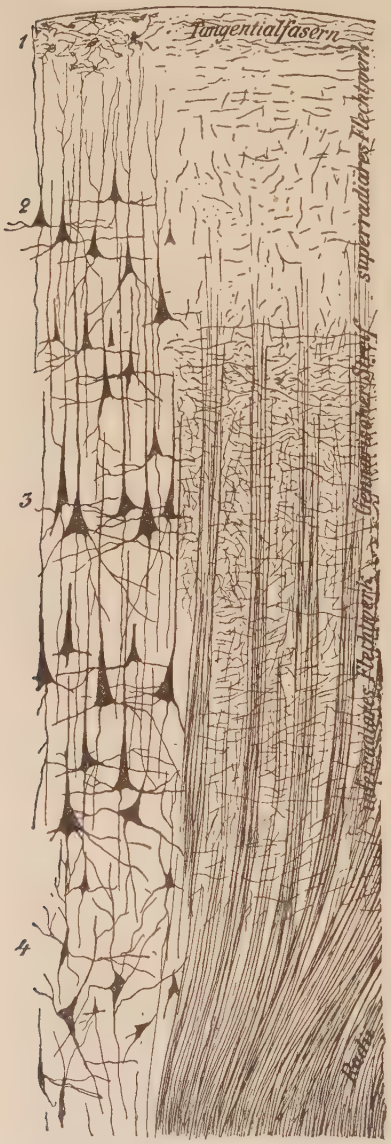

FIG. 120.—SECTION THROUGH THE CORTEX OF A FRONTAL CONVOLUTION.

The convolutions of each hemisphere are divided into primary and secondary. The primary are twenty-eight in number; the secondary vary both in number and position, being principally annectant.

The outer surface of each hemisphere is divided into four regions or lobes,—frontal, parietal, occipital, and the temporo-sphenoidal,—so named after the bones which overlie them, but with

which they are not coterminous. Thus, the frontal lobe extends an inch and a half behind the coronal suture; the occipital lobe passes forward for three-fourths inch in front of the lambdoidal suture. The parietal bone covers the parietal lobe or region, and part of the occipital, frontal, and temporo-sphenoidal lobes. The primary

FIG. 121.—LEFT SIDE OF HUMAN BRAIN.

F, frontal, P, parietal, O, occipital, and T, temporo-sphenoidal lobes; S, fissure of Sylvius; S', horizontal, S'', ascending ramus of S; c, fissure of Rolando; A, ascending frontal, B, ascending parietal convolutions; F1, superior, F2, middle, and F3, inferior, frontal convolutions; P1, superior parietal lobule; P2, inferior parietal lobule; O1, first, O2, second, and O3, third occipital convolutions; T1, first, T2, second, and T3, third temporo-sphenoidal convolutions.

convolutions are four frontal,—first, superior; second, middle; third, inferior; and fourth, ascending; four parietal,—first, ascending; second, superior; third, supramarginal; and fourth, angular; three occipital,—first, second, and third; three temporo-sphenoidal,—first,

second, and third; three orbital,—first, internal; second, external; third, posterior; six convolutions in the island of Reil, and five on the inner surface of the cerebrum,—the marginal, quadrate, cuneate, fornicate, and uncinate. There are three primary fissures on the outer surface of the cerebrum, namely, the fissure of Sylvius, fissure of Rolando, and parieto-occipital. The fissure of Sylvius is first formed. It is found well developed in the entire range of vertebrate brains. In man it passes upward from the base of the anterior third of the brain, runs upward and backward for three-fourths of an inch, and divides into an ascending and a horizontal limb. The stem of the fissure of Sylvius separates the frontal from the temporo-sphenoidal lobe. The fissure of Rolando passes downward and forward from the upper part of the great longitudinal fissure, and terminates just above the angle of division of the fissure of Sylvius. It separates the frontal lobe from the parietal. The parieto-occipital fissure separates the parietal from the occipital lobe. It is placed at the posterior third of the longitudinal fissure, and passes downward between the superior parietal and the first occipital convolution. On the inner surface of the hemispheres it is better developed, and extends downward between the quadrate and cuneate convolutions and terminates in the calcarine fissure.

THE CONVOLUTIONS OF THE FRONTAL LOBE.

The superior, middle, and inferior are short, horizontally-placed gyri, connected by short annectant or secondary convolutions, and separated by the superior and inferior frontal fissures. The ascending frontal is a long, obliquely-placed convolution, which lies between the vertical limb of the fissure of Sylvius in front and the fissure of Rolando behind.

THE CONVOLUTIONS OF THE PARIETAL LOBE.

The ascending lies behind the fissure of Rolando, and runs upward and backward, and is continuous with the superior parietal, which is continued backward to the parieto-occipital fissure. The supra-marginal convolution lies behind the ascending parietal. It is frequently continuous with the angular, which bends abruptly downward. The intra-parietal fissure separates the supra-marginal from the angular convolution.

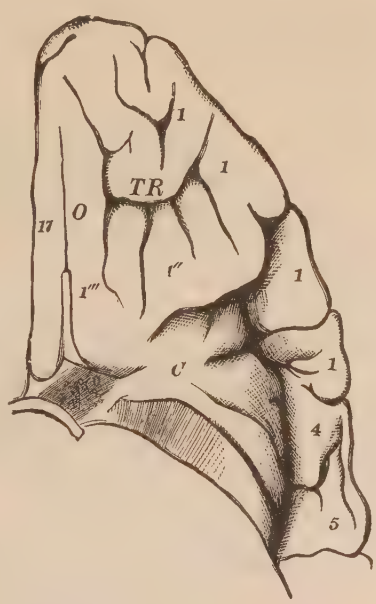

FIG. 122.—ORBITAL SURFACE OF THE LEFT FRONTAL LOBE AND THE ISLAND OF REIL; THE TIP OF THE TEMPORO-SPHENOIDAL LOBE HAS BEEN REMOVED.

17, convolution of the margin of the longitudinal fissure; O, olfactory fissure, with the olfactory lobe removed; TR, triradiate fissure; 1'' and 1''', convolutions of the orbital surface; 1, 1, 1, 1, under surface of the infero-frontal convolution; 4, under surface of the ascending frontal, and 5, of the ascending parietal convolutions; C, central lobe, or island.

OCCIPITAL CONVOLUTIONS.

The *occipital* convolutions are obliquely placed, and separated by secondary fissures, which vary much in extent and depth.

The *temporo-sphenoidal* convolutions are horizontally disposed and separated by deep and well-marked fissures, one of which (that below the first temporo-sphenoidal convolution) is called the parallel fissure.

The *orbital* convolutions are three in number. They rest on the orbital plates of the frontal and on the lesser wings of the sphenoid. They are designated the anterior, posterior, and inner, the latter lying parallel with the commencement of the marginal convolution. These

convolutions are separated by the stellate fissure. By separating the frontal and temporo-sphenoidal lobes, the *island of Reil* is exposed. It consists of a cluster of five or six convolutions projecting from the bottom of the fissure of Sylvius.

The inner surface of the cerebral hemisphere is flat and presents five principal convolutions. First, the marginal convolution skirts the free border of the longi-

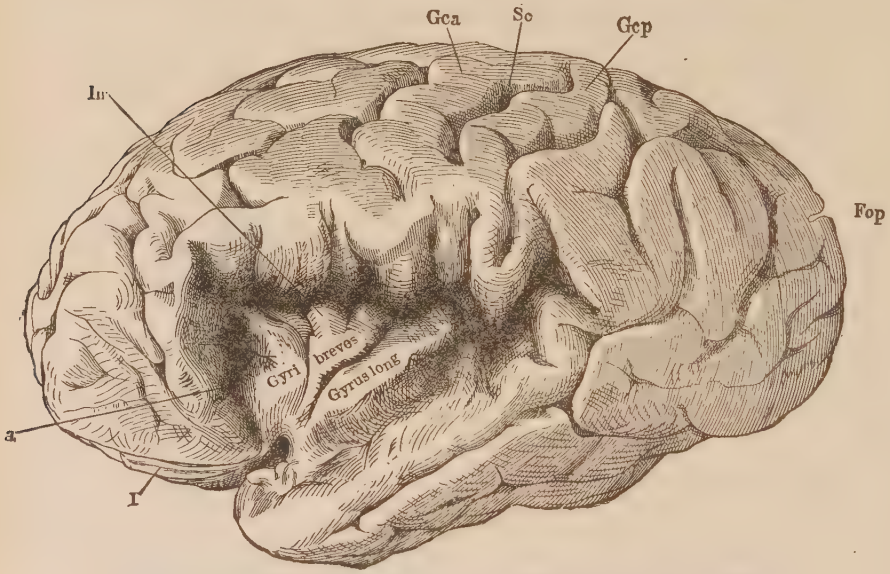

FIG. 123.—LEFT HEMISPHERE OF BRAIN, SHOWING ISLAND OF REIL.
In, island of Reil; Sc, sulcus centralis; Gca, Gcp, gyrus centralis, anterior and posterior; Fop, fissura parieto-occipitalis.

tudinal fissure. It begins at the inner side of the orbital lobe and passes upward and backward to the junction of the calloso-marginal and Rolandic fissures. Behind, it is the quadrate convolution, which is separated from the cuneate lobule by the parieto-occipital fissure. These three convolutions—the marginal, quadrate, and cuneate—are all placed along the free border of the longitudinal fissure.

The gyrus fornicatus, or arched convolution, arises in common with the marginal, and curves upward and backward over the corpus callosum, and becomes continuous with the quadrate and uncinate convolutions.

The interval between the corpus callosum and gyrus fornicatus has been called the ventricle of the corpus callosum. The uncinate, or hippocampal gyrus, arises below the posterior bulbous part of the corpus callosum and passes horizontally forward for about two inches, and

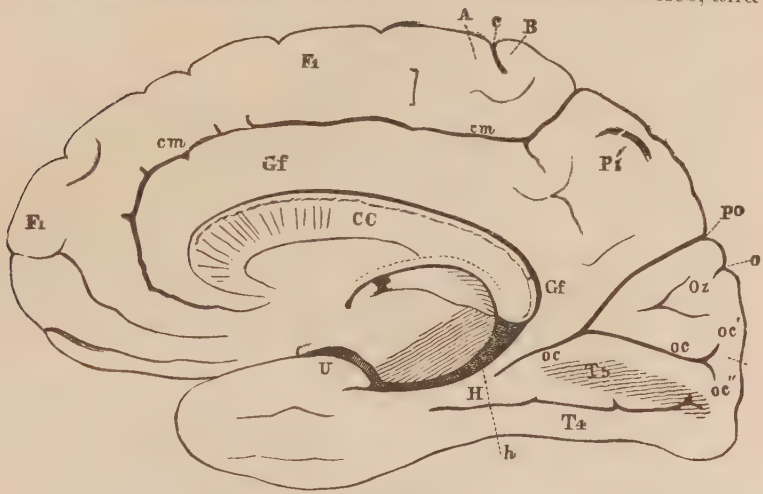

FIG. 124.—CONVOLUTIONS ON THE MEDIAN ASPECT OF THE RIGHT HEMISPHERE.

CC, corpus callosum divided longitudinally; Gf, gyrus fornicatus; H, gyrus hippocampi; h, sulcus hippocampi; U, uncinate gyrus; cm, calloso-marginal fissure; F1, first frontal convolution; c, terminal portion of fissure of Rolando; A, ascending frontal convolution; B, ascending parietal convolution and paracentral lobule; Pi, præcuneus, or quadrate lobule; Oz, cuneus; Po, parieto-occipital fissure; o, transverse occipital fissure; oc, calcarine fissure; oc', superior, oc'', inferior ramus of the same; D, gyrus descendens; T4, gyrus occipito-temporalis lateralis; T5, gyrus occipito-temporalis medialis.

terminates in a hook-like process, which curves upward and backward over the anterior extremity of the dentate fissure. The fissures on the inner surface of the cerebrum are :—

The *calloso-marginal*, which separates the marginal convolution from the gyrus fornicatus and communicates with the fissure of Sylvius. The *parieto-occipital*, separates the quadrate from the cuneate lobule and passes

downward and forward, dividing into two branches, one of which communicates with the calcarine fissure. The *calcarine* fissure is a short, deep, horizontally placed fissure below the posterior bulbous part of the corpus callosum. It causes an elevation on the floor of the posterior cornu of the lateral ventricle, called the calcar, or hippocampus minor. Above the uncinate gyrus is a short, deep fissure, which extends deeply into the descending cornu of the lateral ventricle, forming on its floor and inner aspect the fascia dentata. Below the uncinate convolution is a long fissure, called the *collateral.* It causes an elevation on the floor of the posterior cornu of the lateral ventricle, designated the emmenentia collateralis. The base of the brain is flattened and irregular, and presents for examination the frontal and temporo-sphenoidal lobes, the pons Varolii, medulla oblongata, cerebellum, and a number of structures along the median line. From before backward, the following points are seen :—

1. *Longitudinal Fissure.*—The deep, vertical, longitudinal fissure that divides the two hemispheres of the cerebrum. It is bridged by the corpus callosum.

2. *Corpus Callosum.*—The white, transverse commissure between the two cerebral hemispheres. It is about four inches long, and is placed about the junction of the upper three-fifths and lower two-fifths of the inner surface of the cerebrum. It is bodily advanced so as to encroach upon the anterior portion of the cerebral hemispheres.

3. *Olfactory Bulbs, Tracts, and Roots.*—The first pair of nerves. The bulbs are the anterior enlarged extremities of the olfactory tracts. They lie on the cribriform plate of the ethmoid, through which they send numerous filaments into the nose. The tracts lie

in a sulcus which separates the marginal from the internal orbital convolution.

4. *Fissure of Sylvius.*—Entirely separates the frontal from the temporo-sphenoidal lobe. It begins external to the anterior perforated space.

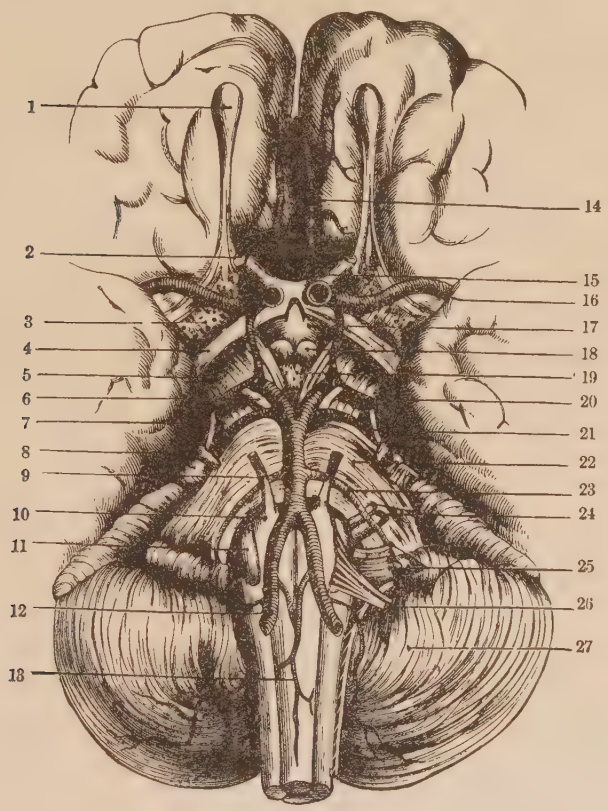

FIG. 125.—BASE OF BRAIN.

1, olfactory bulb; 2, optic nerves; 3, anterior perforated space; 4, tractus opticus; 5, crus cerebri; 6, third pair of nerves; 7, fourth pair of nerves; 8, fifth pair of nerves; 9, sixth pair of nerves; 10, pyramid; 11, olivary body; 12, vertebral artery; 13, anterior spinal artery; 14, anterior cerebral artery; 15, lamina cinerea; 16, fissure of Sylvius, which lodges the middle cerebral artery; 17, tuber cinereum; 18, corpora albicantia; 19, posterior perforated space; 20, posterior cerebral artery; 21, superior cerebellar artery; 22, pons Varolii; 23, anterior cerebellar artery; 24, seventh and eighth pairs of nerves; 25, ninth, tenth, and eleventh pairs of nerves; 26, twelfth pair of nerves; 27, cerebellum.

5. *Anterior Perforated Space.*—Continuous with the lamina cinerea and tuber cinereum is a triangular layer of gray matter, at the inner part of the fissure of Sylvius.

It is numerously perforated for the passage of vessels to the corpus striatum.

6. *Lamina Cinerea.*—A gray layer continuous with the termination of the corpus callosum. It lies below the chiasm of the optic nerves.

7. *Optic Nerves, Chiasm and Tracts.*—The second pair of nerves. The tracts begin at the corpora geniculata, curve around the outer part of the crura cerebri; cross, forming the chiasm, which sends off the optic nerves.

8. *Tuber Cinereum.*—The gray, dome-shaped structure that extends between the crura cerebri. It forms the floor of the third ventricle.

9. *Pituitary Body and Infundibulum.*—The infundibulum is a funnel-shaped process of the tuber cinereum. It hangs down and is drawn slightly forward. It presents a central canal. Attached to it is the pituitary body,—a trilobed structure situated in the sella turcica.

10. *Corpora Albicantia.*—Located near the posterior part of the tuber cinereum, formed by reduplication of the anterior pillars of the fornix.

11. *Posterior Perforated Space.*—Behind the corpora albicantia; transmits vessels to the optic thalami.

12. *Crura Cerebri.*—Formed by the continuation of the fibres of the medulla. As they emerge from behind the pons the two crura diverge. They are about one inch broad, one and three-fourths inches long, and contain a central gray portion,—the locus niger.

13. *Third Pair of Nerves.*—Motor oculi, wind around the under side of the crura.

14. *Fourth Pair of Nerves.*—Patheticus, emerge from around the outer border of crura.

15. *Pons Varolii.*—Consists of white and gray matter. The white fibres run both transversely and longi-

tudinally. The transverse are the commissural fibres between the two hemispheres of the cerebellum, interwoven by the longitudinal fibres forming the crura.

16. *Fifth Pair of Nerves.*—Arise by two roots from each side of the pons, about three-quarters of an inch external to the median groove.

17. *Sixth Pair of Nerves.*—Abducens, arise in the groove between the anterior pyramids and olivary body, just behind the pons.

18. *Medulla Oblongata.*—Cuboidal in form, is the upper enlarged portion of the spinal cord.

19. *Twelfth Pair of Nerves.*—Arise in the same groove as the sixth.

20. *Seventh, Eighth, Ninth, Tenth, and Eleventh Pairs of Nerves.*—Arise in the groove between the olivary body, lateral tract, and restiform body.

21. *Cerebellum*, or *After-Brain.*—Lies in the lower occipital fossæ. It fits like a saddle over the upper part of the medulla.

A horizontal section below the convolutions through the two hemispheres is oval in outline, and has been called the centrum ovale minus. This section shows the exterior cortical portion of the brain and the white, fibrous portion within, on which are seen numerous red points,—the puncta vasculosa,—which are the minute blood-vessels of the white matter cut across. A section through the cerebral hemispheres on a level with the corpus callosum is called the centrum ovale majus. This section exposes the upper surface of the corpus callosum, which is the great transverse commissure between the two cerebral hemispheres. On its upper surface are seen some longitudinal elevations of white fibres called the nerves of Lancisi. The upper surface of this commissure is slightly wavy from front to back. The under

surface forms the roof of the lateral ventricles, which are two symmetrical, cuboidal, serous sinuses, presenting for examination a roof, a floor, an inner wall and an outer wall, an anterior cornu, a posterior cornu, and a middle cornu. The roof of the lateral ventricle, formed by the corpus callosum, as above stated, is arched from front to

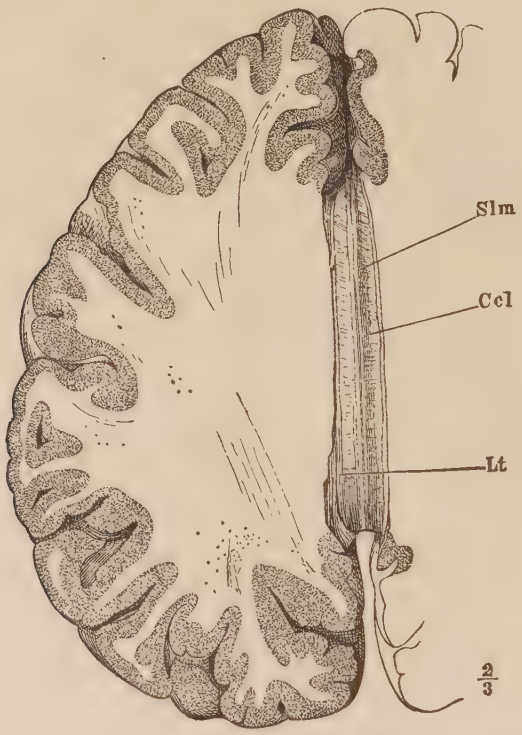

FIG. 126.—CENTRUM OVALE MAJUS.
Ccl, corpus callosum; Lt, ligamentum tectum; Slm, striæ longitudinales.

back. The floor of each ventricle is made up of the following structures:—

Corpus striatum,	Tænia semicircularis,
Optic thalamus,	Choroid plexus,
Edge of fornix,	Fornix.

The floor of the ventricle is very irregular. The outer wall is formed by the fibres of the cerebral hemi-

sphere. The inner wall is formed by the septum lucidum, which is the vertical partition between the right and left lateral ventricles. The anterior cornu is an extension of the lateral ventricle into the anterior lobe.

FIG. 127.—TRANSVERSE SECTION OF THE HUMAN BRAIN THROUGH THE BASAL GANGLIA.

NC, caudate nucleus; NC', the amygdala; LN, lenticular nucleus; TH, optic thalamus; F, frontal lobe; TS, temporo-sphenoidal lobe; O, occipital lobe; Cls, claustrum; IK, thalmo-lenticular portion of internal capsule; K, knee of same; IK', caudo-lenticular portion of same; EK, external capsule; f, fornix cut across; In, insula, or island of Reil; Op, depth of Sylvian fissure; mc, middle commissure; ph, posterior horn of lateral ventricle; ah, anterior horn of same; Sl, septum lucidum.

The middle cornu curves downward behind and beneath the optic thalamus into the middle lobe. The posterior cornu extends backward into the posterior lobe.

The *corpus striatum*, one of the great basal ganglia, is striated on section, and consists of a mixture of white and

gray matter. It is pear-shaped, the larger end of the pear presenting forward and projecting into the anterior and inferior part of the lateral ventricle. Along its upper surface is a group of ganglionic cells called the caudate nucleus. Within the substance of the corpus striatum is the lenticular nucleus,—another arrangement of ganglionic nerve-cells. The corpus striatum rests on the anterior portion of the crus cerebri of each side. The greater portion of it is imbedded in the cerebral hemispheres, and is known as the extra-ventricular portion, while that part which presents within the ventricle is known as the intra-ventricular portion. The *tænia semicircularis* is a longitudinal commissure which arises anteriorly in common with the anterior pillar of the fornix, and curves backward and outward in the groove between the optic thalamus and corpus striatum, and becomes finally lost in the middle cornu of the lateral ventricle. The *optic thalamus* is placed behind and to the inner side of the corpus striatum; it is an ovoidal structure, and rests upon the crus cerebri of each side. It is composed of an external white portion and an internal mixed portion of gray and white matter. A collection of ganglionic cells in the interior of the optic thalamus, arranged in the form of a sickle, is called the falciform nucleus. The anterior extremity of the optic thalamus is pointed and forms the posterior boundary of the foramen of Monro. The posterior extremity is broad and rounded, and presents two elevations,—the external and internal geniculate bodies,—which are the termini of the optic tracts. The upper surface is convex and rounded. Its outer portion forms part of the floor of the lateral ventricle. Its inner portion is covered by the fornix, from which it is separated by the velum interpositum and its fringe-like border, the choroid plexus. The inner surface of the

optic thalamus forms the outer wall of the third ventricle. The *choroid plexus* is the edge of the velum interpositum thrown into a fringe-like border of capillary vessels. It passes from the lateral into the third ventricle through the foramen of Monro. The *edge of the fornix* is called the corpus fimbriatum, and rests upon the choroid plexus. The *fornix* is a longitudinal commissure of white fibres, which arises in common with the corpus callosum. It curves forward and downward, diverging from the under surface of the corpus callosum; it is separated from it by the septum lucidum. As it passes forward it becomes narrow, and divides into the two anterior crura, which pass down behind the anterior commissure to the posterior part of the tuber cinereum, where they become reduplicated and form the corpora albicantia. The posterior crura curve downward into the middle cornua of the lateral ventricle, and lie upon the hippocampi. The edge of each posterior crus is called the corpus fimbriatum. The under surface of the fornix is striated, which arrangement has been called the lyra. The anterior cornu extends into the frontal lobe, and curves forward, outward, and downward around the anterior portion of the corpus striatum.

The posterior cornu extends into the occipital lobe, and curves backward, downward, and inward. On its floor is a curved elevation, called the calcar, or hippocampus minor. It is formed by an involution of brain-substance over the calcarine fissure. Between the posterior and middle cornua is an elevation due to the extension inward of the collateral fissure. It is called the collateral eminence. The middle cornu curves backward, outward, downward, forward, and inward behind and beneath the optic thalamus, and deeply into the substance of the temporo-sphenoidal lobe. On its floor are

seen (1) the hippocampus major, (2) pes hippocampi, (3) corpus fimbriatum, (4) choroid plexus, (5) dentate fascia, and (6) the transverse fissure of the brain. The hippocampus major is an elevation formed by the involution of the dentate fissure. It is rounded, curved, and terminates in an enlarged nodular extremity called the

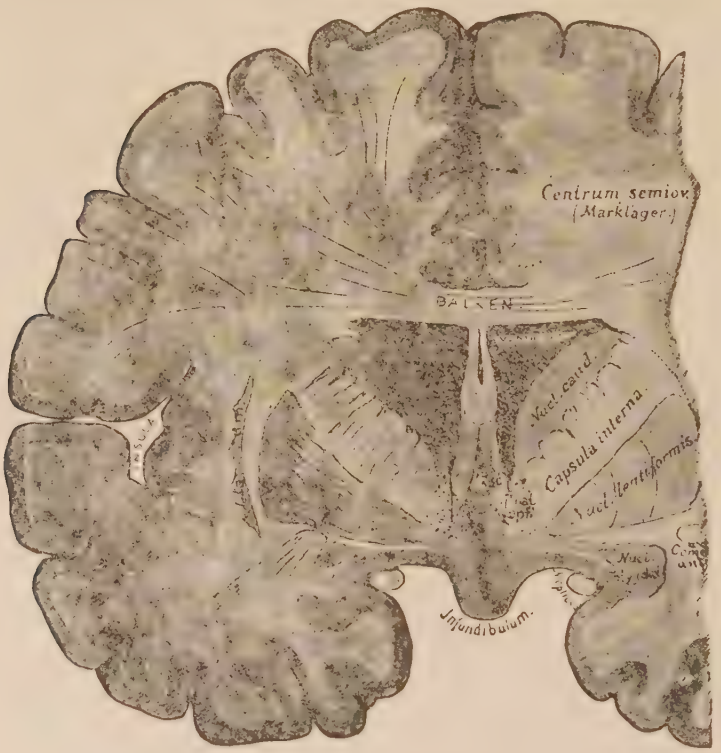

FIG. 128.—VERTICAL SECTION THROUGH THE ADULT BRAIN.

pes hippocampi. It is covered by a layer of gray matter more or less jagged along its inner free border, and called the fascia dentata.

The corpus fimbriatum is the edge of the posterior pillar of the fornix. The transverse fissure, a strongly-curved fissure bounded above by the common origin of

the corpus callosum and fornix, below by the tubercula quadrigemina and optic thalami, and laterally and above on each side by the corpus fimbriatum of the middle cornu. The septum lucidum is the vertical partition between the lateral ventricles. It is attached above along the median line of the under surface of the corpus callosum, below along the median line of the upper surface of the fornix. It consists of two laminæ of white and gray matter inclosing a small serous sinus,—the fifth ventricle.

Immediately below the fornix is the velum interpositum,—a process of pia mater transmitted by the transverse fissure. It is triangular in shape, and presents along its free borders the choroid plexus. Two similar tufted choroid plexuses hang down from its under surface into the third ventricle. Running longitudinally along its upper surface are two large veins,—the venæ galeni,—which receive the blood from the choroid plexuses, and also from the corpora striata. They empty into the straight sinus.

The third ventricle is located between the two optic thalami. It is bounded above by the fornix, from which it is separated by the velum interpositum; laterally, by the inner surfaces of the optic thalami and the peduncles of the pineal gland; the floor, by the structures of the interpeduncular space at the base of the brain; in front, by the anterior pillars of the fornix; behind, by the anterior aspect of the corpora quadrigemina and the aqueduct of Sylvius. The third ventricle is lined by gray matter, and is crossed by three commissures,—the anterior, white, placed in front of the anterior pillars of the fornix, passes between the corpora striata; the middle, gray, passes between the optic thalami; and the posterior, white, between the optic thalami; it supports the pineal gland. Four openings lead into the third ventricle,

—anteriorly, the two foramina of Monro; bounded in front by the anterior pillars of the fornix; behind, by the anterior extremities of the optic thalami. Each transmits the choroid plexus. The aqueduct of Sylvius leads from the third to the fourth ventricle; it is lined by

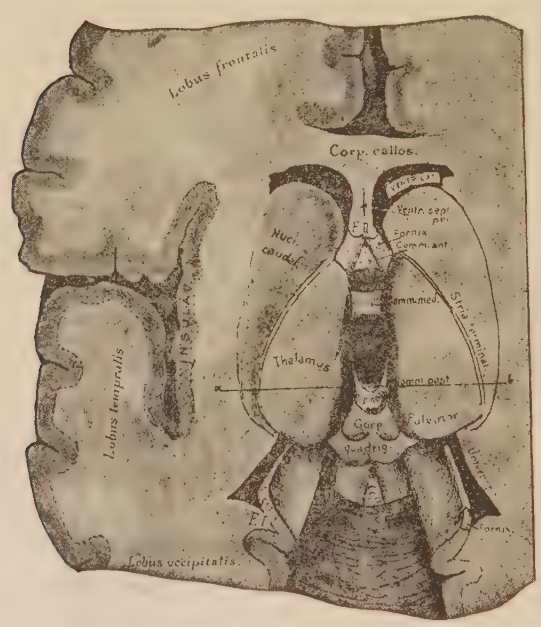

FIG. 129.—HORIZONTAL SECTION OF BRAIN, SHOWING THIRD VENTRICLE.

gray matter, and perforates the base of the tubercula quadrigemina. The infundibulum, pendent from the tuber cinereum, leads to the pituitary body. It is patulous in the fœtus, but exists as a funnel-shaped pit in the adult.

The pineal gland is a reddish, conoidal body, which rests upon the upper surface of the posterior commissure of the third ventricle and the tubercula quadrigemina. It is invested and held in position by the velum interpositum, and is attached to the inner upper part of the optic thalami by two slender white peduncles, which conjoin anterior to their attachment to the pineal gland. It is formed principally of gray matter. It contains a small amount of earthy salts.

The tubercula quadrigemina, situated behind the third ventricle, extends between the posterior extremities of the optic thalami. It consists of two pairs of rounded elevations,—the upper or larger, called the nates; the lower, the testes.

They are connected with the optic thalamus by the anterior and posterior commissural bands. In structure they are composed principally of gray matter. The aqueduct of Sylvius passes through their base; it leads from the third to the fourth ventricle.

The fourth ventricle is situated in the upper surface of the medulla. It is a diamond-shaped depression, about an inch and a half long and one inch wide. It is bounded above by the processus e cerebello ad testes and the valve of Vieussens; below, by the diverging posterior columns and restiform bodies; and laterally, at the middle, by the middle peduncles of the cerebellum. Its roof is formed by the inferior vermiform process of the cerebellum. Projecting into the fourth ventricle are two or three fringes of pia mater known as the choroid plexuses of the fourth ventricle.

The floor of the fourth ventricle is formed by the posterior surface of the transverse commissure of the gray matter of the cord and medulla exposed by the divergence of the posterior columns and restiform bodies.

It presents the posterior median longitudinal fissure, which is quite shallow, and on each side a round bundle of fibres running the entire length of the floor of the fourth ventricle, and called the fasciculi teretes. Islands

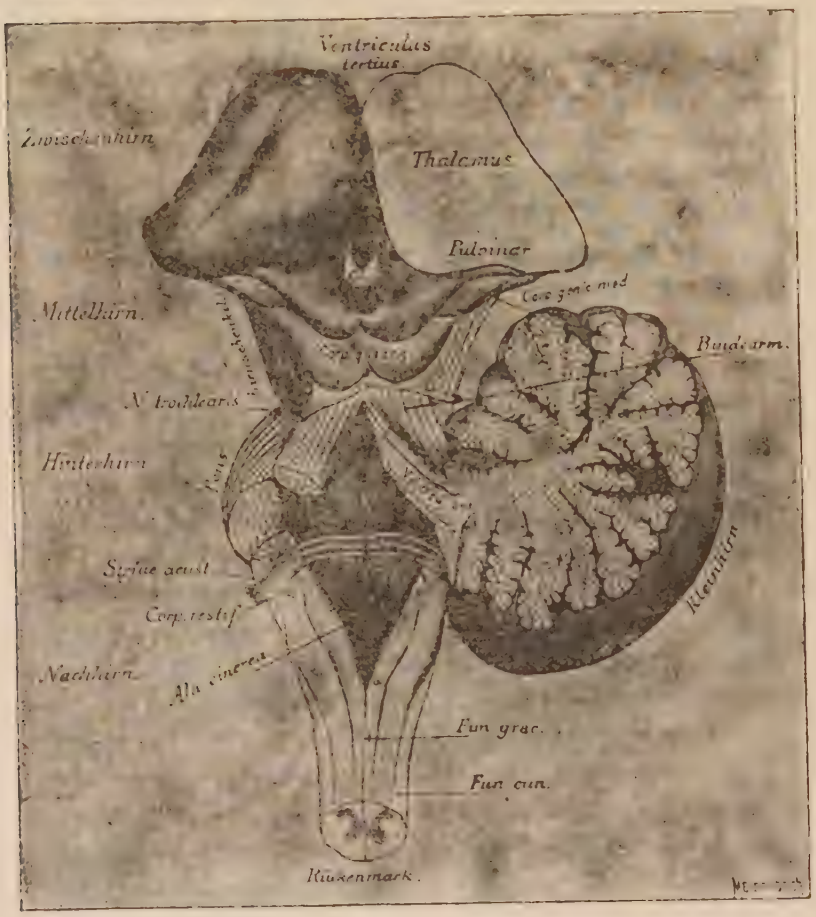

FIG. 130.—FLOOR OF FOURTH VENTRICLE.

of ganglionic cells impart a lighter tint of color to parts of the floor of the fourth ventricle, and are called the blue spots and violet streaks of the floor of the ventricle. The processus e cerebello ad testes are white fibres which

pass from the cerebellum upward to the testes. The valve of Vieussens stretches between the two processus e cerebello ad testes at their point of entrance into the tubercula quadrigemina. It is a fold of gray matter which forms the roof of the aqueduct of Sylvius.

The medulla oblongata is the upper enlarged part of the spinal cord. It is about one and one-half inches long, one inch broad, and three-quarters of an inch thick. It rests upon the upper surface of the basilar process of the occipital bone, and is limited above by the pons Varolii. It presents an anterior and posterior median fissure, which divide the medulla into two symmetrically arranged halves, each of which presents the anterior pyramid, lateral tract and olivary body, restiform body and posterior pyramid. The anterior pyramid is separated from its fellow by the anterior median fissure. It consists of bundles of white fibres which at the lower part of the medulla interlace with those of the other pyramid, forming the decussation of the pyramids. The lateral tract, external to the anterior pyramid, presents at its upper part the olivary body, placed with its long diameter in the direction of the fibres of the tract. Its lower portion is crossed by a number of curved fibres. A section of the olivary body discloses the dentate capsule,—an open capsule of gray matter.

The restiform body, continuous with the posterior column of the cord, is a large, rounded tract of white fibres placed between the lateral tract and the posterior pyramid. The posterior pyramids, continuous with the posterior median columns of the cord, are separated from each other by the posterior median fissure. At the inferior part of the fourth ventricle the posterior pyramids and the restiform bodies diverge widely and form the inferior lateral boundary of the fourth ventricle,

and then pass to the cerebellum and form its inferior peduncles.

The pons Varolii is the great commissure at the base of the brain, connecting the hemispheres of the cerebellum with the cerebrum and medulla. It rests on the basilar process of the occipital and os planum of the sphenoid, and presents an inferior convex surface, a supe-

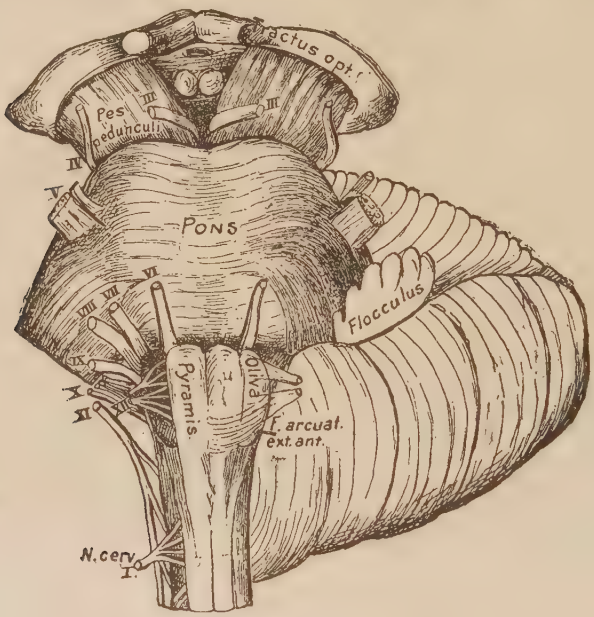

FIG. 131.—MEDULLA OBLONGATA, PONS, CEREBELLUM, AND CRURA CEREBRI, SEEN FROM IN FRONT.

rior and inferior border. The borders are sharply defined, —the anterior curved from side to side, the inferior slightly concave. The inferior surface presents a median longitudinal groove, in which rests the basilar artery. About one inch on either side of the median groove is the origin of the fifth pair of nerves—nearer the anterior than the inferior border. Externally the pons narrows and enters the cerebellum, forming its middle pe-

duncles. The upper surface of the pons forms part of the floor of the fourth ventricle. Its fibres are divided into transverse and longitudinal. Of the former there are two planes—superficial and deep. The longitudinal layers are likewise separated into two sets: the first passes upward between the transverse planes; the deep

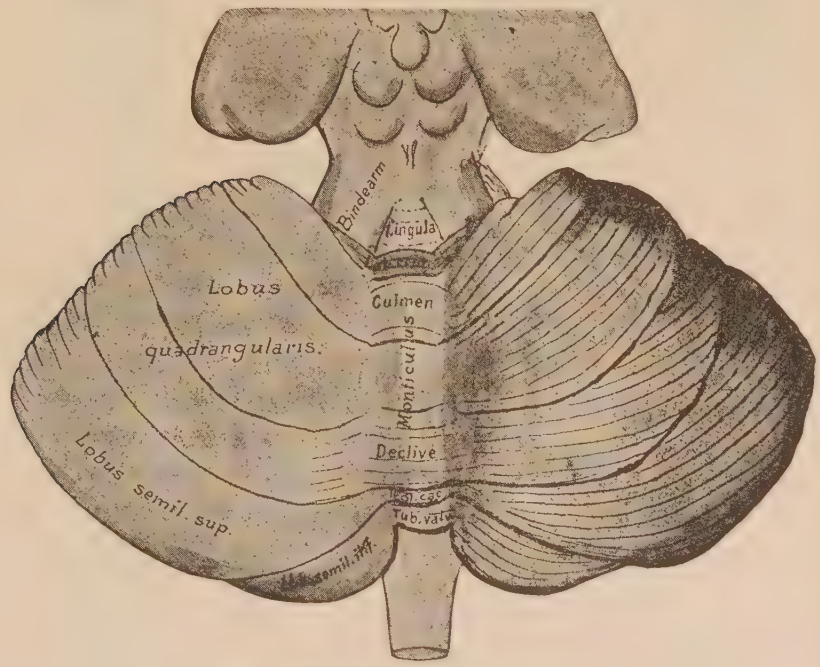

FIG. 132.—THE CEREBELLUM, UPPER SURFACE.

set, above the deep transverse plane, forms part of the fibres of the floor of the fourth ventricle.

The cerebellum is situated below the posterior lobes of the cerebrum. It is lodged in the inferior occipital fossæ. It weighs about five and one-half to six ounces. It is about four inches transversely, two and one-half inches antero-posteriorly, two inches vertically at the thickest part. It is composed of a gray cortex and a white medullary portion, in which there is imbedded an

open gray capsule, called the corpus dentatum. It consists of two symmetrical hemispheres joined together by a central constricted commissural portion. The upper surface is flattened, slightly convex, and presents two lobes,—a large anterior, the quadrate, and a narrower portion, the semilunar. Along the median line is the transverse commissure called the superior vermiform process, which begins at the anterior notch and terminates at the posterior notch of the cerebellum. Three slight eminences along the superior vermiform process

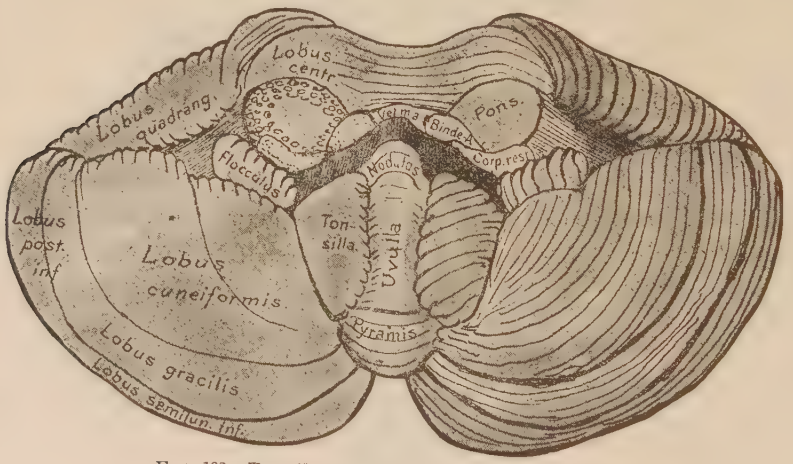

FIG. 133.—THE CEREBELLUM, INFERIOR SURFACE.

have received names. They are the central, anterior, and posterior lobes. The inferior surface of the cerebellum is irregular and uneven. Each hemisphere presents four lobes,—the tonsillar, digastric, slender, and posterior inferior. The inferior vermiform process is depressed, and presents from behind forward the short commissure, the pyramid, the uvula, the nodule, and arching outward from each side of the nodule is a lamina of white matter called the velum. At each extremity of the velum is the flocculus,—a group of miniature convolutions. The



FIG. 134.—SPINAL CORD AND NERVES, ANTERIOR ASPECT.
Nc2, suboccipital nerve; Ld, ligamenta dentata; Nd1, first dorsal nerve; Nl1, first lumbar nerve from cauda equina; Ns1, first sacral nerve from cauda equina.

cerebellum presents a great number of fissures. One, the great horizontal fissure, is of large size, and divides the cerebellum into an upper and lower portion. If a vertical section is made through the cerebellum, a remarkable arrangement of the gray cortical matter into laminæ is observed. It is called the arbor vitæ cerebelli.

THE SPINAL CORD.

The spinal cord is that portion of the cerebro-spinal system situated in the spinal canal. It is invested by three membranes, —the dura mater, the arachnoid, and the pia mater. The dura mater of the cord differs from the dura mater of the brain, firstly, in that it is a loose, tubular sac which is not adherent to the bones of the spinal canal; secondly, it does not send processes into the cord; and, thirdly, its lamellæ do not diverge to form blood-sinuses. It is attached to the margins of the foramen magnum, and forms tubular sheaths for the anterior and posterior roots of spinal nerves. Its lower end becomes blended with the periosteum of the sacrum and coccyx.

The arachnoid, as in the

brain, is a shut serous sac having a closely attached parietal and a loosely attached visceral layer.

The pia mater, thick, less vascular than in the brain, sends processes into the principal fissures of the cord and at the sides forms the dentate ligament, —a series of processes attached to the dura mater, and which help to sustain the cord in position. The spinal cord is about sixteen inches long. It extends from the atlas to the first lumbar vertebra, weighs about an ounce and a half, and consists of a cylinder of nerve-tissue which terminates below in a leash of nerve-bundles called the cauda equina. The white substance of the cord is on the exterior; the gray matter, arranged in the

FIG. 135.—SECTION OF SPINAL CORD AND MEMBRANES.
1, dura mater; 2, arachnoid membrane; 3, ganglion on posterior root; 4, anterior root of spinal nerve; 5, subarachnoid space; 6, posterior branch of spinal nerve; 7, anterior branch of spinal nerve.

form of the letter **H** on transverse section, is within. The cord presents two enlargements,—the cervical and lumbar,—corresponding to the roots of origin of the brachial and lumbar plexuses, respectively. The cord is divided into two symmetrical halves by the anterior and posterior median fissures. The anterior median fissure extends the entire length of the cord, and is continuous with the same fissure of the medulla. It is not as deep as the posterior median fissure, which, like the anterior, extends the entire length of the cord and is continuous with the median fissure on the floor of the fourth ventricle. Each half of the cord presents four columns,—the anterior, lateral, posterior, and posterior median; separated by

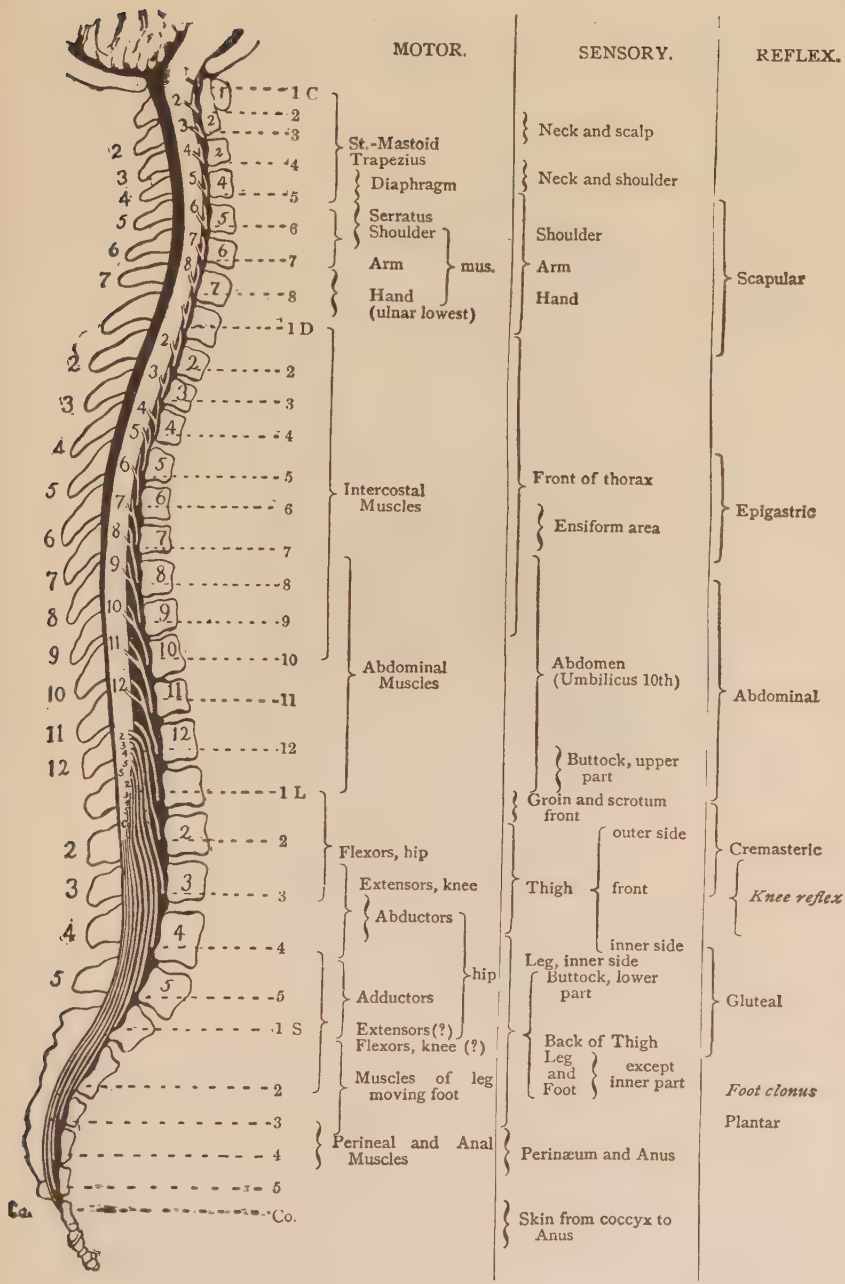
MOTOR.
SENSORY.
REFLEX.
1 C
2
3
4
5
6
7
8
1 D
2
3
4
5
6
7
8
9
10
11
12
1 L
2
3
4
5
1 S
2
3
4
5
Co.
St.-Mastoid
Trapezius
Diaphragm
Serratus
Shoulder
Arm
Hand
(ulnar lowest)
mus.
Intercostal Muscles
Abdominal Muscles
Flexors, hip
Extensors, knee
Abductors
hip
Adductors
Extensors (?)
Flexors, knee (?)
Muscles of leg moving foot
Perineal and Anal Muscles
Neck and scalp
Neck and shoulder
Shoulder
Arm
Hand
Front of thorax
Ensiform area
Abdomen (Umbilicus 10th)
Buttock, upper part
Groin and scrotum front
Thigh
outer side
front
inner side
Leg, inner side
Buttock, lower part
Back of Thigh
Leg and Foot
except inner part
Perinæum and Anus
Skin from coccyx to Anus
Scapular
Epigastric
Abdominal
Cremasteric
Knee reflex
Gluteal
Foot clonus
Plantar

FIG. 136.

three fissures,—the antero-lateral, postero-lateral, and posterior.

The antero-lateral fissure is the line of emergence of the filaments of the anterior roots of spinal nerves. It is just external to the anterior cornu of the gray matter of the cord. The postero-lateral fissure, a slight groove, gives origin to the posterior roots of spinal nerves. The extremity of the posterior cornu of gray matter extends quite up to the postero-lateral groove. The posterior

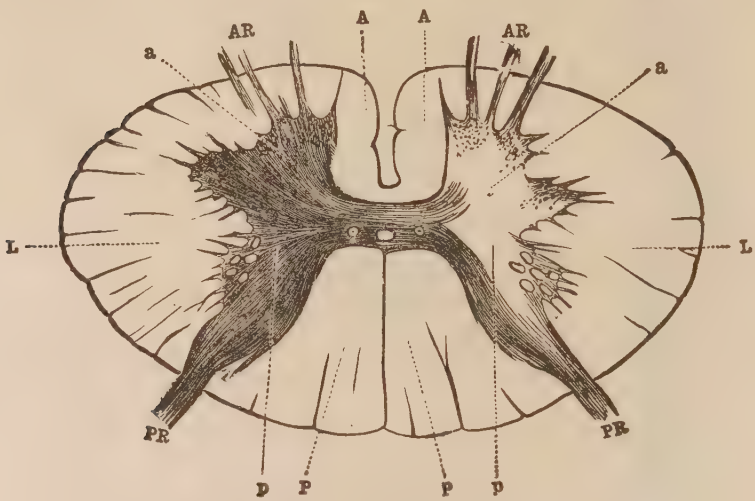

FIG. 137.—TRANSVERSE SECTION OF THE SPINAL CORD.
p, posterior horns; a, anterior horns; PR, posterior roots; AR, anterior roots; A, the white anterior, LL, the lateral, PP, the posterior columns.

fissure separates the posterior median and the posterior columns of the cord. It is a faintly marked groove, deeper in the cervical than in any other region. The anterior column is a tract of white fibres continuous with the anterior pyramid of the medulla. The lateral column, between the two lateral fissures, is the largest column of the cord. It is a tract of white fibres continuous with the lateral tract of the medulla. The posterior column is a tract of white fibres between the

posterior median and lateral columns of the cord. It is continuous with the restiform body of the medulla. The posterior median column is a narrow tract of white fibres continuous with the posterior pyramid of the medulla.

FIG. 138.—HALF SECTION THROUGH THE LUMBAR CORD.
1, posterior root; 2, inner portion of posterior root; 3, posterior commissure; 4, central canal; 5, fibres of anterior commissure; 6, fibres of anterior root.

The gray or vesicular substance of the cord is in the interior, invested by the white, fibrous structure. It consists of two crescents connected by commissural fibres. The anterior segment of the gray crescent is called the

anterior cornu. Imbedded in it are a number of large motor cells, which are intimately connected with the anterior roots of spinal nerves. The posterior segment of the gray matter, or posterior cornu, contains smaller groups of polar cells, connected with the posterior roots of spinal nerves. In the centre of the gray commissure is the opening of the central canal, impervious in the adult. It is lined by endothelium and opens just below the calamus scriptorius of the fourth ventricle. In the adult nothing remains of it except a pit called the foramen cæcum, below the calamus scriptorius. The two halves of the cord are also associated by the anterior and posterior white commissures, which pass from side to side in front and behind the gray commissure. The gray matter of the cord is best developed in the cervical, next in the lumbar, and least in the dorsal region.

CRANIAL NERVES.

Twelve pairs of nerves take their origin from the brain. They are:—

1. Olfactory (special sense—smell).
2. Optic (special sense—sight).
3. Motor oculi (motion).
4. Pathetic (motion).
5. Trifacial (sensation and motion).
6. Abducens (motion).
7. Facial (motion).
8. Auditory (special sense—hearing).
9. Glosso-pharyngeal (special sense and sensation).
10. Pneumogastric (motion and sensation).
11. Spinal accessory (motion and sensation).
12. Hypoglossal (motion).

1. Olfactory Nerve.—Origin, by three roots: (1) middle lobe of brain; (2) from corpus striatum; (3) from gyrus fornicatus. These three roots unite, forming the olfactory tract, which is about one-eighth inch

wide, one and a half inches long, and terminates in the olfactory bulb, which rests on the cribriform plate of the ethmoid. Here it sends off from eighteen to twenty filaments, which pass through the foramina of the cribriform plate, and are distributed to the mucous membrane of the nose.

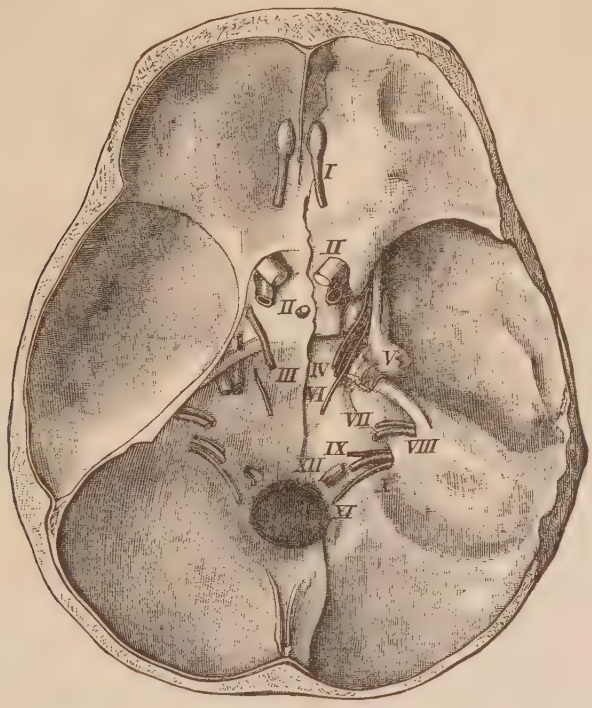

FIG. 139.—THE BASE OF SKULL, WITH THE NERVES WHICH ESCAPE FROM ITS FORAMINA.
The cranial nerves are numbered in their customary order.

2. OPTIC NERVE.—Origin, from the optic chiasm, which is formed by the interlacement of the optic tracts. The chiasm consists of three sets of fibres: one set passing from the optic tract directly to the optic nerve of the same side; another set passing from the optic tract to the opposite optic nerve; the third set being commissural between the optic nerves and between the optic

tracts. The optic nerves pass forward through the optic foramina in the lesser wings of the sphenoid, pierce the sclerotic and choroid, and are distributed in the retinæ.

3. Motor Oculi Nerve.—Origin, from inner side of crus cerebri, just in front of pons. Runs along side of body of sphenoid, passes through the anterior lacerated foramen, and is distributed to all the muscles of the orbit, except the external rectus and superior oblique. It furnishes the motor root to the lenticular ganglion, and, through it, animates the sphincter muscle of the iris.

4. Patheticus Nerve.—Origin, from the outer side of the crus. It is a small nerve, and passes through the anterior lacerated foramen to the superior oblique muscle.

5. Trifacial Nerve.—Origin, by two roots from the side of pons. A large sensory and a small motor root, separated by some of the fibres of the pons. It is the largest cranial nerve. The sensory is the larger root, and is distributed to the structures of the upper, lateral, anterior, and deep parts of the head. The two roots pass forward and outward to the apex of the petrous part of the temporal bone; here the sensory root enters a large semilunar ganglion, the Casserian, while the motor root passes beneath it. The Casserian ganglion rests directly on the surface of the bone beneath the dura mater. It is semilunar in shape, the convexity being anterior. It sends off three branches,—ophthalmic, superior maxillary, and inferior maxillary. The ophthalmic supplies sensation to the contents of the orbit, to the skin above the orbit and of the nose, and to the mucous membrane of the anterior part of the nasal cavities. It sends off three branches,—lachrymal, frontal, and nasal. The lachrymal is distributed to the structures of the orbit. The frontal divides, near the anterior

opening of the orbit, into several branches. One, the supra-orbital, passes through the supra-orbital foramen, and is distributed to the skin of the frontal region. The other passes downward, and is distributed to the skin of the side of the nose. The nasal passes forward to the anterior ethmoidal foramen, enters the cranium, and passes through a slit-like opening at the side of the crista galli into the nose, and supplies its mucous membrane with sensation.

Lenticular Ganglion.—Associated with the ophthalmic nerve is a small sympathetic ganglion, lens-shaped, and placed at the posterior part of the orbit, between the optic nerve and external rectus. It is imbedded in fat, and is about the size of a hemp-seed. It has three roots,—a sensory from the nasal branch of the ophthalmic, a motor from the third nerve, and a sympathetic from the cavernous plexus. The branches of the lenticular ganglion are the short ciliary, which pass forward and are distributed to the eye.

The superior maxillary nerve supplies sensation to the structures associated with the upper jaw. It passes forward through the foramen rotundum, across the upper part of the spheno-maxillary fossa, enters the infra-orbital canal and emerges at the infra-orbital foramen. The branches of the superior maxillary consist of three sets,—the spheno-palatine, infra-orbital, and facial. The *spheno-palatine branches* are: 1. The *orbital*, which divides into the temporal and malar, the former distributed to the temporal region, the latter to the malar region. Both nerves emerge through foramina in the malar bone. 2. The *spheno-palatine* are two sensory roots to Meckel's ganglion. 3. *Posterior dental*, one or two in number, enter canals which open on the posterior border of the superior maxillary and supply the molar teeth, communi-

cating with the anterior dental. *Infra-orbital branch:* The *anterior dental*, given off near the infra-orbital foramen, supplies the front teeth and communicates with the posterior dental, forming the dental loop, from which filaments pass off to the apical foramina, to be distributed to the pulp of the teeth. The canal which contains the dental loop is in the outer wall of the antrum of Highmore. The *facial branches* are: 1. Palpebral, to the eyelids. 2. Nasal, to the skin of the nose. 3. Labial, to the upper lip. 4. Septal, to the septum nasi.

Meckel's Ganglion.—Meckel's ganglion is located in the spheno-palatine fossa, being pendent from the superior maxillary nerve, from which it receives its sensory root. It is about as large as a lentil. It receives its motor root from the facial, through the Vidian; its sympathetic root from the carotid plexus. It sends off ascending and descending branches. The ascending consist of a few filaments, distributed to the orbit; the descending branches supply the nose, roof of the mouth, soft palate, and pharynx. They are numerous and important, and divided into three sets,—anterior, middle, and posterior. The more important branches are: the anterior palatine, which passes through the posterior palatine canal and is distributed to the roof of the mouth; the middle palatine passes down the posterior palatine canal, and is distributed to the soft palate and uvula; the posterior pass down the posterior palatine canal, and are distributed to the soft palate, post-nasal pharynx, and Eustachian tube; the naso-palatine, or nerve of Cotunius, passes to the septum nasi, grooves the vomer, and runs obliquely downward and forward to the anterior palatine canal; it supplies the mucous membrane, periosteum, and hard palate, and communicates with the anterior palatine. Other branches pass to the

parietes and septum nasi. The Vidian nerve is commonly described as a branch of Meckel's ganglion. It passes horizontally backward through the Vidian canal, and communicates with the large petrosal of the facial; a filament also communicates with the carotid plexus of the sympathetic.

The inferior maxillary supplies sensation to the lower teeth, gums, contents of oral cavity, skin of the lower lip, and lower part of the face. Its motor root is distributed to the muscles of mastication. One of its branches—the gustatory—contributes to the special sense of taste. The inferior maxillary passes forward and downward from the Casserian ganglion to the foramen ovale, accompanied by the motor root, which joins the inferior maxillary division just beneath the greater wing of the sphenoid. The nerve then divides into an anterior and posterior trunk. The anterior trunk receives the motor root, and is distributed to the muscles of mastication, namely, to the masseter, buccinator, temporal, and the pterygoids. The posterior trunk divides into three portions,—the inferior dental, gustatory, and auriculo-temporal nerves. The inferior dental enters the inferior dental canal, supplies the teeth, and, at the mental foramen, sends forward a filament to supply the incisor teeth. The bulk of the nerve emerges at the mental foramen, breaks up into a leash of fibres, which are distributed to the integument of the chin and adjoining surface. Just before this nerve enters the inferior dental foramen it gives off the mylo-hyoid, which is distributed to the mylo-hyoid muscle and submaxillary gland.

The auriculo-temporal accompanies the temporal artery. It arises by two roots, between which runs the middle meningeal artery. It gives sensation to the temporal region, side of head, and ear.

The gustatory is distributed to the mucous membrane of tongue, and is a nerve of special sense and common sensation. It is joined by the chorda tympani, from which it receives its properties as a nerve of taste. It passes deeply to the floor of the mouth, where it is submucous and is distributed to the mucous membrane of the anterior part of the tongue.

The Submaxillary Ganglion.—The submaxillary ganglion is situated above the submaxillary gland, and is connected with the gustatory, from which it receives its sensory root. Its motor root comes from the facial, through the chorda tympani. Its sympathetic root is derived from the plexus around the facial artery. It is about the size of a hemp-seed, and distributes its branches to the surrounding structures.

The Otic Ganglion.—A small split-pea-shaped ganglion, placed just below the foramen ovale. It receives its sensory and motor roots from the inferior maxillary, its sympathetic root from the carotid plexus. Its branches run to adjoining structures; one animates the tensor tympani muscle; others are distributed to the muscles of the soft palate.

6. Abducens.—Supplies the external rectus. It arises in the groove between the anterior pyramid and olivary body, just below the pons. It runs along the side of the body of the sphenoid, leaves the cranium by the anterior lacerated foramen, lying on its lower boundary, and is distributed to the external rectus.

7. Facial.—The nerve of motion to most of the muscles of the face. It arises posterior to the olivary body, in the groove between it and the restiform body. It passes forward and outward and enters the internal auditory meatus, in common with the eighth nerve, lying upon it. It enters the aqueduct of Fallopius,

through which it runs, and emerges under cover of the parotid gland from the stylo-mastoid foramen. It runs through the parotid gland and appears at the side of the face as a web-like plexus called the pes anserinus. The facial sends off two sets of communicating branches,—

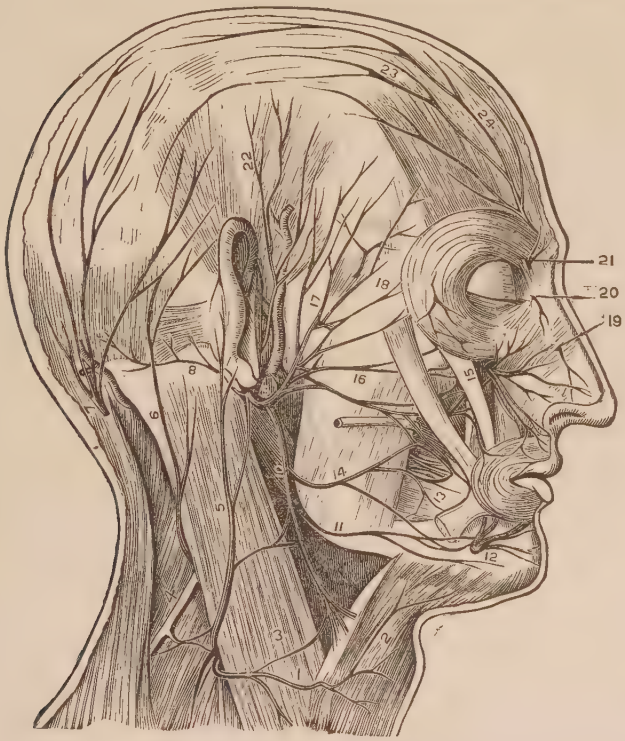

FIG. 140.—NERVES DISTRIBUTED TO THE FACE AND HEAD.

1, superficial cervical; 2, platysma myoides (muscle); 3, sterno-mastoid (muscle); 4, spinal accessory; 5, auricularis magnus; 6, occipitalis minor; 7, great occipital; 8, posterior auricular; 9, facial; 10, infra-maxillary; 11, supra-maxillary; 12, mental; 13, buccinator (muscle); 14, buccal; 15, infra-orbital; 16, malar and infra-orbital nerves; 17, temporal; 18, termination of temporo-malar; 19, termination of nasal; 20, termination of infra-trochlear; 21, termination of supra-trochlear; 22, temporal branch of auriculo-temporal; 23, 24, supra-orbital.

intra-cranial and extra-cranial. The intra-cranial communicating branches are with the auditory; with Meckel's ganglion, by the large petrosal nerve, which passes through the hiatus Fallopii and joins the Vidian; with the otic ganglion, by the lesser petrosal nerve; with the

sympathetic plexus around the external carotid and middle meningeal arteries. The extra-cranial communicating branches are with the pneumogastric, glosso-pharyngeal, great auricular, carotid plexus, auriculo-temporal, and the fifth pair. The other branches of the facial are: 1. In the aquæductus Fallopii, the tympanic, distributed to the stapedius and laxator tympani. 2. Chorda tympani, given off from the lower part of the aquæductus Fallopii, enters the tympanic cavity through a small foramen at its posterior part. It arches upward between the handle of the malleus and incus, and emerges by a foramen near the anterior inferior angle of the tympanum, enters the canal of Huguier, which is parallel with the Glaserian fissure. It joins the gustatory and is distributed to the submaxillary gland and the mucous membrane of the tongue. The facial, as it appears at the side of the face, breaks up into a number of branches distributed to the several muscles, and sends off the digastric, stylo-hyoid, and temporal to these muscles. The posterior auricular, transverse facial, temporo-facial, and cervico-facial are distributed to muscles in these regions.

8. Auditory.—Arises below the seventh pair, from the same groove posterior to the olivary body, between it and the restiform body. It passes forward and outward with the facial and enters the internal auditory meatus, lying beneath the facial. It passes through the vertical cribriform plate of the internal meatus, divides into two sets of branches,—those distributed to the cochlea and those distributed to the semicircular canals. (See the Internal Ear.)

9. Glosso-pharyngeal.—Arises below the auditory, in the groove between the olivary and restiform bodies. Its deep origin is from the lower part of the floor of the

fourth ventricle. It passes through the posterior lacerated foramen, lies upon the stylo-pharyngeus and middle constrictor muscles, then runs along the inner surface of the hyoglossus muscle and is distributed to the mucous membrane of the tongue, pharynx, tonsils, and mouth. This nerve presents two ganglionic enlargements,—one just above the jugular foramen (the jugular ganglion), the other within the jugular canal (the petrosal ganglion). The branches of the glosso-pharyngeal are: the communicating, with the pneumogastric and sympathetic; the tympanic, which is distributed to the promontory of the tympanum; the muscular, and its terminal branches to the pharynx, palate, tonsils, and tongue.

10. Pneumogastric.—A motor and sensory nerve distributed to pharynx, larynx, heart, lungs, liver, and intestines. It arises by a series of fibres from the groove between the olivary and restiform bodies, below the origin of the glosso-pharyngeal. Its deep origin is from the floor of the fourth ventricle, close to the origin of the glosso-pharyngeal, and associated with the nucleus of the fifth pair. It passes out of the skull by the posterior lacerated foramen, and presents in this region two ganglia,—that of the root and that of the trunk, the latter situated just below the jugular foramen. The pneumogastric passes down the neck in the sheath of the carotid artery, between it and the internal jugular vein, but on a plane posterior to them, down to the sixth cervical vertebra, where its course on the two sides of the neck is different. On the right side the pneumogastric lies on the subclavian artery, and runs down along the right side of the trachea to its bifurcation; it passes behind the right bronchus to the posterior part of the œsophagus, passes through the œsophageal opening in the diaphragm, and is distributed to the stomach, forming

intimate anastomoses with the solar plexus. On the left side it enters the chest to the left of the common carotid, lies on the arch of the aorta, passes behind the root of the lung and down the anterior part of the œsophagus, to be distributed to the stomach, duodenum, and liver. The branches of the pneumogastric are divided into three sets,—cervical, thoracic, and abdominal. The cervical branches are: 1. The auricular, which enters a foramen in the jugular notch on the posterior inferior border of the petrous part of the temporal bone, and is distributed to the structures of the tympanum. It escapes by the auricular fissure, and is distributed to the integument of the ear. 2. A pharyngeal branch, which forms a plexus on the pharyngeal muscles. It is the motor nerve to the constrictors. 3. The superior laryngeal is the sensory nerve to the larynx, being distributed to the mucous membrane. 4. The recurrent laryngeal, on the right, winds around the innominate artery from before backward, and is distributed to the muscles of the larynx, which it animates. On the left side it lies in front of the arch of the aorta, and winds around its inferior border below the ductus arteriosus. It ascends to the larynx, and is distributed to the muscles of the corresponding side. 5. The cardiac branches, four or five in number, are distributed to the ganglia of the heart, lungs, and œsophagus. In the abdomen the pneumogastric is distributed to the stomach, omenta, liver, and communicates freely with the sympathetic ganglia.

11. Spinal Accessory.—Consists of two portions,—the upper, arising from the groove between the olivary and restiform bodies; lower, arising from the antero-lateral fissure of the cord by numerous filaments, and as low down as the third cervical vertebra. It enters the foramen magnum, arches over to the posterior lacerated

foramen, through which it passes to the upper inner part of the sterno-mastoid muscle, which it pierces, and is finally distributed to the trapezius. Its branches are communicating with glosso-pharyngeal, pneumogastric, and cervical nerves, and muscular branches to the sterno-mastoid and trapezius.

12. Hypoglossal Nerve.—Is the motor nerve of the tongue. It arises in the groove between the anterior pyramid and olivary body, above the plane of the pneumogastric. Its fibres of origin are numerous. The nerve passes through the anterior condyloid or hypoglossal foramen, descends deeply in the neck, and is distributed to the tongue-muscles. It sends off branches of communication to the pneumogastric, cervical, and sympathetic nerves, and a descending branch (the descendens noni), which forms a loop, on the anterior part of the sheath of the cervical vessels, with the communicans noni, formed by branches from the second and third cervical. From this loop branches pass to the sterno-hyoid, sterno-thyroid, and omo-hyoid muscles.

SPINAL NERVES.

There are 31 pairs of nerves that arise from the sides of the spinal cord. They are arranged in five regions:—

Cervical, ...	8 pairs.
Dorsal, ...	12 "
Lumbar, ...	5 "
Sacral, ...	5 "
Coccygeal, ...	1 pair.

They arise by two roots,—an anterior or motor, from the antero-lateral fissure, and a posterior or sensory or ganglionic, from the postero-lateral fissure. The anterior roots are the smaller. The posterior or larger has a ganglion on it. The two roots unite in or near the

intervertebral foramina and form a mixed nerve, which divides into posterior smaller and anterior larger branches, the latter forming the plexuses from which the nerves are derived that are distributed to the periphery.

Cervical Nerves.

The first cervical emerges from the spinal canal above the atlas; the last cervical, between the last cervical and first dorsal vertebra. The anterior branches of the upper four cervical nerves unite to form the cervical plexus, which rests upon the levator anguli scapulæ and scalenus anticus muscles. It is formed by communicating filaments passing from the first to second, second to third, third to fourth nerves, and sends off two sets of branches,—superficial and deep. The superficial branches are divided into the ascending and descending. The ascending branches are:—

1. Superficialis colli, from second and third cervical; winds around the posterior border of sterno-mastoid and is distributed to the side and anterior part of the neck.

2. Auricularis magnus, from second and third cervical; winds around posterior border of sterno-mastoid and divides into branches to the face, ear, and occiput. It is the largest superficial branch.

3. Occipitalis minor, from second cervical; winds around posterior border of sterno-mastoid and is distributed to the occipital region.

The descending branches are the sternal, clavicular, and acromial, to the regions named.

The deep branches of the cervical plexus are:—

1. The phrenic—the most important—from the third and fourth cervical; runs down the neck, lying on the scalenus anticus, then on the subclavian artery, descends

in the middle mediastinum by the side of the pericardium, and is distributed to the diaphragm.

2. Communicans noni, from second and third cervical; joins the descendens noni on the sheath of the cervical vessels.

3. Communicating, with cranial nerves.

4. Muscular, to cervical muscles.

The posterior division of the cervical nerves communicate but irregularly, and are distributed to the muscles and integument at the back of the neck.

Brachial Plexus.

The brachial plexus rests upon the scalenus medius muscle, and is formed by the anterior branches of the fifth, sixth, seventh, and eighth cervical nerves and first dorsal. In one hundred dissections of this plexus, made during the last twelve years, and which were photographed, I do not find any two photographs alike. The arrangement of the plexus can best be understood by the following formula: 3 nerves + 2 nerves = 2 trunks + 3 cords,—or, briefly, 3N + 2N = 2T + 3C. In explanation, let it be remembered that five spinal nerves enter into the brachial plexus; that the fifth, sixth, and seventh unite to form the upper trunk; and that the eighth cervical and first dorsal unite to form the lower trunk; here we get 3N + 2N, which equals the sum of 5. Draw a line through the plexus internal to the two trunks formed by the five nerves, thus:—



and the rest of the formula becomes clear, forming 2 trunks plus 3 cords, or in full (3N + 2N = 2T + 3C), and from the cords the principal branches of the brachial plexus are given off. The figure 5 is the key to the plexus. The branches of the brachial plexus are divided into those given off above the clavicle and those below. Those above the clavicle are:—

1. Muscular, to muscles of neck.

2. Communicating, a filament from fifth cervical to phrenic.

3. External respiratory, from the fifth and sixth cervical; supplies serratus magnus muscle.

4. Supra-scapular, from fifth and sixth cervical; runs through the supra-spinous foramen, supplying the posterior scapular muscles.

Below the clavicle the branches are numerous, and are distributed to the trunk and shoulder and the arm, forearm, and hand. They are:—

1. The anterior thoracic, two or three in number, arise from the upper and lower cords, and are distributed to the chest-muscles.

2. The circumflex, arises from the posterior cord, winds around the neck of the humerus, and is distributed to the shoulder-joint, deltoid, teres minor, and integument.

3. The subscapular, two or three branches from the posterior cord, supply the subscapular muscles.

4. The external cutaneous, from the outer cord of brachial plexus, pierces the coraco-brachial muscle, passes beneath the biceps, and appears beneath the mediocephalic vein. It supplies the elbow-joint and integument of elbow along outer side of forearm.

5. The median is formed by a branch from the outer and one from the inner cord. These unite and form the

nerve, which passes down the median line of the arm and forearm, beneath the anterior annular ligament; it is ultimately distributed to the palmar surface of all the digits except the little finger and adjoining side of ring-finger. It sends off numerous branches in the forearm to the muscles and the anterior interosseous, which runs along the median line of the interosseous membrane and supplies the deep muscles. It terminates beneath the pronator quadratus in a ganglion.

6. The ulnar is the continuation of the inner cord, and runs along the inner side of arm, passes behind the internal epicondyle, along the ulnar side of forearm, and terminates in the skin of the little finger and adjoining side of ring-finger. The ulnar sends off numerous branches to the muscles of the forearm and the integument, along the inner side of forearm and hand.

7. The internal cutaneous, a small branch from the inner or lower cord, runs down the inner side of arm, becomes subcutaneous, passes over the medio-basilic vein, and is distributed to the integument of inner and posterior part of forearm.

8. The lesser internal cutaneous, or nerve of Wrisberg, arises from the inner cord above the internal cutaneous. It is commonly joined by a branch from one of the intercostal nerves, called the intercosto-humeral. It is distributed to the integument along the inner side of elbow and forearm.

9. The musculo-spiral is the continuation of the posterior cord, and is the largest branch of the plexus. It runs downward and outward, winds around the humerus from within backward, lying in the musculo-spiral groove, and descends between the origins of the brachialis anticus and supinator longus muscles to the elbow, where it divides into the radial and posterior interosse-

ous. The radial nerve accompanies the radial artery, and is distributed to the muscles of the forearm and thumb, and to the integument of the dorsal surface of the thumb, index, and middle fingers. The posterior interosseous pierces the supinator brevis, and descends deeply along the posterior part of forearm, and terminates above the wrist-joint in a ganglionic enlargement. The musculo-spiral nerve sends off branches to the muscles of the forearm and cutaneous branches to the integument in the region of the elbow along its outer side.

Dorsal Nerves.

The dorsal nerves are smaller than any other spinal nerves except the last sacral and coccygeal. They consist of twelve pairs. The last pair emerge between the last dorsal and first lumbar vertebra. They arise from the cord on a higher plane than the foramina through which they pass and divide into an anterior and posterior branch. The anterior form the intercostal nerves. They run between the intercostal muscles, send off a number of branches to the wall of the chest, and terminate near the sternum in the cutaneous branches, which supply the skin and superficial structures at the anterior part of chest. The posterior branches are distributed to the muscles of the back and the integument.

Lumbar Nerves.

The lumbar nerves are five in number. The last lumbar makes its exit between the last lumbar vertebra and sacrum. The roots are very long and large, and unite in the intervertebral foramina. As they emerge they divide into smaller posterior and larger anterior branches. The posterior branches are distributed to the muscles of the back and the integument in this and the gluteal region. The upper four lumbar nerves form the

Lumbar Plexus.

A communicating branch passes from the first to the second; others from the second to the third and from the third to the fourth. The branches of the plexus are:—

1. The ilio-hypogastric and the ilio-inguinal, from the first lumbar nerve.

2. The genito-crural and a branch to the external cutaneous and a large branch to the anterior crural from the second lumbar nerve.

3. The external cutaneous and anterior crural and a branch to the obturator from the third lumbar nerve.

4. The obturator, accessory obturator, a branch to anterior crural, and a connecting branch to the fifth lumbar from the fourth lumbar nerve.

The plexus is imbedded deeply in the substance of the psoas magnus muscle.

1. The ilio-hypogastric, from first lumbar, runs along the inner surface of the posterior wall of the abdominal cavity, pierces the transversalis, and is distributed to the integument of the gluteal and hypogastric regions.

2. The ilio-inguinal, from the first lumbar below the ilio-hypogastric, follows the inguinal canal and is distributed to the integument of pubes, scrotum, and groin.

3. The genito-crural runs along the anterior surface of the psoas magnus. It arises from the second lumbar. It is distributed to the cremaster muscle in the male, and the round ligament in the female. Another branch supplies the skin along the inner part of the thigh.

4. The external cutaneous, from the third lumbar, receives a branch from the second lumbar. It runs along the crest of the ilium and appears just below the attachment of Poupart's ligament to the spine of the ilium. It is distributed to the skin along the outer and anterior part of the thigh.

5. The anterior crural is the longest branch of the lumbar plexus. It arises from the third lumbar and receives branches from the second and fourth lumbar. It descends in the substance of the psoas near the outer border and emerges a short distance above Poupart's ligament, passes beneath Poupart's ligament external to the femoral artery, and is distributed to the muscles and integument of the anterior part of the thigh. The anterior crural sends off superficial and deep branches. The superficial are the middle cutaneous, distributed to the skin along the anterior part of thigh, and the internal cutaneous, distributed to the skin along the inner part of the thigh. The deep branches are the long saphenous, which accompanies the femoral artery as far as Hunter's canal and is distributed to the integument of the inner part of the knee-joint and inner side of leg. It accompanies the long saphenous vein as far down as the foot. The other deep branches are the muscular and articular, the latter being distributed to the knee-joint.

6. The obturator from the fourth lumbar receives a branch from the third. It runs along the inner border of the psoas, passes through the obturator foramen, and is distributed to the integument along the inner part of the thigh near the knee-joint. It sends off a small branch to the hip-joint.

7. The accessory obturator arises by two filaments from the fourth lumbar. These frequently unite and the nerve is distributed to the skin of the pubes. It is sometimes wanting.

8. The fifth lumbar nerve is called the lumbo-sacral cord. It receives a filament of communication from the fourth lumbar, and curves down into the pelvis to join the sacral plexus. It is the largest communicating nerve in the entire spinal series.

Sacral Nerves.

The sacral nerves are five in number. The upper four emerge from the anterior and posterior sacral foramina. The fifth sacral, which is very small, makes its exit between the sacrum and coccyx. The sacral nerves are derived from the cauda equina and have the longest roots. Their upper three are large; the fourth is small. Their anterior divisions unite with the lumbo-sacral cord to form the sacral plexus.

Sacral Plexus.

This plexus is simple in construction, being formed by the union of the lumbo-sacral cord, first sacral, second sacral, and third sacral, with some filaments from the fourth sacral nerve, in a large, broad, flat band of nerve-fibres one inch wide, which sends off the following branches:—

The *great sciatic* is the largest nerve in the body. It is practically the continuation of the sacral plexus and emerges from the pelvis by the greater sacro-sciatic foramen below the pyriform muscle. It passes down the posterior median part of the thigh and leg into the foot, and is distributed to the muscles of the posterior part of the thigh and of the leg and foot, and also supplies the skin of nearly the entire lower extremity with sensation. Its branches are articular to the hip-joint, muscular, and it divides above the popliteal space into internal popliteal the larger and external popliteal the smaller branch.

The internal popliteal descends through the middle of the popliteal space to the leg, where it lies upon the deep muscles. It sends off cutaneous and muscular branches and the external saphenous, which is distributed to the integument at the back of the calf of the leg. It

receives a communicating branch, called the communicans peronei, from the external popliteal. The posterior tibial, the continuation of the internal popliteal, descends upon the deep muscles of the leg to the inner malleolus, where it divides into the internal and external plantar. It sends branches to the muscles of the leg. The internal plantar is between the first and second layers of the muscles of the foot, and is distributed to the four inner

FIG. 141.—DIGITAL NERVES AND THEIR TRUNK CONNECTIONS.
A, internal plantar; B, external plantar; C, deep branch of external plantar; D, first digital; E, second digital; F, third digital; G, fourth digital; H, fifth digital; I, external digital; 1, branches to first toe; 2, branches to second toe; 3, branches to third toe; 4, branches to fourth toe; 5, branches to fifth toe.

toes. The external plantar, the smaller, is distributed to the little toe and adjoining side of the fourth toe.

The external popliteal runs along the outer part of the popliteal space behind the tendon of the biceps, winds around below the head of the fibula, and descends along the anterior surface of the interosseous membrane as the anterior tibial. It sends off a cutaneous branch to communicate with the short saphenous, called the communicans poplitei, or peroneal. The anterior tibial sends off

muscular, cutaneous, and articular branches, the latter to the ankle-joint, and is distributed to the dorsal surface of the foot and toes. It sends off also the musculo-cutaneous, which arises near the upper third of the leg, pierces the peronei muscles, and is distributed to the muscles along the outer side of the leg and the integument as far down as the dorsum of the foot.

The *small sciatic* passes through the greater sacro-sciatic foramen with the great sciatic nerve, and supplies the gluteus maximus and the integument of the perineum and inner part of thigh. It becomes cutaneous, and is distributed to the lower part of thigh and upper part of leg.

The *pudic nerve* passes through the greater sacro-sciatic foramen to the inner side of small sciatic. It winds around the outer part of the spine of the ischium, enters the lesser sacro-sciatic foramen, and runs forward and upward along the inner surface of the inferior border of the rami of the ischium and pubes. It sends off the inferior hæmorrhoidal, which crosses the ischio-rectal fossa and is distributed to the lower part of the rectum. The perineal is distributed to the structures of the perineum. It divides into several branches, which supply the muscles and integument. The dorsal nerve of the penis passes forward with the vessels, and is finally distributed to the glans, prepuce, and skin of the penis. In the female this nerve is distributed to the glans clitoridis and associate parts.

The superior gluteal leaves the pelvis above pyriform muscle, and divides into several branches, which supply the glutæus minimus, medius, and tensor vaginæ femoris.

The muscular branches are distributed to the pelvic muscles, the gemelli, and quadratus femoris.

The articular are small branches to the ilio-sacral articulations.

THE SYMPATHETIC.

The sympathetic serves to connect and bind the several parts of the body sympathetically together. It consists of a number of ganglia placed at each side of the spinal column, and connected together by communicating fibres. Each ganglion consists of an investing fibrous membrane, and from this are given off delicate fibrous septa, forming a neuroglia for the support of the nerve cells and fibres. In each ganglion there are groups of multipolar cells, naked axis-cylinders, the fibres of Remak, and ordinary nerve-fibres. The ganglia are connected together chain-like by interganglionic nerve-fibres, and receive a number of branches from the cerebro-spinal system. The branches of distribution are frequently arranged in the form of plexuses on the blood-vessels, and to the viscera. Excluding the sympathetic ganglia associated with the fifth pair of nerves and previously considered, there are three pairs of ganglia in the cervical, twelve pairs in the dorsal, four pairs in the lumbar, four or five pairs in the sacral, and one terminal ganglion placed at the side of the third coccygeal vertebra. The superior cervical ganglion lies on the anterior surface of the rectus capitis anticus major, and behind the deep cervical vessels. It sends branches in every direction, and forms the carotid and cavernous plexuses. Just above the anterior communicating artery, the sympathetic chains communicate, forming the ganglion of Ribes. The superior cervical ganglion sends off the superior cardiac nerve to the cardiac plexus. The second or middle cervical ganglion, placed to the side of the fifth cervical vertebra, rests upon the anterior surface of the scalenus medius muscle. Its most important branch is the middle cardiac, the largest

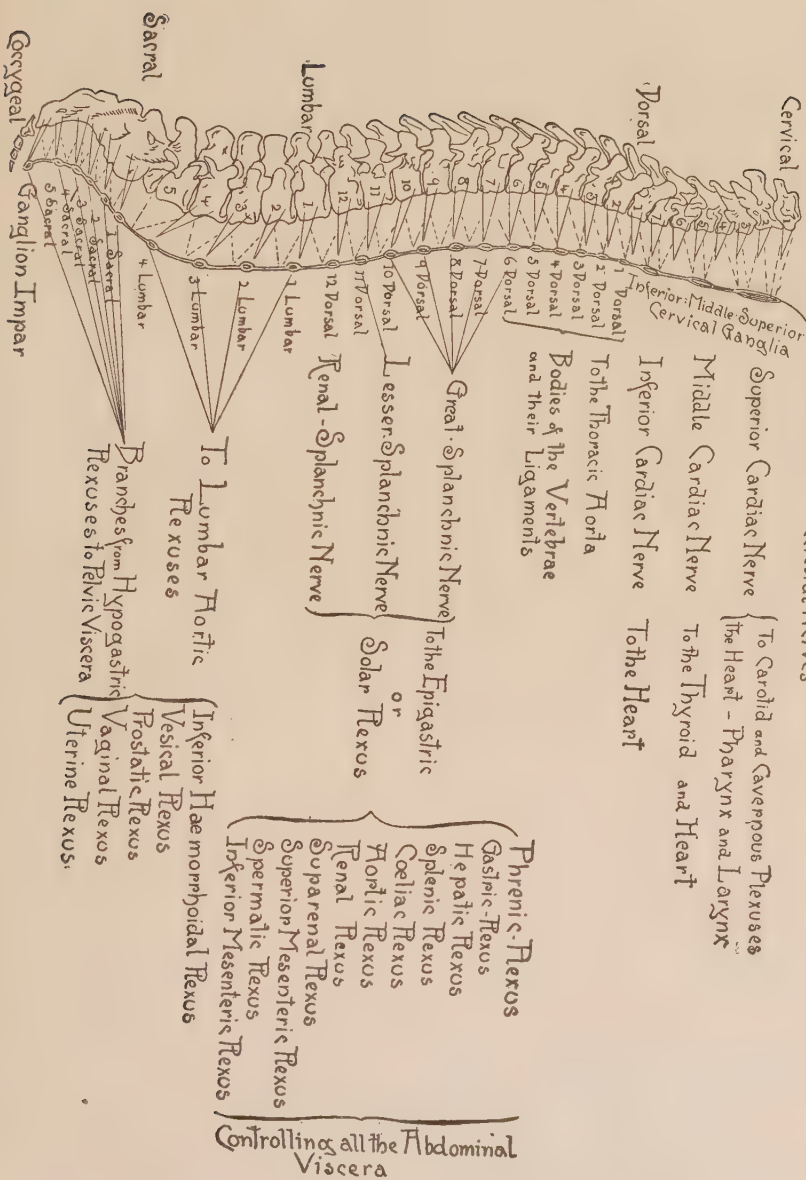

FIG. 142.—DIAGRAM OF THE SPINAL SYMPATHETIC NERVOUS SYSTEM AND CONNECTIONS.

of the cardiac. It is distributed to the deep cardiac plexus. The third or inferior cervical ganglion is placed at the side of the seventh cervical vertebra, and rests on the neck of the first rib. Its most important branch is the inferior cardiac, and is distributed to the deep cardiac plexus.

The sympathetic ganglia of the thorax consist of a chain of ganglia placed on either side of the spinal column, resting on the heads of the ribs and covered by the pleura. Their branches are distributed in every direction. The most important are the greater splanchnic, lesser splanchnic, and renal splanchnic. The greater splanchnic arises by filaments from the lower six dorsal ganglia. It is a nerve of considerable size, white in color, descends, and pierces the crus of the diaphragm, and terminates in the solar plexus. The lesser splanchnic arises from the ninth and tenth ganglia, accompanies the greater splanchnic, and enters the solar plexus. The renal splanchnic, often wanting, arises from the lower two dorsal ganglia, and terminates in the renal plexus.

The solar plexus is a great sympathetic ganglion, which surrounds the cœliac axis. It is formed by two semilunar ganglia and connecting fibres, and these receive the splanchnics and termination of the pneumogastrics. The solar plexus sends branches in all directions and forms retiform plexuses around all of the branches of the abdominal aorta. It is through the blood-vessels that the sympathetic reaches the viscera.

The lumbar part of the sympathetic presents four ganglia placed at the side of the spine, internal and posterior to the psoas. Its branches are freely distributed to the vessels and viscera. The sacral ganglia, four or five in number, are placed along the inner line of the

anterior sacral foramina, and converge as they meet to join in the terminal ganglion, or ganglion Impar. They send numerous branches to the pelvic vessels and viscera, and form secondary plexuses such as the superior hypogastric, placed between the iliac arteries anterior to the sacrum. The inferior hypogastric plexus is imbedded in the substance of the perineum, and sends branches to the rectum, prostate, bladder, and corpora cavernosa in the male, or the clitoris, vagina, and uterus in the female.

In the heart, uterus, kidney, intestines, and other organs there are numerous sympathetic ganglia distributed through the substance of the viscera. About the heart there are three well-defined plexuses which communicate with the cervical sympathetic ganglia through the cardiac nerves. They are also intimately connected with the pneumogastrics and spinal nerves.

THORACIC VISCERA.

THE THORAX.

The thorax is the osseo-cartilaginous case which contains the heart and lungs. In shape it is the frustum of a cone compressed antero-posteriorly, and it is due to this antero-posterior flattening that man in conditions of extreme relaxation gravitates upon the back. In the lower animals, as a rule, the chest is flattened from side to side, and under similar conditions, or at death, they rest upon the side.

It is supported posteriorly by the spine, formed anteriorly by the sternum, and front and back and at the sides by the ribs. The construction of the thorax is such as to enable the ribs to rotate on their axes and enlarge the transverse diameters of the chest. The upper opening of the thorax is formed by the first ribs, sternum, and first dorsal vertebra. It is nearly circular in form, and transmits the trachea, œsophagus, great vessels and nerves, and some muscles.

The lower opening is very large and irregular. It is formed by the last dorsal vertebra, the twelfth ribs, the apices of the eleventh ribs, the costal cartilages of the sixth, seventh, eighth, ninth, and tenth ribs, and the ensiform cartilage. Stretched across it is the diaphragm, which separates the thoracic from the abdominal cavities. The antero-posterior diameter of the chest is two-thirds the transverse. It is deeper posteriorly than anteriorly, the ensiform cartilage being on a level with the ninth dorsal vertebra; the upper border of the sternum is on a

level with the second dorsal vertebra. In the intervals between the ribs are the intercostal muscles.

Posteriorly the thoracic cavity is concave along the spine, and along either side of it are the broad, concave, posterior walls formed by the ribs. The sternum is directed obliquely downward and forward.

THE HEART.

The heart lies near the centre of the chest and is invested by a strong, loose, fibro-serous sac, the pericardium.

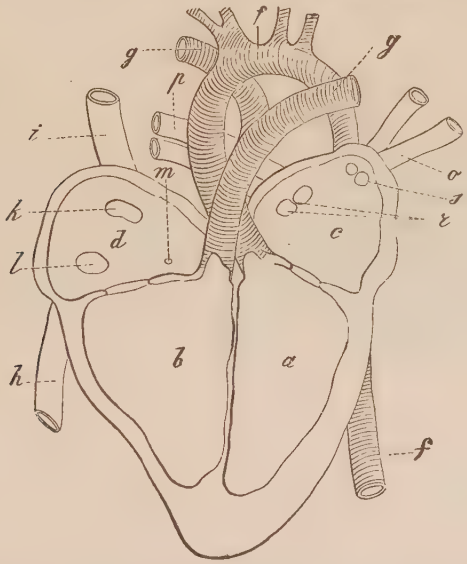

FIG. 143.—DIAGRAM OF THE HEART.

a, left ventricle; b, right ventricle; c, left auricle; d, right auricle; f, aorta; g, g, pulmonary arteries; h, inferior vena cava; i, superior vena cava; k, orifice of the superior vena cava; l, orifice of inferior vena cava; m, orifice of coronary vein; o, left pulmonary veins; p, right pulmonary veins; r, orifices of right pulmonary veins; s, orifice of left pulmonary veins.

That portion of the chest-cavity posterior to the pericardium is called the posterior mediastinum, that portion in front the anterior mediastinum; the heart lies in the middle mediastinum.

The pericardium is a loose, fibro-serous sac, which contains the heart and origin of the great vessels, to

which it is closely adherent. The serous lining of the pericardium consists of two layers,—the visceral and parietal. The visceral layer closely invests the heart and roots of the great vessels, and is reflected on the inner surface of the fibrous layer of the pericardium. Both parietal and visceral surfaces are smooth and glistening. A small amount of fluid is found within the sac.

The heart is contained within the pericardial sac. It is a hollow, muscular organ, conical in form, and situated in the middle mediastinum between the two lungs. It is placed obliquely, the base is above, the apex below, and it extends from the right third costo-sternal articulation to the fifth intercostal space on the left side, about one and one-half inches to the left of the sternum. It is held in position by the great vessels which spring from its base, and is entirely free to move throughout the rest of its extent. It is about five inches long, three inches transversely, and two and one-half inches antero-posteriorly; roughly speaking, it is about the size of the fist. It weighs from eight to ten ounces in the female and from nine to eleven ounces in the male. It consists of two ventricles and two auricles; the auricles, right and left, are two cuboidal sinuses, which receive the blood; below these are placed the ventricles, which force the blood into the pulmonary artery and aorta. A vertical sep-

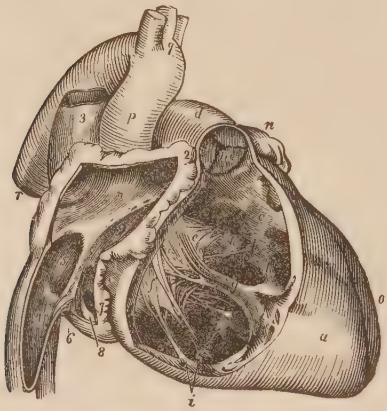

FIG. 141.—RIGHT SIDE OF HEART, RIGHT AURICLE AND RIGHT VENTRICLE LAID OPEN.

a, apex; b, right ventricle; d, pulmonary artery; e, f, chordæ tendinæ; p, aorta; 3, superior vena cava; 5, inferior vena cava.

tum divides the heart into a right, or venous, and a left, or arterial side. The right auricle is a cuboidal blood-sinus, into which empty the descending and ascending venæ cavæ. It presents a principal sinus and an appendix. Its walls are about as thick as stout wrapping-paper, and present on their inner surface five openings, two valves, and some relics of fœtal structure.

The openings are:—

Superior Vena Cava.—The large venous trunk which drains the upper half of the body. It opens into the upper anterior part of the auricle, the axis of

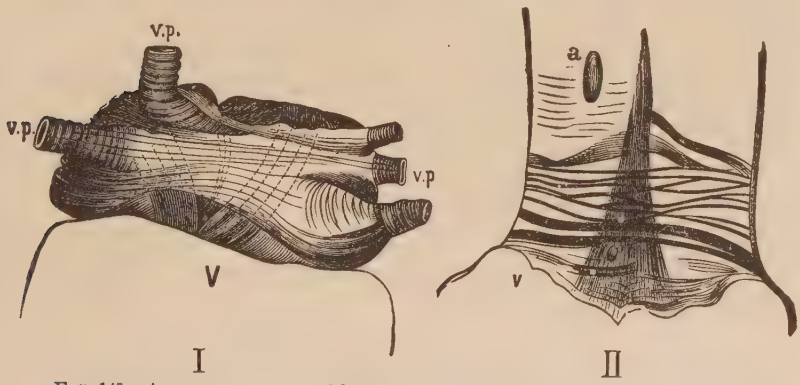

FIG. 145.—ARRANGEMENT OF MUSCULAR FIBRES AROUND THE AURICLES AND GREAT VEINS.

I, muscular fibres on the left auricle; v.p., fibres on the pulmonary veins; V, the left ventricle. II, muscular fibres on the superior vena cava; a, opening of vena azygos; v, auricle.

its current being anterior to that of the ascending vena cava and directed to the tricuspid opening. Around the openings of the vena cava the circular fibres of the auricles are reduplicated, but there are no valves.

Inferior Vena Cava.—Returns the blood of the lower half of the body. The axis of its current lies behind that of the superior vena cava and is directed against the septum auricularum.

The opening of the *coronary sinus* is to the right of the tricuspid opening. It drains the blood from the

heart, and is protected by the coronary valve,—a semilunar fold of the endocardium. It opens into the auricle. The sinus will admit the end of the little finger, is about one and one-half inches long, and is formed by the right and left coronary and oblique veins of the heart.

The *foramina thebesii* are numerous minute openings of the small veins of the auricles.

The right *auriculo-ventricular* or tricuspid opening is the opening from the auricle into the ventricle; it will admit the ends of three fingers, and measures accurately four and five-sixths inches; it is the largest opening at the base of the heart, and is strengthened by a strong ring of white fibrous tissue, which affords attachment to the tricuspid valves and gives origin to the muscular layers of the heart.

The *Eustachian valve* is a semilunar fold of the endocardium, extending between the anterior margin of the ascending vena cava and the tricuspid opening. In the fœtus it helps to direct the column of blood toward the foramen ovale.

On the septum between the auricles is an oval depression, the *fossa ovalis*, which corresponds to the position of the foramen ovale in the fœtus; it is surrounded by an elevated margin, the *annulis ovalis.*

The *auricular appendix* is an ear-like extension of the right auricle. It passes to the left and lies upon the root of the pulmonary artery. It presents a number of cylindrical interlacing bundles of muscular fibres, forming the *musculi pectinati.*

The Right Ventricle.

The right ventricle is placed immediately below the right auricle. It is conoidal in form; its walls are about three-sixteenths of an inch thick. It presents two open-

ings, the tricuspid and pulmonary; two valves, the tricuspid and semilunar; the columnæ carneæ and chordæ tendineæ.

The tricuspid opening has been described.

The pulmonary opening is the constricted orifice at the summit of the right conus arteriosus. It will admit the thumb, and measures accurately three and one-half inches in circumference.

The *tricuspid valves* consist of three leaflets,—the inner, between the pulmonary orifice and tricuspid opening; the anterior, and posterior. Their edges are joined together at their attachment to the tricuspid fibrous ring. They are formed by a reduplication of the endocardium and re-inforced by bundles of fibrous tissue. Each leaflet is triangular in form and is attached by its free end to the chordæ tendineæ, which are inserted at three different places on the valve,—first, on the central thickened part of the valve; second, on the free margin of the valve; third, on the valve at its insertion into the tricuspid fibrous ring.

The *semilunar* valves are three semilunar folds or festoons of the endocardium, placed at the beginning of the pulmonary artery; they open into the vessel, have thickened edges, and present at their middle a fibro-cartilaginous nodule, the corpus Arantii, which serves to close the valve perfectly, thus preventing regurgitation.

The *columnæ carneæ* are bundles of muscular fibres disposed in three different ways. Some are mere ridges on the inner surface of the ventricle, others are attached by their two extremities, and the third set are attached by one extremity to the ventricle; the other is continued as a tendinous cord (the chordæ tendineæ) to the valve.

The *left auricle* is smaller than the right; its walls

are thicker; it is a cuboidal sinus, with an auricular extension to the right and across the root of the pulmonary artery; it presents the openings of the pulmonary veins and the mitral opening.

The four openings of the pulmonary veins are at the upper posterior part of the auricle; they have no valves, but the circular fibres of the auricle are disposed around them as a thickened layer, and prevent, in a measure, the reflux of blood.

The left *auriculo-ventricular* or mitral opening will admit two fingers; accurately, it measures three and eleven-twelfths inches. It is strengthened by a fibrous ring, which surrounds it and affords attachment to the mitral valve and the layers of the muscular fibres of the left ventricle. In the interior of the appendix auriculæ are the musculi pectinati, arranged as on the right side; on the septum auricularum is the reverse of the annulus and fossa ovalis.

The Left Ventricle.

The left ventricle, longer, but less capacious, than the right, forms the posterior part and apex of the heart. Its walls are from one-third to one-half inch thick, and thickest about the middle of the ventricle. It presents for examination the

Auriculo-ventricular or *mitral* opening, which is to the left of the aortic opening. It will admit two fingers, and measures accurately three and eleven-twenty-fourths inches. It is strengthened by a strong ring of fibrous tissue, to which are attached the mitral valves and the muscular layers of the heart.

The *aortic* opening, at the summit of the left conus arteriosus, will admit the index finger, and measures accurately three and one-sixth inches. It is surrounded by a strong ring of fibrous tissue, which affords attachment

to the semilunar valves, aorta, and muscular structures of the heart.

The *semilunar* valves, three in number, are formed by the reduplication of the endocardium, and consist of three festoons with a central fibro-cartilaginous nodule —the corpus Arantii—on each. They are much stronger than on the right side.

The mitral valves guard the auriculo-ventricular orifice. They are triangular leaflets of the endocardium attached to the fibrous ring around the mitral orifice; they are united by their edges for a short distance, and

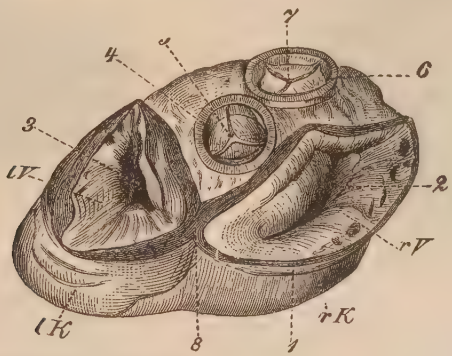

FIG. 146.—BASE OF THE HEART, BOTH AURICLES REMOVED.
rV, right auricle; lV, left auricle; rK, right ventricle; lK, left ventricle; 1, coronary furrow; 2, right, 3, left auriculo-ventricular; 4, origin of the aorta; 5, aortic semilunar valves; 6, origin of the pulmonary artery; 7, its semilunar valves; 8, auricular septum.

are held in place by the chordæ tendineæ. One leaflet is placed between the mitral and aortic orifices; the other, to the left of the mitral opening. The chordæ tendineæ are attached as on the right side.

The *columnæ carneæ* are stronger and larger than on the right side, but are disposed in a similar manner.

The *conus arteriosus* of each ventricle is the funnel-shaped approach to the pulmonary and aortic openings. These openings are the most constricted part of the conus arteriosus of either ventricle. They are smooth throughout and lined by tightly adherent endocardium.

The *endocardium* is the serous lining of the heart and is continuous with the inner coat of the great vessels. It is considerably modified where it enters into the formation of the valves, being in these situations re-inforced by bundles of fibrous tissue and some muscular fibres. It lines the interior of the ventricle, columnæ carneæ, and chordæ tendineæ.

The structure of the heart consists of planes of mus-

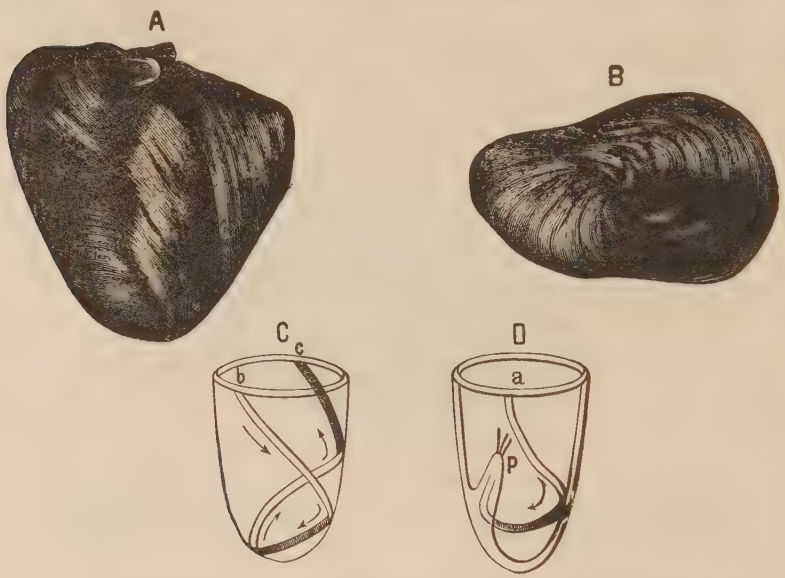

FIG. 147.—COURSE OF THE MUSCULAR FIBRES OF THE HEART.

A, on the anterior surface; B, view of the apex with the vortex; C, course of the fibres within the ventricular wall; D, fibres passing into a papillary muscle.

cular fibres arranged so as to effectually empty the cavities of the heart and exert sufficient force to drive the blood through all parts of the vascular system. These planes of muscular fibres arise from the fibrous rings at the base surrounding the auriculo-ventricular, pulmonary, and aortic orifices. They are divisible into three principal layers: the oblique, transverse, and spiral. The transverse layer is thick and strong and encircles the

two ventricles; in like manner the two auricles are surrounded by a transverse plane of muscular fibres. Ultimately the fibres are lost upon the cardiac septa and in the columnæ carneæ, thence to be inserted by the chordæ tendineæ upon the valves. The muscular fibre of the heart is not invested by sarcolemma and consists of striated, branched, and nucleated fibres.

THE LARYNX.

The larynx is placed in the median line on the upper part of the trachea. It is a pyramidal box composed of cartilages, fibrous tissue, and muscles. The cartilages are nine in number: three single,—thyroid, cricoid, and epiglottis; and three pairs, —arytenoid, cuneiform, and cornicula laryngis.

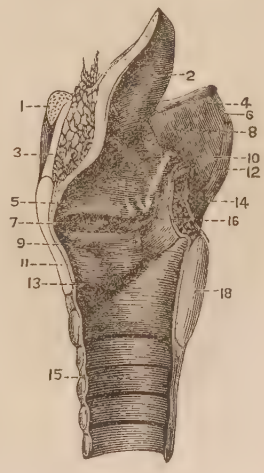

FIG. 148.—VERTICAL SECTION OF LARYNX.

1, body of hyoid bone; 2, epiglottis; 3, thyro-hyoid membrane; 4, great cornu of hyoid; 5, false vocal cord; 6, thyro-hyoid ligament; 7 ventricle of larynx; 8, thyro-hyoid membrane; 9, true vocal cord; 10, aryteno-epiglottidean fold; 11, thyroid cartilage; 12, superior cornu of thyroid; 14, arytenoides muscle; 16, arytenoid cartilage; 18, coracoid cartilage.

The *thyroid* consists of two quadrilateral plates of cartilage united in front at an acute angle. Each plate is smooth and the posterior border terminates in the superior and inferior cornua. The angle of junction forms a projection at the anterior part of the neck called the pomum Adami, or Adam's apple.

The *cricoid* is a ring of cartilage shaped like a seal-ring, the narrow part in front. Posteriorly it presents two superior facets for the arytenoid cartilages, and laterally a facet for articulation with the thyroid.

The *epiglottis* is a leaflet of yellow-fibre cartilage which is attached to the receding angle between the two plates of the thyroid. Its normal position is vertical, but

on elevation of the larynx, as in swallowing, it is depressed and serves to cover the glottis.

The *arytenoid* cartilages are trilateral pyramids which rotate on their bases. They are placed upon the upper posterior part of the cricoid. Upon the apex of each cartilage is placed a small nodule of fibro-cartilage, the cornicula laryngis. The cuneiform are two plates of cartilage placed in the aryteno-epiglottidian folds.

The ligaments of the larynx are intrinsic and extrinsic; the *extrinsic* are the two thyro-hyoid ligaments which connect the superior cornua of the thyroid cartilage with the greater cornua of the hyoid bone and the thyro-hyoid membrane, which is stretched between the upper border of the thyroid cartilage and the inferior border of the hyoid bone. The intrinsic ligaments are: The crico-thyroid membrane, passes between the inferior border of the thyroid cartilage and superior border of the cricoid, and is composed of yellow elastic tissue; two capsular ligaments, for the crico-thyroid articulations: two capsular crico-arytenoid ligaments. These ligaments are much thicker posteriorly. The two epiglottic ligaments from the posterior part of the body of the hyoid to the anterior surface of the epiglottis are a plane of elastic fibres. The thyro-epiglottic ligament is a long, narrow band of elastic fibres, which runs from the upper part of the epiglottis to the inner surface of the thyroid cartilage near the median line. The glosso-epiglottic folds, formed by the reduplication of the mucous membrane, are the two lateral and the median.

The muscles of the larynx consist of eight pairs. They are those which control the vocal cords and those of the epiglottis. The muscles of the vocal cords are:—

Crico-thyroid.—From side of cricoid; passes backward, and is inserted into the side of thyroid.

Posterior Crico-arytenoid.—From posterior broad surface of cricoid into angle of arytenoid.

Lateral Crico-arytenoid.—From side of cricoid beneath the cover of the thyroid into outer angle of arytenoid.

Arytenoid.—Three sets of fibres, right and left oblique and transverse between the arytenoids.

Thyro-arytenoid.—From anterior angle of arytenoid to receding angle of thyroid.

Those of the epiglottis are:—

Thyro-epiglottic.—Inner surface of thyroid to epiglottis.

Superior Aryteno-epiglottic.—Fibres pass from arytenoid to epiglottis in aryteno-epiglottic folds.

Inferior Aryteno-epiglottic.—From arytenoid to side of larynx, over the sacculus laryngis.

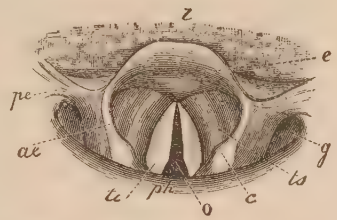

FIG. 149.—THE HUMAN GLOTTIS.

l, tongue; e, epiglottis; pe, pharyngo-epiglottic fold; ae, aryteno-epiglottic fold; ph, posterior wall of pharynx; c, cartilage; ts, superior thyro-arytenoid fold; ti, inferior fold; o, glottis.

Within the larynx are also several folds arranged in pairs. The aryteno-epiglottic inclose the fibres of the aryteno-epiglottic muscles. These folds form the sides of the inlet to the larynx, which is broad in front, where it is completed by the epiglottis; narrow behind, where it is formed by the apices of the arytenoid cartilages. Immediately below this fold is the cavity of the laryx, which is limited below by the inferior border of the cricoid cartilage. It is traversed on each side, from front to back, by the superior or false and the inferior or true vocal cords. The false vocal cords are formed by the thyro-arytenoid muscles, which are covered by the

mucous membrane lining the larynx. Below the false are the true vocal cords, formed of yellow elastic tissue and invested by mucous membrane. They are attached closely together in the receding angle of the thyroid cartilage; they pass horizontally backward and are inserted on the anterior angles of the arytenoids; each vocal cord is about one-sixth of an inch wide and about five-eighths of an inch long, but susceptible, by virtue of its elasticity, of considerable elongation. Between the false and true vocal cords is the ventricle of the larynx, a depression which communicates with the sacculus laryngis, a large mucous crypt; upon its surface the fibres of the inferior thyro-epiglottic muscles are distributed. The mucous membrane of the larynx continues with that of the trachea, mouth, and pharynx, is reflected over all the structures in the larynx. On the true vocal cords it is very thin and tightly adherent; above the false cords it is covered principally by squamous epethelium; below, it is of the ciliated variety.

THE TRACHEA.

The trachea, or wind-pipe, is a membrano-cartilaginous, cylindrical tube about five inches long, and extends from the fifth cervical to the third dorsal vertebra. It is about three-fourths of an inch in diameter, and terminates below in the right and left bronchi. The right is short, wide, and nearly horizontal in direction; the left is long, narrow, and oblique. If a section be made just above the bifurcation of the trachea, a septum is observed to extend upward between the two bronchi; it inclines to the left; in fact, it looks as if the right bronchus were continued or thrust into the trachea. This arrangement explains the tendency of foreign bodies to lodge in the right bronchus. The trachea consists of

sixteen to twenty incomplete cartilaginous rings connected by fibrous tissue and muscular fibres; the deficiency of the rings is posterior. In the interval between their ends extends the trachealis muscle, a band of involuntary muscular fibres disposed longitudinally. The mucous membrane is of the ciliated variety.

THE PLEURÆ.

The pleuræ are two flattened serous sacs interposed between the lungs and the walls of the chest. Each lung is entirely invested except at the hilum; the pleuræ are then reflected over the pericardium, inner surface of the chest, and thoracic surface of the diaphragm; a fold of pleura extending from the root of the lung to the diaphragm is called the broad ligament of the lung. The parietal layer extends upward about one and a half inches above the first rib; it is impressed by the subclavian artery, which rests upon it.

THE LUNGS.

The lungs are a double organ, right and left, separated by the structures in the middle mediastinum; they consist of five lobes,—these of myriads of lobules, and each lobule of clusters of air-cells.

Each lung is conoidal in form, and presents an apex, a base, an anterior and posterior border, an inner and outer surface. The apex projects above the level of the first rib; the base is broad, concave, and rests on the upper surface of the diaphragm; the anterior border is thin, sharp, and meets the anterior border of the other lung, except at the lower third, where that of the left lung recedes, exposing the pericardium to the extent of the area of a silver dollar; the posterior border is bluntly rounded and broad, and longer than the anterior; the anterior surface is convex and smooth, and is

applied to the wall of the chest; the inner surface is flattened, slightly concave, for the accommodation of the heart, and posteriorly presents the hilum, for the entrance of the bronchi, vessels, and nerves.

The right lung presents three lobes; the left lung two. The lobes are formed by deep fissures, commencing at the anterior border and extending deeply upward and inward. The left lung is the longer; the right the broader and heavier. The two lungs weigh forty-two

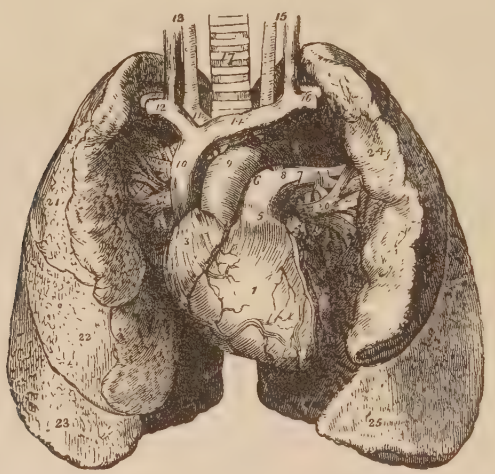

FIG. 150.—HEART AND LUNGS.

1, right ventricle; 3, right auricle; 5, pulmonary artery; 9, aorta; 10, supe ior cava; 20, root of lung; 21, 22, 23, upper, middle, and lower lobes of right lung; 24, 25, upper and lower lobes of left lung.

ounces, have an average specific gravity of about 0.5, and hence float in water; but, if consolidated by inflammatory effusions, or if collapsed, or prior to the respiratory act, they will sink in water. At birth, the lungs are of a rose-pink in color; but, as age advances, they become darker, often mottled and bluish. On the surface of the lungs are seen polygonal spaces, about the size of a split pea, which correspond to the lobules.

The structure of the lungs can best be understood by

a consideration of the air-sacs of a frog. These consist of membranous sacs, which are filled by the act of deglutition. They present upon their inner surfaces numerous reticulations, forming pits, which are the air-cells proper. The capillary vessels are freely distributed to the minute partitions between the pits, and the blood is exposed to the action of the air. In the human subject we have a similar arrangement, but very much dwarfed in size,—an arrangement of a microscopic sac, presenting numerous reticulations, forming pits or air-cells, the entire sac of cells being called a cluster. Ten to forty clusters make a lobule, which is surrounded by areolar tissue, containing much yellow elastic and some involuntary muscular fibres, which also form the nidus for the ramification of arterioles, venules, nerves, and the lymphatics. To further elucidate the structure of the lungs, it is necessary to follow the course of a bronchus, which, upon entering the hilum, divides and subdivides repeatedly, until it has attained the diameter of one-fiftieth of an inch, when it loses its encircling rings, which are replaced by delicate cartilaginous plates; these then become entirely membranous, and terminate in the air-sacs, these air-sacs being simple dilatations, very similar to the large air-sacs of the frog; they present along their walls a reticulated arrangement of the lining mucous membrane; these reticulations form numerous pit-like, polyhedral air-cells, separated by very delicate septa, in which the capillaries ramify; they all open into the common air-sac, and

FIG. 151.—TWO CLUSTERS OF AIR-CELLS.

the space between them is designated the intercellular passage. The air-cells are about one-two-hundredth inch in depth. The pulmonary capillaries form a close net-work, the meshes of which are less than the diameter of the vessels. Their walls are extremely delicate, consisting of a single layer of endothelial cells, supported on a skeletal basement membrane. In the septa, the capillaries are often disposed in a single layer, exposing them to the action of the air on both sides of the septum. The pulmonary artery does not nourish the lung, which depends for its nutrition on the blood which flows in the bronchial arteries.

THE ORGANS OF DIGESTION.

The alimentary canal and its appendages comprise the organs of digestion. It begins at the mouth and terminates at the anus, and consists of a tube about twenty-eight feet long, which undergoes many changes in name and position, arrangement and form.

The mouth is the commencement of the alimentary canal; it is an ovoidal cavity, containing the tongue, teeth, and openings of the ducts of the salivary glands. It is bounded above by the hard palate, laterally by the cheeks, anteriorly by the lips, below by the mylo-hyoid muscles; posteriorly it opens into the pharynx. The lining mucous membrane is of the squamous variety and rich in mucous glands. Opposite the second upper molar is a papilla, which presents the opening of the parotid duct; on the floor of the mouth, at each side of the frænum linguæ, is the opening of Wharton's duct, the duct of the submaxillary gland. The ducts of the sublingual gland, eight to fifteen in number, open on the floor of the mouth. The gums are fibrous structures, closely attached to the periosteum, and covered by the lining mucous membrane, which is intimately adherent.

THE TEETH.*

Human teeth are osseous in character and are ivory-like bodies, placed in the jaws for the purposes of mastication, articulation, and contour. Normally fifty-two teeth make their appearance during life; these are divided into two sets, for child and adult life. The first, known as the primary, temporary, deciduous, or milk set of teeth, consists of twenty—ten for either jaw. The second, or permanent, consists of thirty-two, of which the first tooth making its appearance is the first or six-

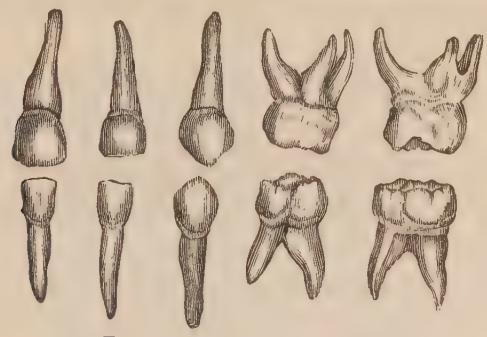

FIG. 152.—TEMPORARY TEETH.

year-old molar, so named because it erupts about the sixth year.

The temporary teeth are classified on each side, from the median line backward, into two incisors (one central and one lateral incisor), one cuspid or canine, and two molars, the first and second, in each jaw.

In the permanent set the incisors and cuspids correspond in number and position to those of the temporary, but the molars are replaced by the first and second bicuspids or premolars, and posterior to these we find the first, second, and third molars; the third molar is often termed the "dens sapientiæ," or "wisdom tooth."

*The section on the teeth has been prepared by T. S. Heineken, D.D.S., of New Jersey, and E. E. Caspersonn, D.D.S., of Australia.

A tooth is said to consist of a crown, neck, and root or roots. The crown is all that portion found normally above the gum; the neck the narrow, constricted portion between the crown and root at the edge of the gum. The root is that portion imbedded in the alveolus; its end is termed the apex.

Physical Characteristics of the Teeth.—In placing this description before the reader, and by means of which he will be enabled to distinguish any normal tooth, we wish him to bear in mind that abnormally he may find a variety of deviations. The second upper bicuspids

FIG. 153.—PERMANENT TEETH.

are sometimes found with two roots; either of the superior bicuspids with three; molars occasionally have four, even five roots. The writer has in his possession a second lower molar with five cusps and three roots; one with five cusps is very rarely met with.

The crown of each tooth has five surfaces, viz., the labial or buccal, that next the lip or cheeks; the lingual, next the tongue,—sometimes called the palatal in the upper teeth; the two approximal surfaces,—that nearest the median line being called the mesial, that farthest away the distal; and the cutting edge or masticating sur-

face, according to whether it is an incisor or one of the bicuspids or molars.

Permanent Teeth.—Upper incisors: the labial and

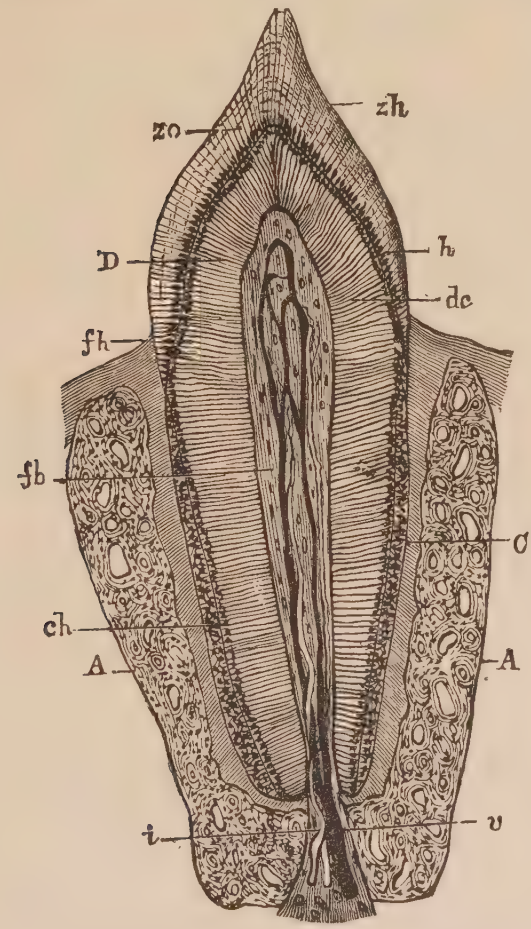

FIG. 154.—DIAGRAM OF PREMOLAR TOOTH, WITH ALVEOLUS.

A, bony wall of alveolus; zo, enamel prisms; zh, enamel casting; h, spaces in the base of the enamel prisms; D, dentine; dc, dentinal tubules; fh, gum, with alveolar periosteum below it; C, cement; ch, cement spaces; fb, tooth-pulp; i, nerve entering pulp; v, pulp blood-vessels.

lingual surfaces are shovel-shaped, the former convex, the latter concave; the approximal surfaces are triangular in shape, with the base at the neck, the distal

corner rounded, and by this peculiarity we can distinguish to which side the tooth belongs; the cutting edge is convex; when first erupted three cusps are noticeable on it, which correspond to the cornua of the pulp, and are gradually worn off by usage; on the lingual surface we find three ridges corresponding to these cusps; on the same surface, near the neck, is usually a small prominence called the cingulum, and beneath a depression termed the basilliar pit; the termination of the enamel on the gum line is concavo-convex, the former on the approximal surfaces, the latter on the labial and lingual; the roots are conical in shape.

The upper centrals are distinguished from the upper laterals in that the root of the former is irregularly rounded, while the latter is slightly flattened. It is also one-third larger than the lateral. The mesial surface of the lateral is often slightly concave and the distal more convex, that corner being also more rounded and the cingulum more marked and nearly always present; indeed, it is more frequently found in the upper laterals than any other teeth.

The lower incisors differ from the upper in being smaller, the cutting edges straight, and the angles at both mesial and distal corner equally well defined, in having no cingulum, and the roots are flat and longer in comparison to the crown than the upper.

The lower centrals and laterals are very much alike, except that the former is the smaller of the two.

The cuspids are thicker, stronger, and in every way larger than the incisors. The upper has three ridges, prominently marked, especially the central one, which divides the labial surface. The mesial surface is larger than the distal; the lingual surface is concave, excepting for a prominent ridge, which makes it appear almost

convex. The enamel on the approximal surfaces terminates in an obtuse angle, with vertex toward the cusps and most readily distinguished on the distal surface. The root is prominent and long, and, on cross-section, like a rounded triangle.

We are enabled to tell on which side the tooth belongs by the slope from cusp to mesial surface being shorter than that from cusp to distal surface.

The lower cuspids resemble the upper, but are distinguished by being smaller. The lingual and labial surfaces are more distinctly convex, and the root is flattened. The enamel at the approximal surfaces is curved at the neck; occasionally that of the mesial side is angular, like the upper.

The bicuspids or premolars have crowns, on section, almost like a rounded square.

The first upper bicuspid has a buccal and lingual cusp, separated by a fissure, which bifurcates at each termination and runs over on the mesial surface. The former is the larger cusp, and the slope from cusp to the distal surface is longer than that to the mesial. The root bifurcates. The second bicuspid is distinguished by being larger than the first; the fissure does not run over on the mesial surface, and its root is not bifurcated, but oval, and compressed by a groove which runs down the centre on each side.

The inferior first bicuspid is the smallest of the bicuspids, and is the only one which is not marked by a fissure; the buccal cusp turns in very much, and the lingual is small and often rudimentary. Its cusps are connected by a ridge, on either side of which is a pit.

The inferior second bicuspid has a semilunar fissure running mesio-distally with its convexity toward the lingual surface, and a second fissure sometimes running

over on the lingual surface, generally dividing the lingual cusp into two.

The roots of both lower bicuspids are oval in shape. The first superior molar has a large crown, and is in outline like a rounded rhomboidal; the buccal and lingual surfaces are convex and the approximal flattened. It has four cusps, on the masticating surface of which the mesio-lingual is the largest, the mesio-buccal next in size,

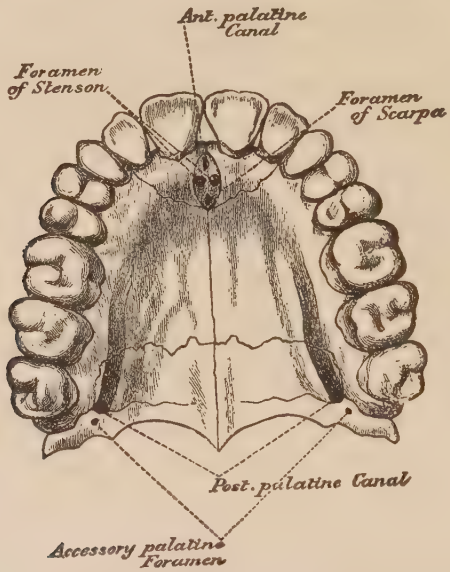

FIG. 155.—THE UPPER PERMANENT TEETH IN POSITION.

then the disto-buccal, and, smallest of all, the disto-lingual. The mesio-lingual cusp is connected with the disto-buccal by a ridge, and around each other cusp is a fissure,—one running mesio-bucally and the other disto-lingually. This fissure often runs over on the lingual surface. It has three roots,—one lingual and two buccal, the lingual being largest and round; the buccal roots are flat, and the anterior larger than the posterior.

The second superior molar resembles the first, but

has generally the following distinctions: the disto-lingual cusp is more rudimentary; the disto-lingual fissure does not run over on the lingual side, and the roots have a tendency to stand closer together.

The third superior molar is the smallest; it has three cusps separated by fissures, which terminate in the centre in a depression. The roots have a still greater tendency to come together, and are often confluent.

The inferior first molar has five cusps,—three buccal and two lingual,—separated by fissures, one running mesio-distally and one from this fissure lingually separating the last-mentioned cusps, and two running from the mesio-distal fissure, separating the three buccal cusps. It has two roots,—an anterior and posterior,—of which the first is the larger and flatter.

The inferior second molars differ from the first in having only four cusps and a crucial fissure, which generally extends over on the buccal surface and terminates near the gum in a depression. The roots have a tendency to curve backward.

The third inferior molar is very much like the first, except that the roots have even a greater tendency than those of the second to curve backward, and are more confluent.

Temporary Teeth.—The temporary teeth are smaller, but closely resemble, in form, those of the permanent set. The enamel terminates abruptly, and is the distinguishing feature when in doubt. The crown of the upper first molar has usually three cusps; the upper second, four; the inferior first molar, four; and the second, five.

Structure of Teeth.—On dissection we find a tooth to consist of pulp, dentine, enamel, cementum, and the pericementum or peridentium.

The pulp is that portion contained within the pulp cavity and canal or canals. That part within the former is termed the bulb, and corresponds in general outline to the shape of the tooth, having a cornu or horn for each cusp. That within the canal is termed the radicle, one being found in each root. The pulp is composed of a number of fine blood-vessels, ramifying in a mass of delicate connective tissue, and a number of cells. Many of these on the outside of the pulp (odontoblasts) have processes, —long, delicate prolongations, —continued into the dental tubuli. It is the means of nutrient supply and sensation; it is also essential to the preservation of translucency and for the vital resistance of the tooth. On its death, the organ gradually loses its translucency, being devitalized, and becomes discolored and opaque. Such a tooth is, however, not dead, as the cementum, and even perhaps part of the dentine, continues to receive nourishment through the peridentium for years.

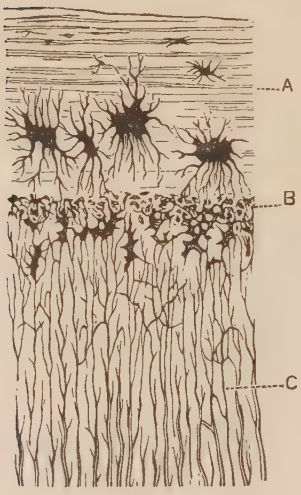

FIG. 156.—SECTION THROUGH A CANINE TOOTH.

A, crusta petrosa, with large bone-corpuscles; B, interglobular substance: C, dentinal tubules.

The dentine is that hard substance which forms the principal bulk of the tooth, extending from the pulp cavity and canal on the inside to the enamel and cementum on the outside. It is composed of dental tubuli and their contents, imbedded in intertubular tissue, a dense, homogeneous substance. The former are minute tubes, having an external diameter averaging about $\frac{1}{3300}$ inch, and internally $\frac{1}{10000}$ inch. They extend

in a double curved or wavy direction from both the enamel and dentine to the pulp. In their course they divide and subdivide dichotomously, giving to the surface of the dentine, when cut, a striated appearance. They are filled with a delicate rod of protoplasm, which is continuous with the processes of the odontoblasts on the surface of the pulp. No nerve-filaments have been found in dentine, but this protoplasm is probably the medium through which painful sensations are transmitted to the nerves of the pulp. The chemical composition of dentine is about twenty-eight per cent. organic matter and seventy-two inorganic or earthy matter, consisting of phosphate and carbonate of lime, and traces of fluoride of lime, phosphate of magnesium, and other salts. Secondary dentine is a formation of dentine within the walls of the pulp-cavity, due to an external or internal irritant which has stimulated certain odontoblasts.

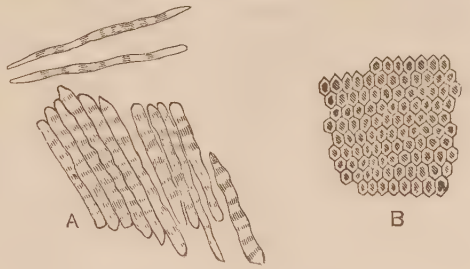

FIG. 157.—ENAMEL PRISMS.
A, in longitudinal view; B, in cross-section.

The enamel is the external covering of the crown, and is the hardest and most brittle structure of the body. It is composed almost entirely of inorganic matter, containing only from about three to five per cent. of inorganic material. In arrangement, it is made up of hexagonal prisms, radiating from the centres of development, one for each cusp, and thus in the fissures we often have the enamel imperfectly protecting the dentine by the formation of V-shaped spaces, which allow ingress to various external causes of decay. It is thickest on

the articulating surfaces, and most of all over the cusps; thinnest toward the neck, where it is overlapped by the cementum.

The cementum, or crusta petrosa, is the thin layer of material covering the roots and extending from the apex to neck. In structure and resemblance, it is the most analogous of all tooth-substance to bone, containing sparingly lacunæ and canaliculi, and about 30 per cent. of organic matter. In single-rooted teeth the cementum is thickest at the apex, in multi-rooted teeth at the bifurcation.

The pericementum is that membrane which envelops the root of the tooth and fills the space intervening between it and the wall of the alveoli. It is analogous to the periosteum of the bone, and performs the double function of nourishing the cementum on the one side and bone on the other.

Tooth-development begins about the sixth week of fœtal life. Along the whole length of the fœtal gum is a projecting ridge, termed the "dental ridge," due to the excessive activity of the Malpighian layer of epithelial cells, which, for want of space, necessarily crowd up the corneous layer. This same activity produces, in like manner, the dental groove in the gum, also filled with epithelial cells, and running along under the ridge. This groove gradually becomes deeper, extending into the deeper layer, and a hollow sack is formed, which gradually closes at the top and the groove becomes obliterated by the closure of the Malpighian layer. This sack has the appearance of a pear hanging by a stem, with the blossom end downward, and is pressed in to accommodate the advancing papillæ, which are the makers of the future pulp and dentine. The stem becomes the gubernaculum, or the future enamel organ of the accompanying permanent tooth, by a similar dipping down on

the lingual side. The papilla grows still deeper into the pear-shaped body, or stellate reticulum, as it is now termed, because of the stellate-shaped cells it contains, and thus forms a double cap over the papilla, the lower tunic of which is the enamel organ, consisting of cylindrical epithelial cells, which probably absorb the stellate cells, becoming calcified, forming the enamel prisms, and so the process goes on from within outward, until the enamel is completely calcified.

While the enamel is thus being calcified the same process is taking place with the dental papillæ, but in the opposite direction. The continuous layers of odontoblasts which now occur here calcify from without in the papilla, receding till it forms the future pulp inclosed within its now formed pulp cavity and canal, with its minute apical foramen for the transmission of the nerves and vessels so essential to the future welfare of the tooth. It is important to remember that the complete formation of the apical foramen does not take place for some years after the eruption of the tooth.

The cementum is formed from the soft connective tissue of the dental sac. When the tooth is erupted the enamel is also covered by a thin layer of cement, which wears off. It is about the $\frac{1}{20000}$ inch in thickness and is named Nasmyth's membrane.

Table of Eruption of Temporary Teeth.

Central incisors, lower, . .	5 to 7 months.
Central incisors, upper, . .	7 to 8 "
Lateral incisors, lower, . .	8 to 9 "
Lateral incisors, upper, . .	9 to 10 "
First molars, lower, . . .	11 to 12 "
First molars, upper, . . .	13 to 14 "
Cuspids or canines, lower, . .	17 to 18 "
Cuspids or canines, upper, . .	19 to 20 "
Second molars, ...	23 to 30 "

Table of Eruption of the Permanent Teeth.

First molars,	5 to 7 years.
Central incisors,	6 to 8 "
Lateral incisors,	7 to 9 "
First bicuspid,	9 to 10 "
Second bicuspid,	10 to 11 "
Lower cuspids,	10 to 12 "
Second molars,	12 to 14 "
Upper canines,	13 to 15 "
Wisdom,	17 to 45 "

The teeth of the lower jaw, as a rule, precede the upper by a few months.

Method of Eruption.—When the enamel is completely formed and the calcification of the other tissues of the tooth is sufficiently advanced to enable it to bear the pressure to which it is to be afterward subjected, its eruption takes place, the tooth making its way through the gum, which is absorbed by the pressure of the crown against it. The tooth itself is advanced by the increasing size of the root. At the same time the septa between the dental sacs, at first fibrous in structure, ossify and constitute the alveoli. While the teeth are in place they are firmly attached to the peridental membrane, and on removal of the tooth the alveoli finally become absorbed.

THE SALIVARY GLANDS.

The salivary glands consist of three pairs—the parotid, submaxillary, and sublingual—and numerous simple follicles imbedded in the mucous membrane of the mouth. The *parotid gland* is situated in front and below the ear, wedged in between the mastoid portion of the temporal bone and the posterior border of the ramus of the lower jaw; it is irregularly lobulated, grayish in color, and formed of lobes which are made up of lobules, and these are composed of frequent branching tubules which dilate

and form the salivary alveoli. These are lined by salivary cells, uninucleated granular cells, which almost entirely fill the alveoli. Interposed between the cells and basement membrane are collections of minute, dark, granular cells, forming zones and crescents. The external carotid artery is deeply imbedded in the substance of the parotid gland, and the posterior auricular and transverse facial are given off in its substance. The facial nerve enters its inner posterior part and emerges near its anterior border. The duct of the parotid, or Steno's duct, is about two and a half inches long; it runs transversely across

FIG. 158.—SECTION OF A SALIVARY GLAND.

the masseter on a level with the necks of the upper teeth, then pierces the buccinator and opens on a papilla just above the upper second molar. It is about one-eighth of an inch in diameter, and feels like a whip-cord. It presents three coats,—outer or fibrous, muscular, and mucous.

The *submaxillary* gland is situated beneath the mylohyoid muscle, in the submaxillary triangle, under cover of the inferior maxillary bone. It weighs about two drachms, is about one and a half inches long, and has a single duct, the duct of Wharton, which opens at

the sides of the frænum of the tongue. Its structure is like that of the parotid.

The *sublingual* gland is situated above the mylohyoid muscle; it weighs about one drachm, and opens by numerous ducts on the floor of the mouth; one of these—the duct of Bartholine—opens into Wharton's duct. In structure it resembles the parotid and submaxillary. The secretion of the salivary glands is watery, having a specific gravity of 1005; it contains many other ingredients,—an organic ferment ptyaline, which acts on starches and transforms them into dextrine.

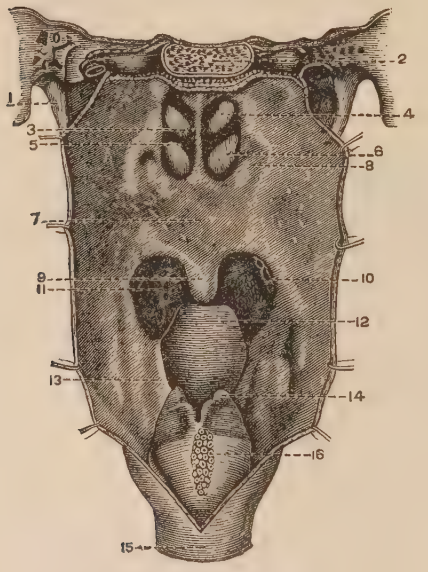

FIG. 159.—PHARYNX LAID OPEN FROM BEHIND.

1, styloid process; 2, body of occipital; 3, septum nasi; 4, middle turbinated bone; 5, posterior naris; 6, inferior turbinated bone; 7, soft palate; 9, uvula; 10, tonsil; 11, back of tongue; 12, epiglottis; 13, arytæno-epiglottidean fold; 14, tip of arytænoid cartilage; 15, œsophagus; 16, back of cricoid cartilage.

THE PHARYNX.

The pharynx is the large musculo-membranous sac which is attached above to the basilar process of the occipital bone, and into which open the posterior nares, the Eustachian tube, the mouth, larynx, and œsophagus. It is about five inches long, and terminates on a level with the fifth cervical vertebra in the œsophagus, with which it is continuous; it is composed of three coats,—muscular, fibrous, and mucous. The muscular coat is formed by the constrictors; the fibrous coat, between the muscular and mucous, is attached to

the basilar process of the occipital bone and the under surface of the petrous portion of the temporal, and becomes thinner as it passes down, and is gradually lost on the sides of pharynx; the mucous coat above is covered by columnar epithelium; below, by squamous cells; in it are imbedded numerous mucous glands. The pharynx is separated

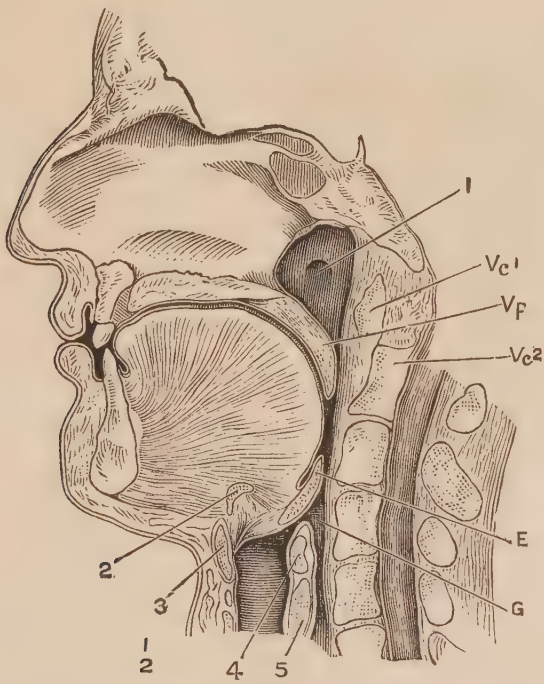

FIG. 160.—MEDIAN SECTION OF THE HEAD.

Vp, position of the soft palate during rest; 1, orifice of Eustachian tube; Vc1 and Vc2, first and second cervical vertebræ; E, epiglottis; G, glottis; 4, arytenoid cartilage; 5, cricoid cartilage; 3, thyroid cartilage; 2, hyoid bone,

from the vertebral column by a quantity of loose connective tissue. In front it is irregularly attached to the internal pterygoid plate, pterygo-maxillary ligament, side of the tongue, hyoid bone, thyroid and cricoid cartilages. In contact with its outer surfaces are the internal carotid artery, the internal jugular vein, and ninth, tenth, eleventh, and twelfth pairs of nerves, and the cervical

sympathetic. Two glandular organs—the tonsils—are placed on either side, between the pillars of the fauces. Their bases are applied opposite to the course of the great vessels,—an important fact to remember in operations on these structures.

THE ŒSOPHAGUS.

The musculo-membranous tube, which leads from the pharynx into the stomach, is about nine inches long, and extends from the fifth cervical to about the ninth dorsal vertebra. It passes down in front of the bodies of the vertebræ, through the posterior mediastinum and through the œsophageal opening of the diaphragm, and enters the cardiac end of the stomach. It has three coats,—muscular, fibrous, and mucous. The muscular or outer is formed by longitudinal and circular fibres; the fibrous coat consists of loose cellular connective tissue; the mucous coat is thrown into longitudinal rugæ, and is covered with squamous epithelium. The œsophagus is in relation in the neck with the trachea anteriorly, and laterally with the great vessels. In the thorax it descends in the posterior mediastinum, having in front the structures of the root of the lungs, and, lower down, the pericardium. It is covered laterally by the pleuræ. The pneumogastrics descend upon it,—the right behind, the left in front. The continuation of the alimentary tract is situated in the abdominal cavity.

ABDOMINAL VISCERA.

THE ABDOMEN.

THE abdomen is the largest cavity in the body. It is limited above by the diaphragm, below by the upper plane of the true pelvis. It is ovoidal in shape, and is bounded behind by the spine, psoas and quadratus muscles; anteriorly and at the sides, by the ribs, abdominal muscles, and the iliac bones. It is lined by a serous membrane,—the peritoneum,—which is also re-

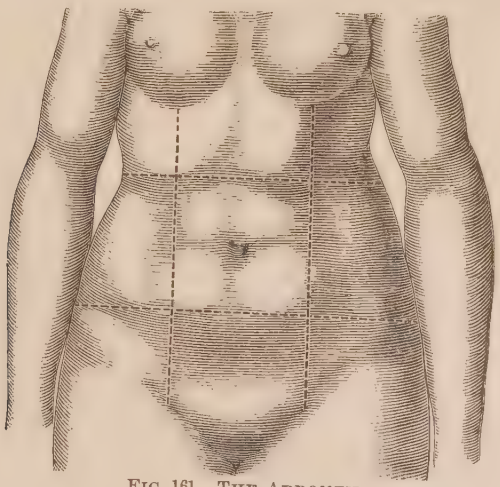

FIG. 161.—THE ABDOMEN.
(The dotted lines represent the planes that divide the abdomen into nine regions.)

flected around the abdominal viscera, and serves to keep them in place. There are six openings into the abdominal cavity, namely, the aortic; œsophageal; the opening for the vena cava; in the fœtus, the umbilicus; and below, the openings of the inguinal canals. Normally, these are sufficiently strong to resist the hernia of the abdominal viscera. The abdominal cavity is divided into nine regions

or chambers by two transverse and two vertical planes. The upper transverse plane cuts the abdominal cavity at a level with the costal cartilage of the ninth rib; the lower plane on a level with the summits of the crests of the iliac bones. These divide the abdominal cavity into three portions,—a superior, middle, and inferior. These are again divided by two vertical planes, each drawn through the costal cartilage of the eighth rib and through the middle of Poupart's ligament, subdividing the abdominal cavity into nine regions, or chambers. The middle regions are: the epigastric above, umbilical in the middle, and the hypogastric below. Those at the sides are: the hypochondriac above, the lumbar at the sides of the umbilical, and the inguinal below. The following structures are located in these regions:—

Right Hypochondriac. The right lobe of the liver, gall-bladder, the duodenum, pancreas, hepatic flexure of the colon, upper part of the right kidney, and the right supra-renal capsule.	*Epigastric.* The middle and pyloric end of the stomach, left lobe of the liver and lobulus Spigelii, the pancreas, aorta, ascending vena cava and cœliac plexus.	*Left Hypochondriac.* The splenic end of the stomach, the spleen and extremity of the pancreas, the splenic flexure of the colon, upper half of the left kidney, and the left supra-renal capsule.
Right Lumbar. Ascending colon, lower part of the right kidney, and some convolutions of the small intestines.	*Umbilical.* The transverse colon, part of the great omentum and mesentery, transverse part of the duodenum, and some convolutions of the jejunum and ileum, and great vessels.	*Left Lumbar.* Descending colon, part of the omentum, lower part of the left kidney, and some convolutions of the small intestine
Right Inguinal. The cæcum, appendix cæci, ureter, and iliac vessels.	*Hypogastric* Convolutions of the small intestine, the bladder in children, and in adults if distended, the uterus during pregnancy, great vessels, and lumbar plexus.	*Left Inguinal.* Sigmoid flexure of the colon, ureter, and iliac vessels.

THE PERITONEUM.

The peritoneum is a serous sac which lines the walls of the abdomen and is reflected upon the viscera, which it more or less completely invests. In order best to understand its arrangement with reference to the viscera, this diagram, representing a vertical antero-posterior section through the median line of the body, should be closely studied.

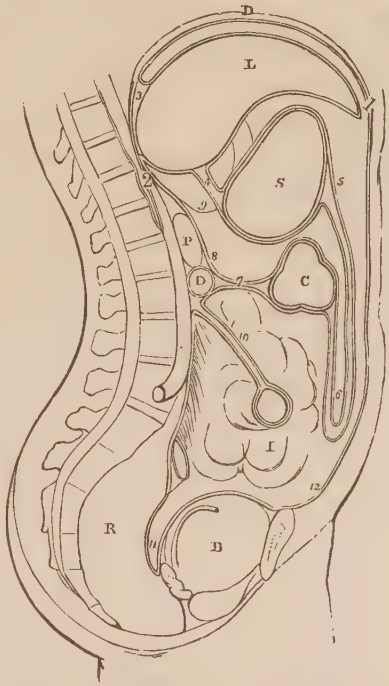

FIG. 162.—A VERTICAL SECTION SHOWING THE ARRANGEMENT OF THE LAYERS OF THE PERITONEUM.

D, diaphragm; L, liver; S, stomach; P, pancreas; D, duodenum; C, colon; I, small intestine; D, bladder; R, rectum; 3, posterior surface of liver; 4, foramen of Winslow; 5, great omentum; 6, lesser omentum; 7, mesocolon; 8, 9, lesser cavity of peritoneum; 10, mesentery; 11, recto-vesical fold.

Now begin at the under surface of the diaphragm anteriorly, and marked 1 in the diagram, and draw a line to represent the peritoneum nearly up to the posterior abdominal wall; then draw another line, beginning posteriorly at 2, forward so as to meet the line first drawn. These lines represent the anterior and posterior leaflets of the peritoneum, which meet above the liver and descend upon its superior surface, forming the suspensory ligament of the liver. Upon reaching the upper surface of the liver they again diverge, the anterior leaflet passing in front of the liver, the posterior behind it; but again meet at the transverse fissure of the liver, having invested that organ. Thence they pass by this to the superior curvature of the stomach, forming

the gastro-hepatic omentum, which includes the hepatic vessels and nerves. On reaching the superior curvature of the stomach again they separate, the anterior leaflet passing in front, the posterior behind the stomach, which they invest, the two leaflets again meeting at the greater curvature. They then pass down together for from six to twelve inches, hanging like an apron in front of the intestines; together they make an abrupt bend upward, the anterior layer becoming posterior, the posterior leaflet anterior, and they reach the anterior portion of the transverse colon, where they again separate, the posterior leaflet passing over the transverse colon and the anterior leaflet beneath it. They invest the colon and again meet along its posterior surface, and together proceed to the posterior wall of the abdomen, forming the meso-colon. Now the two layers separate; the posterior leaflet, which became by the ascent of the apron (or great omentum) the superior layer, runs up along the posterior abdominal wall, over the anterior surface of the duodenum and pancreas, and joins the leaflet whence it started, at the under surface of the diaphragm, and marked in the diagram 2. The anterior leaflet (now the lower leaflet of the meso-colon) passes down to the superior mesenteric vessels, and upon these to the small intestine, which it surrounds or invests and then passes back to the spine, forming the mesentery. It runs along the spine for a short distance and is reflected over the rectum and for some distance along its anterior wall; thence to the posterior surface of the upper part of the vagina and the posterior surface of the uterus, forming a pouch called Douglas's *cul-de-sac;* thence over the fundus uteri, along its anterior surface to the bladder, investing its upper portion only, and is then reflected along the anterior wall of the abdomen to the point of starting, and marked 1 in

the diagram. It will thus be seen that the peritoneum forms two sacs,—a smaller, formed by the posterior, and a larger, formed by the anterior layer. These two sacs communicate behind the gastro-hepatic omentum and may be likened to an hour-glass with a smaller globe at right angles to a larger. The constricted opening between them is behind the gastro-hepatic omentum, and is called the foramen of Winslow. The peritoneum is reflected from the cardiac end of the stomach to the hilum of the spleen, forming the gastro-splenic omentum, which contains the splenic vessels and nerves. In the male the peritoneum is a shut sac; in the female the Fallopian tubes open into the peritoneal cavity. The viscera entirely invested by peritoneum are the liver, stomach, spleen, transverse colon, upper part of duodenum, the small intestine, sigmoid flexure of colon, first part of rectum, ovaries, and uterus. The viscera partially invested by peritoneum are the kidneys, supra-renal capsules, pancreas, lower part of duodenum, ascending and descending colon, cæcum, second portion of rectum, vagina, and bladder. The peritoneum, by its reflections to the viscera, forms their ligaments, and three omenta,—the gastro-hepatic or lesser, the greater, and the gastro-splenic.

THE STOMACH.

The stomach is a remarkable dilatation of the alimentary canal, and is the principal organ of digestion. When distended it is conoidal in form, bent so as to present a short superior concave curve and a long inferior convex curvature. It measures about twelve inches long, four and a half inches in its vertical diameter, and three and a half inches antero-posteriorly. It weighs about five ounces; it lies transversely across the upper part of the abdominal cavity, beneath the diaphragm, extending

from the left hypochondrium across the epigastric into the right hypochondriac region. Its left extremity is broad, blunt, and large, and is called the cardiac end; it is attached to the spleen by the gastro-splenic omentum. The right extremity, or pylorus, is constricted; it lies near the end of the eighth costal cartilage. The pyloric orifice, or outlet of the stomach, communicates with the duodenum, and consists of an oblique orifice through a ring of muscular fibres. The œsophageal orifice is funnel-shaped and is situated to the right of the cardiac end, upon the upper portion of the organ. The lesser or superior curvature runs between the pylorus and œsophagus; it affords attachment to the lesser omentum. The greater or inferior extends between the œsophagus and pylorus and affords attachment to the greater omentum. The anterior surface of the stomach is convex and is in contact with the abdominal wall; posterior surface, also convex, lies upon the great vessels, the solar plexus, and pancreas. The stomach presents four coats,—serous, muscular, cellular, and mucous. The serous coat is derived from the peritonium. The muscular coat consists of planes of involuntary fibres arranged circularly, longitudinally, and

FIG. 163.—GLANDS OF THE FUNDUS OF THE STOMACH.

oblique. The circular layer is the principal plane of fibres; the longitudinal are most abundant near the curvatures; the oblique fibres are scattered, although disposed in a layer over the cardiac end.

The cellular coat is formed of loose cellular tissue, which connects the muscular and mucous coats. The mucous lining of the stomach is thick, smooth, pale pink in color, and, when the stomach is collapsed, thrown into numerous longitudinal wrinkles,—the rugæ. The mucous membrane presents under the microscope a honeycomb arrangement of shallow, pit-like depressions, about $\frac{1}{200}$ inch in diameter. At the bottom of these alveoli the peptic and mucous follicles open. They are both simple follicles, lined by columnar epithelium; in the peptic glands numerous spheroidal cells are imbedded among the columnar epithelium; these are active agents in the elaboration of the gastric juice. The mucous crypts are very abundant about the pylorus. The free surface of the stomach is lined by columnar epithelium.

THE SMALL INTESTINE.

The small intestine is a musculo-membranous tube, about twenty feet long. It is divided into three parts,—the duodenum, jejunum, and ileum. The duodenum is about ten inches long; its diameter is greater than any other part of the small intestine; it is comparatively fixed in position by the peritoneum; it curves around the head of the pancreas, and at first ascends, then descends, and then runs transversely across the front of the spine. The ascending portion is about two inches long, invested by the layers of the lesser omentum; it is commonly found stained with bile; the descending portion, about three inches long, passes down in front of the right kidney; it receives the common bile and pancreatic

duct near the middle, along its inner side; the transverse portion is about five inches long, and becomes narrower, and terminates in the jejunum to the left of the second lumbar vertebra. The jejunum is about eight feet long; it begins at the duodenum and terminates in the ileum; it is more capacious and more vascular than the ileum. The ileum is a highly convoluted portion of the small intestine; it is ten to twelve feet long, and terminates in the right inguinal region in the cæcum. The ileum is the narrowest part of the small intestine; its walls are thin and less vascular than those of the jejunum.

The small intestine has four coats,—serous, muscular, cellular, and mucous; the ileum, jejunum, and first part of duodenum have a peritoneal investment. The muscular coat consists of circular and longitudinal fibres; the cellular coat consists of loose connective tissue. The mucous membrane lining the small intestine is thick, covered by columnar epithelium, and presents for examination: the valvulæ conniventes; villi; mucous crypts, or follicles of Lieberkühn; Brunner's glands, in the duodenum; solitary glands; and agminate glands, forming Peyer's patches. The valvulæ conniventes are transverse folds of mucous membrane, extending one-third around the intestine, and about one-third inch in depth; they are found in the second and third parts of the duodenum, throughout the jejunum, and gradually disappear in the upper part of the ileum. The valvulæ conniventes are arranged spirally around the interior of the intestines. The villi contain the intestinal termini of the lacteals; they are about four millions in number, and are scattered throughout the whole length of the small intestine; they are minute, conical elevations, covered by columnar epithelium, and contain lacteals, blood-vessels, nerves,

connective and lymphoid tissue. The follicles of Lieberkühn are simple mucous crypts, and are found throughout the mucous membrane of the small intestine; they are similar in structure to the mucous follicles of the stomach. Brunner's glands are racemose glands imbedded in the mucous membrane of the duodenum. The solitary glands are found most abundantly in the lower

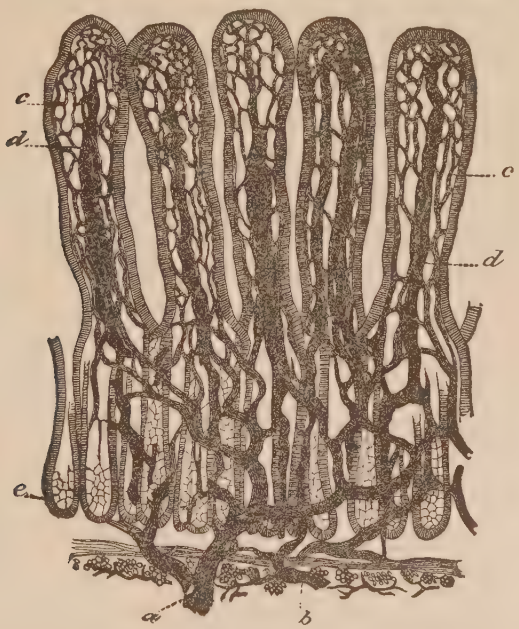

FIG. 164.—SECTION OF INTESTINE, SHOWING THE VILLI.
The blood-vessels, c, and the lacteals, d, have been injected. The blind ending, or simple loop of the black lacteal, is seen to be surrounded by the capillary net-work of the blood-vessels.

part of the ileum; they consist of a delicate, skeletal, interlacing fibrous structure, supporting lymphoid elements. They are grayish bodies, ovoidal in form, and measure from two to three millimetres in diameter; they are surrounded by villi and mucous follicles. Peyer's patches are formed by aggregations of the solitary gland, forming oval patches twenty to thirty in number, found principally in the lower part of the ileum; they are

placed opposite to the attachment of the mesentery. The patches are about three-fourths inch wide, one and one-half inches long, but vary both in size and shape; they are surrounded by villi and mucous crypts.

THE LARGE INTESTINE.

The large intestine begins in the right inguinal region and terminates at the anus. It is about five feet long. Throughout the whole of its extent it is sacculated and covered by columnar epithelium. It is divided into the ascending, transverse, and descending colon and the rectum. The ascending colon begins as a blind pouch, the cæcum, which is the largest part of the colon. It is situated in the right inguinal region and is held in position by the peritoneum, which, as a rule, covers the anterior surface and sides of the cæcum. Attached to its lower posterior part is the appendix vermiformis,—a rudimentary cæcum. It is about four inches long, about as thick as a pencil, and often entirely invested by peritoneum. The ileum enters the cæcum at its inner side, the opening being designated the ileo-cæcal valve. These valves are placed horizontally, and they are formed by the reduplication of the mucous membrane of the cæcum and muscular fibres. When these are cut the valve disappears, and the opening gapes widely and is funnel-shaped. The iliac surface of the valve is covered with villi. The upper portion of the ascending colon passes upward to the under surface of the liver. Its sides and anterior surface are covered by peritoneum. Beneath the liver it bends at right angles and becomes the transverse colon, and is entirely surrounded by peritoneum, which holds it to the posterior wall of the abdomen by the meso-colon. In the left hypochondriac region beneath the spleen it bends abruptly downward, becoming the

descending colon, which is covered anteriorly and at the sides by peritoneum, and terminates in the convolutions of the colon called the sigmoid flexure, which is held in position by the sigmoid meso-colon. It terminates in the rectum, which is a cylinder about eight inches long. It begins at the left side of the lumbo-sacral articulation, curves slightly to the right, then follows the curve of the sacrum, and finally bends abruptly backward to terminate at the anus. It is divided into an upper, middle, and inferior portion. The upper part is about three and one-half inches long, passes downward to the upper border of the third piece of the sacrum. It is invested by peritoneum and held in place by the meso-rectum. The middle part, about three inches long, terminates on a level with the tip of the coccyx. The lower portion extends from the tip of the coccyx to the anus, and is about one and a half inches long. It is encircled by the internal sphincter and forms the posterior limit to the perineum. The large intestine has four coats,—serous, muscular, cellular, and mucous. The serous coat is formed by the peritoneum. It covers the anterior surface and sides of the cæcum, ascending colon, and descending colon. It entirely invests the transverse colon, the sigmoid flexure, and the first or upper part of the rectum. The muscular coat consists of longitudinal and circular fibres. The longitudinal fibres are collected into three bands about half an inch in width. They are only about three-fifths as long as the large intestine, and by their attachment to the sides of the gut cause the sacculation or pouching. The fibres of the bands become diffused on the surface of the sigmoid flexure. They are placed nearly equidistant, and generally are arranged, one anteriorly, one along the inner side, and one along the outer side of the colon. The circular fibres form a

continuous layer, thicker at the ridges between the pouches and in the lower part of the rectum; re-inforced by some voluntary fibres, they form a band one and one-half inches broad, one-third of an inch thick, which forms the internal, the main sphincter of the rectum. The cellular coat consists of loose connective tissue.

The mucous coat is of a grayish color, and thrown into a great number of transverse semilunar wrinkles; it has no villi. It is lined by columnar epithelium. In the rectum it is thick and vascular, and loosely connected with the muscular coat. When empty it is thrown into numerous longitudinal wrinkles, which disappear as distension occurs. Three, sometimes four, folds of mucous membrane at right angles to the axis of the rectum form a series of shelves for the support of the weight of the fæcal matter.

The anus is the external opening of the rectum. It forms an antero-posterior slit-like opening between the buttocks, posterior to a line across the tuberosities of the ischia. The skin surrounding this orifice is pigmented, and presents numerous short, stiff hairs. Beneath the skin are a series of delicate bundles of muscular fibres, called the corrugator cutis ani, which throw the skin into a number of wrinkles, and which radiate from the anal aperture. The external sphincter consists of an elliptical plane of voluntary fibres, which surround the anus. It is about a millimetre in thickness, and lies beneath the skin. A critical examination of the anus shows that, when contracted, it is puckered into from seven to twelve slightly nodular elevations,—the extremities of the anal columns. In the intervals between the nodules are minute pouches, which are not infrequently subject to excoriations and ulceration. The large intestine is studded with mucous follicles. It also

presents a number of solitary glands, especially in the cæcum and ascending colon.

THE LIVER.

The liver is the largest gland in the body; it is situated in the right hypochondriac, but extends across the epigastric into the left hypochondriac region; it is of a dark reddish-brown color, weighs about three and one-half pounds, is dense, but friable, and measures about twelve inches long, three inches at its thickest part, and six inches in its greatest breadth; it is a semi-ovoidal organ, smooth and convex above, flattened and somewhat irregular below, the large part of the oval being to the right. Superiorly it is divided by the suspensory ligament into a large right and a small left lobe; inferiorly it presents five lobes and five fissures, practically between the right and left lobes. The anterior border is thin; it presents a deep notch between the right and left lobes; the posterior border is thick and rounded, and is held to the diaphragm by the layers of the coronary ligament.

The upper surface of the liver is on a level with the fifth rib; the anterior border corresponds with the inferior border of the chest. The liver changes its position slightly during respiration, descending in inspiration and rising a trifle higher in expiration. It has five lobes, five ligaments, five fissures, and five sets of vessels.

The lobes are the right and left, and between them, on the inferior surface, are the quadrate, Spigelian, and caudate lobes. The right lobe forms seven-eighths of the mass of the liver; it is quadrangular in form, convex on the superior surface, flattened below, and presents a shallow, anterior depression for the colon; posteriorly it is impressed by the right kidney. The left lobe

is triangular, and separated from the right lobe, above, by the suspensory ligament; below, by the longitudinal fissure. The lobus Spigelii is connected with the right lobe by the caudate lobe. The quadrate lobe is situated anteriorly between the fissure for the gall-bladder and the longitudinal fissure.

The five fissures are placed between the right and left lobes on the inferior surface of the liver; they are arranged in the form of a letter **A**, the expanded limbs being anteriorly; they are named the longitudinal, fissure for the ductus venous, fissure for the gall-bladder, fissure for the vena cava, and the transverse fissure. The longitudinal fissure begins at the notch at the anterior border, and lodges the round ligament (in the fœtus, the umbilical vein); the continuation backward of the longitudinal fissure lodges a fibrous cord, which is the obliterated remains of the ductus venous; the fissure for the gall-bladder, placed between the quadrate and right lobes, lodges the gall-bladder. Posteriorly the liver is deeply grooved by the ascending vena cava. The transverse fissure transmits the hepatic artery, ducts, lymphatics, nerves, and portal vein; it forms the cross-bar of the letter **A**.

The ligaments are the suspensory from the diaphragm, the right and left lateral, and the coronary, all formed by the layers of the peritoneum. The ligamentum teres is the obliterated umbilical vein. The vessels of the liver are the hepatic artery, hepatic veins, hepatic duct, portal vein, and lymphatics. The hepatic artery, a branch of the cœliac axis, enters the transverse fissure and is distributed to the portal canals. The hepatic duct arises in the lobules of the liver by capillaries which ultimately form the right and left duct; these join near the transverse fissure, form one duct, which empties with the pancreatic into the descending portion of the duodenum.

The hepatic veins empty into the vena cava. The lymphatics are numerous and are distributed through the portal canals. The portal vein enters the liver at the transverse fissure and divides into a right and left branch; these give off vaginal branches that run in the portal canals; from these are given off the interlobular; and these send off numerous vessels into the lobule, called the lobular. The lobular are the smallest radicles of the portal system; they all converge toward the centre of the lobule and run into the middle lobular or intralobular veins, which empty into the sublobular, and these form the hepatic, three or five in number, which open into the ascending vena cava as it lies in the fissure in the posterior border of the liver. The nerves of the liver are the pneumogastric and sympathetic.

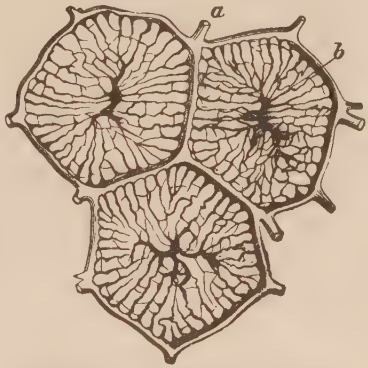

FIG. 165.—TRANSVERSE SECTION OF LOBULES OF LIVER.
a, interlobular vein; b, intralobular or central vein.

In structure the liver is composed of great numbers of lobules held together by delicate connective tissue, arteries, ducts, veins, lymphatics, and nerves, the entire mass being invested by a serous coat, the peritoneum, and a fibrous coat, which is blended with the serous investment; it is reflected into the interior of the liver as the capsule of Glisson. An examination of the lobules shows them to be about one-twelfth of an inch in diameter, and, viewed in the erect position, they may be said to be conoidal in form with undulate sides; so that a vertical section gives a foliated outline. The bases, by mutual pressure, are polygonal in outline.

Each lobule is surrounded by a plexus of the interlobular veins, which send off the lobular capillaries. These make an intricate net-work in the interior of the lobule, but ultimately empty into the intralobular vein, which runs from apex to base, through the axis of the lobule and empties into the sublobular vein. The bases of the lobules are applied to the sublobular veins, and these become the common drain for the lobules. The interspaces between the lobular capillaries are occupied by the hepatic cells, which are spheroidal in form and are about $\frac{1}{1500}$ inch in diameter. They consist of a sponge-work of protoplasm containing one or more distinct nuclei. The cell is devoid of cell-wall. The nuclei present bright nucleoli. The substance of the cell presents biliary coloring matter and oil-globules. The bile-ducts begin as intercellular passages, which probably open on the periphery of the lobule and form the interlobular plexuses, which may be considered to be the real commencement of the hepatic duct.

THE GALL-BLADDER.

The gall-bladder is situated in the fissure for the gall-bladder, and, when moderately distended, is pear-shaped, the large end of the pear projecting beyond the anterior border of the liver. It is about four inches long, one inch broad, and will hold from an ounce to an ounce and a half. It is held in position by the peritoneum. It presents a broad anterior end, the fundus, the body, and the neck. It has four coats: serous, muscular, fibrous, and mucous. The internal or mucous coat is tinged a bright yellow, and presents numerous wrinkles, which give it some resemblance to a honey-comb. Near the neck the mucous membrane forms valvular folds. The gall-bladder is lined by columnar epithelium. The ductus

communis choledochus is formed by the union of the hepatic duct with the duct of the gall-bladder. The latter is about one inch long; its lining mucous membrane is arranged in a spiral manner. This arrangement probably assists in filling the gall-bladder. The common bile-duct is about three inches long, is joined by the duct of the pancreas, and empties into the descending portion of the duodenum.

THE PANCREAS.

The pancreas is situated behind the peritoneum, just above the superior mesenteric vessels. It is about six inches long, one and a half inches at its greatest breadth, and one inch at the thickest part. It weighs about three ounces. It is a flat, tongue-like organ, which has no distinct investing capsule. It presents a a head, body, and tail. The head is received in the curve of the duodenum; the body is behind the stomach; the tail is small and pointed, and is in relation with the spleen. The upper border is thick, and presents the splenic groove for the accommodation of the splenic artery. The pancreatic duct runs through the middle of the gland from the tail to the head. It is called the duct of Wirsung, and is joined by a second duct,—the duct of Greenhow,—which arises from the lower part of the head of the pancreas. It is essentially a compound racemose gland, resembling the salivary glands.

THE SPLEEN.

The spleen is a ductless gland. It is situated in the left hypochondrium; it is of a dark-bluish color, about six inches long, three broad, an inch and a half thick, and weighs about five ounces. It is dense but friable, and is entirely invested by peritoneum. It is convex externally, slightly concave on the inner surface, where

it presents a longitudinal fissure—the hilum; its anterior border presents a notch. The spleen is invested by a fibrous coat, which contains involuntary muscular fibres and much yellow elastic tissue in its structure. It is reflected into the organ at the hilum, forming the large splenic canals. Its under surface sends off trabeculæ, which constitute the skeleton of the spleen. In truth, the spleen may be said to consist of a sponge-work of fibrous trabeculæ, derived from the fibrous coat. The meshes of the trabeculæ hold the splenic pulp. This consists of a dark-red substance, consisting of interlacing connective-tissue cells, forming a skeletal arrangement to support the pulp, which consist of blood-corpuscles in all stages of development and decay and free hæmoglobin. The splenic artery breaks up into minute capillaries, the walls of which consist of proliferating lymphoid elements. The capillaries open directly into the meshes of the spleen. The Malpighian corpuscles of the spleen are collections of lymphoid elements along the course of the arterioles; they are nodular masses, about one-fiftieth inch in diameter. The changes effected in the blood in the spleen are briefly the genesis of white corpuscles out of the lymphoid tissue; possibly, the genesis of the red corpuscle, and certainly the destruction of effete corpuscular elements and the liberation of the hæmoglobin.

THE KIDNEYS.

The kidneys, two in number, are placed against the posterior wall of the abdomen behind the peritoneum. They extend from the twelfth rib to the crest of the ilium, the right being a trifle lower than the left. They are about four inches long, two broad, and one thick; weigh about five ounces,—a little less in the female; of a dark-red color, friable—being readily torn—and com-

posed of an aggregation of tubular glands inclosed in a delicate, transparent, fibrous, investing structure,—the capsule of Bowman. The kidney presents for examination an anterior and posterior surface, inner and outer border, and a superior and inferior extremity. The anterior sur-

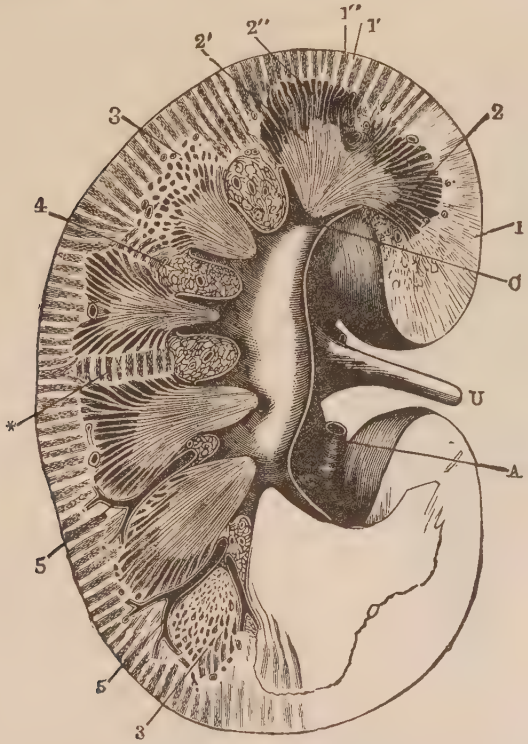

FIG. 166.—NAKED-EYE APPEARANCE OF THE KIDNEY.

1, cortex; 1', medullary rays; 1'', labyrinth; 2, medulla; 2', papillary portion of the medulla; 2'', boundary layer of the medulla; 3, transverse section of tubules in boundary layer; 4, fat of renal sinus; 5, artery; *, transversely coursing medullary rays; A, branch of renal artery; C, renal calyx; U, ureter.

face is convex and covered by peritoneum; the posterior surface is somewhat flattened. The outer border is convex and rounded; the inner border presents a notch leading into a vertical fissure—the hilum, which opens into the sinus of the kidney. The superior extremity is rounded and larger than the inferior; upon the superior

extremity rests the supra-renal capsule. Each kidney is imbedded in a quantity of firm fat.

If a section is made of the kidney it is seen to consist of two portions,—an outer or cortical, and an inner or medullary. The cortical matter consists of convoluted tubuli, Malpighian corpuscles, and vessels. The medullary portion consists of from sixteen to twenty conical masses of straight tubuli, called the pyramids of Malpighi. The cortical substance makes one-third, the medullary two-thirds of the section. The sinus of the kidney is occupied by the pelvis of the ureter, which is the upper distended portion of the tube; it presents three funnel-shaped depressions, called the infundibula,—the superior, middle, and inferior. The lining mucous membrane is thrown into ridges, which subdivide the infundibula into twelve to eighteen alveoli, called the calyces. The apices of the Malpighian pyramids present at the bottom of the calyces.

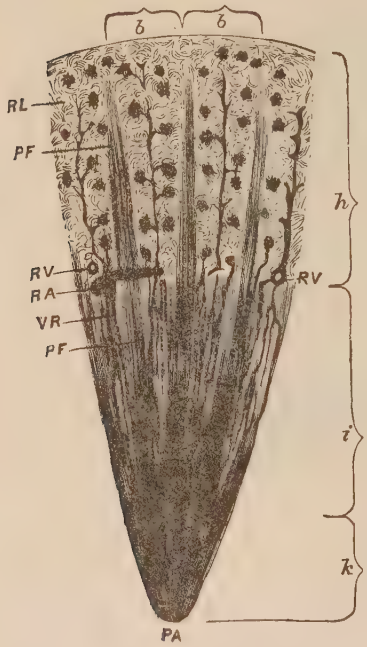

FIG. 167.—LONGITUDINAL SECTION OF A MALPIGHIAN PYRAMID.

PF, pyramids of Ferrein; RA, branch of renal artery; RV, lumen of a renal vein receiving an interlobular vein; VR, vasa recta; PA, apex of a renal papilla; b, b, embrace the bases of the renal lobules; h, cortex; i, boundary or marginal zone; k, papillary zone.

A minute examination of the apex of the pyramid reveals the open mouths of numerous tubuli, which should be carefully followed, so as to understand the structure of the kidney. The tubule proceeds in a straight direc-

tion for a short distance and divides; each branch then proceeds in a straight direction and divides; and thus, a single tubule at the apex of the pyramid will have

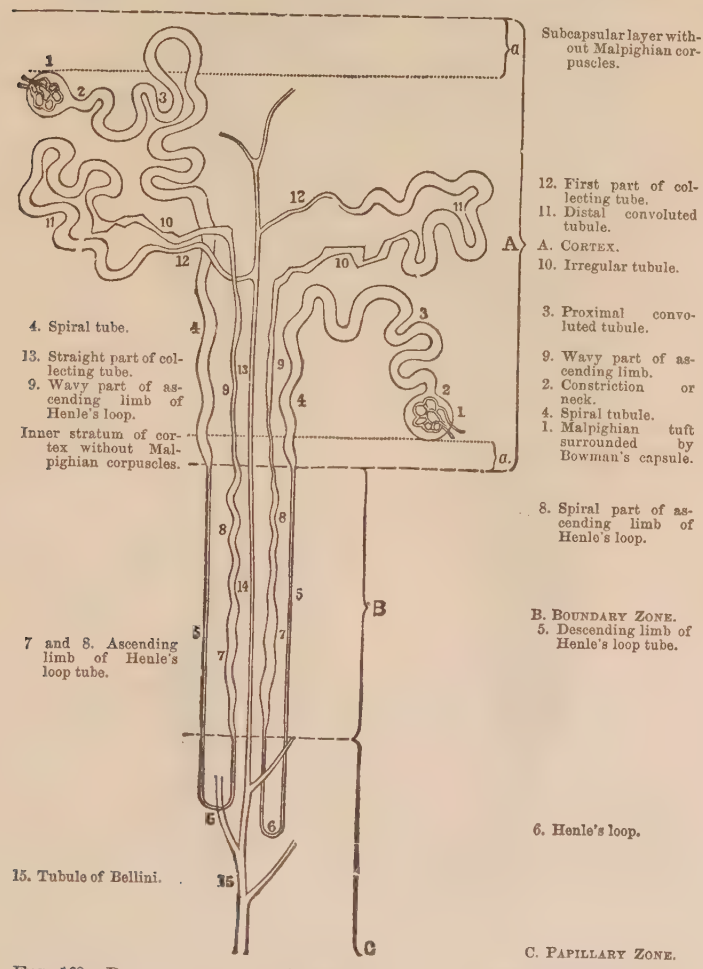

FIG. 168.—DIAGRAM OF THE COURSE OF THE URINIFEROUS TUBULES.

branched into a number of tubuli at the base of the pyramid; all the tubuli in the pyramid run in a straight direction, and are called the tubuli of Bellini. When it reaches the base of the pyramid the tubule sends off a



FIG. 169.—BLOOD-VESSELS AND URINIFEROUS TUBULES OF THE KIDNEY.

A, capillaries of the cortex; B, of the medullary; a, interlobular artery; 1, vas afferens; 2, vas efferens; r, e, vasa recta; c, venæ rectæ; v, v, interlobular vein; S, origin of a vena stellata; i, i, Bowman's capsule and glomerulus; x, x, convoluted tubules; t, t, Henle's loop; n, n, junctional piece; o, o, collecting tubes; O, excretory tube.

number of curved branches called the collecting tubes; these become much twisted, convoluted, and form the convoluted tubes of Ferrein, a name applied to all the tubuli

of the kidney, except the straight tubes of Bellini in the pyramids.

The curved or collecting tubule terminates in the distal convoluted tubule, this in the irregular tubule which leads into the loop of Henle, a contracted portion of the tubule, and which terminates in the spiral tubule. The spiral tubule terminates in the proximal convoluted tubule, which becomes contracted and then expands, forming the capsule of the Malpighian corpuscle. The

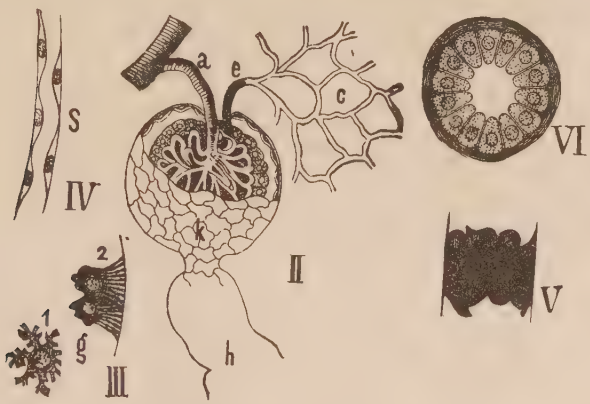

FIG. 170.—THE SECRETING PORTIONS OF THE KIDNEY.

II, Bowman's capsule and glomerulus; a, vas afferens; e, vas efferens; c, capillary network of the cortex; k, endothelium of the capsule; h, origin of a convoluted tubule; III, "rodded" cells from a convoluted tubule; 2, seen from the side, with, g, inner granular zone; 1, from the surface; IV, cells lining Henle's loop; V, cells of a collecting tube; VI, section of an excretory tube.

straight tubuli are lined with columnar epithelium throughout; the convoluted tubuli, up to the corpuscle, present a varied epithelium; in general, it may be said to be of the glandular type. The epithelium rests on a basement membrane, which is supported by a delicate fibrous coat.

The cortical substance dips down between the pyramids, forming the columns of Bertin. A single tubule becomes so multiplied by repeated divisions as to form a cone or pyramid, and the pyramids of Malpighi may be

defined to be a collection of cones or pyramids already described, and invested by delicate fibrous tissue.

The renal arteries enter the hilum and break up into a number of branches, which penetrate the columns of Bertin and reach the bases of the pyramids, over which they form anastomotic arches. From these are given off two sets of branches, the medullary (arteriolæ rectæ) and the cortical. The former supply the pyramids; the latter pass outward toward the periphery and send off numbers of capillary branches, which are very delicate and terminate in a spheroidal tuft of anastomosing capillaries located within the Malpighian capsule. The formation of the capsule is not fully understood, but it is supposed to be made by invagination, the tuft of capillaries resting within the capsule invested by the lining cells. Some believe it to hang free in the capsule; others claim that the tuft distends the capsule, but is shut out from the tubule by a partition layer of cells. The venous capillaries leave the corpuscle and follow the course of the arteries.

THE URETER.

The ureter or duct of the kidney runs from the pelvis of the kidney to the bladder. It is about seventeen inches long, half as thick as a lead-pencil, and is composed of three coats,—a fibrous, a muscular, and a mucous. The fibrous coat is continuous with the capsule of Bowman and is lost on the bladder. The muscular coat is formed by longitudinal and circular fibres, which become thinner toward the bladder. The mucous coat is formed of columnar epithelium in different stages of development, resting on a basement membrane. The mucous membrane is thrown into slight longitudinal folds. The upper, expanded part of the ureter forms the pelvis of the kidney. It dips into the infundibula

and forms the calyces. The lower end pierces obliquely the under surface of the bladder, and, after running about three-fourths of an inch in the wall of the bladder, opens at a posterior angle of the triangle at the base of the bladder.

THE SUPRA-RENAL CAPSULES.

The supra-renal capsules are ductless glands situated behind the peritoneum, upon the kidney. They are of a yellowish color, flattened, weigh about two drachms, and measure about one and a half inches in length. They have an outer cortical and an inner medullary portion. The cortical substance consists of columns perpendicular to the surface; the medullary portion is of a dark-brown color and pulpy consistence.

The cortical columns are derived from the inner surface of the fibrous capsule which invests the gland. They are abundantly supplied with vessels.

THE THYROID GLAND.

The thyroid gland is placed like a saddle across the upper part of the trachea; it presents the two lateral lobes and the isthmus; it is brownish-red in color, and weighs about one and a half ounces. The isthmus covers the second and third rings of the trachea; it is about one-half to three-fourths of an inch wide; the lobes are two inches long and about one inch in width; the gland is inclosed in a fibrous capsule, which sends inward supporting septa, dividing the gland into lobes and lobules; the lobules are formed of closed vesicles, lined by a single layer of cuboidal epithelium. The vesicles are filled with a gelatinous fluid, containing disintegrating red corpuscles and free hæmoglobin. The blood-capillaries and lymphatics form extensive plexuses around the vesicles. The thyroid has no duct.

THE THYMUS GLAND.

The thymus gland, with the thyroid, supra-renal capsules, and spleen, belongs to the ductless glands; it attains its greatest development about the second year, when it begins to atrophy, and, by the sixteenth year, has entirely disappeared; it consists of two lobes, situated in the anterior mediastinum, extending as low as the fourth costal cartilage; it is pink in color and lobulated, and weighs, when bestd eveloped, about an ounce; the lobes are formed of lobules, which present a cellular, cortical, and medullary portion; it is essentially a gland formed of lymphoid elements, and is probably concerned in the formation of red blood-corpuscles.

PELVIC VISCERA,

INCLUDING

ORGANS OF GENERATION.

THE PELVIS.

THE pelvis is bounded above by the superior plane of the true pelvis, formed by the linea ilio-pectinea, and the sacral promontory; below, by the levator ani muscle and the pelvic fasciæ; laterally and in front, by the ischia and pubes. It is a curved cylinder, which contains the bladder, rectum, uterus and its appendages, in the female; in the male, it contains the bladder, seminal vesicles, prostate, and rectum.

THE BLADDER.

The bladder is a musculo-membranous sac, which, when moderately distended with urine, is ovoidal in form, and then measures about five inches in length and three in width, and holds about one pint. When empty its walls are in contact, and it forms a small, triangular sac, placed deeply in the anterior part of the pelvic cavity; it presents for examination a summit, body, base, and neck; the summit is rounded, and has attached to it the urachus,—a fibrous structure, the remains of the allantois, and which passes upward to the umbilicus; at the sides of the urachus are the obliterated hypogastric arteries; the summit of the bladder, behind the urachus, is invested by peritoneum; the anterior parts of the summit and body are in contact with the abdominal wall, when the organ is sufficiently distended. The body of the bladder is convex, and covered posteriorly by peritoneum; at its sides are the vasa deferentia, curving downward

toward the base; also the ureters. The base of the bladder rests on the second part of the rectum, is triangular in form, and measures, when the organ is moderately distended, about two and a half inches from angle to angle. Passing backward to the rectum are two folds of peritoneum,—the recto-vesical. In the female the base of the bladder is firmly attached to the cervix uteri and upper part of the vagina. The neck of the bladder is the opening leading into the urethra; in the male it is surrounded by the prostate gland. The bladder is held in position by five true and five false ligaments; the true are the two pubo-prostatic, the two lateral, and the urachus; the false are the two lateral, the two posterior, and the superior, and are formed by the peritoneum.

The bladder has four coats,—serous, muscular, cellular, and mucous. The serous coat is derived from the peritoneum; it covers the posterior surface of the body and summit and the upper part of the base. The muscular coat consists of longitudinal and circular planes of fibres. The oblique muscles of Bell are delicate bands which pass across the openings of the ureters and are inserted near the neck of the bladder. The cellular coat is loose, and connects the muscular with the mucous coats. The mucous coat is thin, of a pinkish color, and when the organ is distended it is thrown into numerous folds or wrinkles. The epithelium is flat and squamous on the surface, columnar and transitional deeper down. Numerous racemose glands are found imbedded in the mucous membrane.

At the base of the bladder is the triangle; the anterior angle is at the opening of the urethra, the posterior angles at the openings of the ureters. The triangle is smooth, and closely adherent to the muscular coat. It is not thrown into wrinkles. At the opening of the urethra

is a slight elevation of the mucous membrane, called the uvula. The arteries of the bladder are derived from the internal iliacs, the nerves from the hypogastric plexuses.

THE MALE URETHRA.

The male urethra is a canal, from eight to nine inches long, which runs through the corpus spongiosum of the penis. It is divided into a prostatic, membranous, and spongy portion. The prostatic is the widest and most dilatable part. The urethra passes through the gland, in the middle line, above its centre. It measures about one and one-quarter inches in length; its transverse section forms a curve through the prostate, the convexity being upward. The following points are presented in the prostatic urethra. The veru montanum is a linear elevation of the mucous membrane on the floor of the prostatic portion. It becomes much distended during the erection of the penis, and prevents the regurgitation of the semen. On either side of the veru montanum is a sinus, upon the floor of which open numerous prostatic ducts. At the anterior part of the veru montanum is the sinus pocularis, within which open the ejaculatory ducts. The membranous portion is that part of the urethra between the two layers of the deep perineal fascia; it measures three-quarters of an inch along the upper and one-half of an inch along the inferior portion. It is encroached upon inferiorly by the prostate, and curves beneath the subpubic ligament. The spongy portion, about six inches in length, terminates at the meatus urinarius. The bulb of the urethra is the commencement of the spongy portion of the canal; it is dilated, and rests on the anterior surface of the anterior leaflet of the deep perineal fascia, called the triangular ligament. Near the termination of the urethra is the fossa navicu-

laris,—an expanded portion of the canal. The meatus is the smallest part of the urethra; it is a vertical, slit-like opening, which becomes elliptical when distended by the passing column of water. It is about one-quarter of an inch long, and is bounded laterally by two slightly-developed labia, joined by delicate commissures.

The mucous membrane of the urethra is continuous with that of the bladder, and externally with that of the glans. In the non-distended state the spongy and membranous urethra is thrown into longitudinal folds, and a section exhibits the urethra as a transverse slit, with its walls in contact. In the glans penis the flaccid urethra is a vertical slit. The entire urethral mucous membrane is studded with minute, tubular, mucous glands, known as the glands of Littré. One of these glands, called the lacuna magna on account of its size, is situated on the upper wall of the fossa navicularis. The epithelium is squamous and transitional, and columnar in the follicles and ducts. The muscular coat of the urethra consists of two layers,—an outer longitudinal and an inner circular. Their use is to expel the last drops of urine evacuated from the bladder into the urethra; they probably also assist in the ejaculation of the semen.

THE PROSTATE GLAND.

The prostate gland surrounds the neck of the bladder. It resembles a horse-chestnut in size and form, and is placed behind the symphysis pubis, and rests on the anterior wall of the rectum. Its broadened base surrounds the neck of the bladder. Its apex encroaches on the membranous urethra. It weighs about half an ounce; is about one inch long, one and one-quarter inches broad, and three-fourths of an inch thick, and consists of two large, symmetrical, lateral lobes and a small central lobe.

The prostate is pierced by the ejaculatory ducts and urethra. The ducts empty anterior to the veru montanum, on the floor of the prostatic urethra. The prostate is of a grayish color, and consists of a stroma of involuntary muscular tissue and some connective tissue. It is invested by a fibro-muscular capsule. A muscular investment is also given to the urethra, as it runs through the prostate. In the alveoli of the sponge-work of muscle and some fibrous tissue is the glandular substance of the prostate. It is composed of dilated follicles, which empty into ducts. They open on the floor of the prostatic urethra. The prostate undergoes changes at different ages; thus, it is relatively slightly developed in infancy, and very apt to undergo great enlargement at old age, and may become infiltrated with small calculi of organic matter and carbonate of lime.

COWPER'S GLANDS.

Between the two leaflets of the deep perineal fascia are Cowper's glands, each about the size of a pea. They are of a grayish color, and each has a duct which opens on the floor of the bulbous urethra.

THE PENIS.

The penis is the genito-urinary organ, composed of erectile tissue. Its lower portion transmits the urethra. It presents for examination a root, a body, and the glans. The root consists of two crura, which are attached to the ascending rami of the ischia and descending rami of the pubes. Anterior to the symphysis pubis they join and form the corpora cavernosa. A fibrous ligament passes down from the pubes and constitutes the suspensory ligament of the penis. The body of the penis is that portion between the root and the glans. In the flaccid state it is cylindrical and pendent; in the erected state it

is trilateral or prismoidal in form and firm and erect in position. Its upper surface is broad, and is called the dorsum. The skin of the penis is very thin and loosely attached to the underlying structures; at the glans it becomes reduplicated, forming a cuff of skin, which covers the glans, and is called the prepuce. The superficial fascia rarely contains any fat-vesicles except at advanced age. The glans penis is covered by mucous membrane, which also lines the inner surface of the prepuce. The extremity, or glans, is fashioned like a horse-chestnut, with its broad base attached to the body of the penis. At the apex of the glans is the vertical meatus urinarius. At the inferior part is the frænum, a fold of mucous membrane between the labia of the meatus and the prepuce. The glans presents a rounded border, the corona; behind this is the cervix, which is provided with numerous sebaceous follicles, the glands of Tyson, which secrete sebaceous matter having a strong odor.

The penis is formed of the two corpora cavernosa above and side by side, and the corpus spongiosum beneath, in the groove between the corpora cavernosa. The corpora cavernosa are two cylindrical structures, which consist of an exterior fibrous coat, from the interior of which trabeculæ pass off and form a fibrous sponge-work or net-work, which contains the erectile tissue in its meshes. The two corpora cavernosa are but imperfectly separated by an incomplete septum, called the pectiniform septum. Erectile tissue consists of a plexus of anastomosing veins or venous sinuses, which, when filled, entirely distend the meshes in the fibrous sponge-work of the corpora cavernosa. During active erection the blood in the sinuses is arterial and bright-red. In the flaccid state of the organ the blood is dark in color. The veins terminate principally in the dorsal vein, which

pierces the suspensory ligament and empties into the prostatic and pelvic plexuses. The corpus spongiosum commences in front of the triangular ligament as an enlargement called the bulb. It incloses the urethra, and lies beneath and between the two corpora cavernosa. Anteriorly it becomes much expanded, and forms the glans, which is applied against the anterior blunt ends of the corpora cavernosa. The arteries of the penis are derived from the internal pudics and are distributed to the trabeculæ of the corpora cavernosa and empty into the sinuses. The artery of the bulb, also a branch of the internal pudic, supplies the corpus spongiosum.

THE TESTES.

The testes are two ovoidal organs, which secrete the semen; they are developed in the abdominal cavity, but about birth descend, through the contraction of a fibrous structure,—the gubernaculum,—into the scrotum, —a fibro-serous pouch or bag which hangs behind and below the penis. The scrotum is divided into symmetrical halves by the raphe; the skin and underlying dartos are pigmented, and present numerous short, stiff hairs and sebaceous follicles; it is thrown into a great number of rugæ by the contraction of the involuntary muscular fibres in its structure. From the inner surface of the dartos a septum is given off, which divides the scrotum into two pouches, within which the testicles lie, invested by the intercolumnar fascia, cremaster muscle and fascia, the infundibuliform process of the transverse fascia, and the tunica vaginalis. The intercolumnar fascia is a thin, delicate lamina, carried in front of the testicle as it passes through the external inguinal ring; the cremaster muscle and fascia are derived from the lower border of the internal oblique and transversalis; the transverse fascia

invests the cord, having been carried before the testis in its descent. The tunica vaginalis is a fold of peritoneum pushed before the testis; after birth its connection with the abdominal peritoneal cavity is obliterated. It invests the testicles and lines the interior of the scrotal pouch.

The testes are suspended by the spermatic cord, which are formed of arteries, veins, nerves, lymphatics, and the

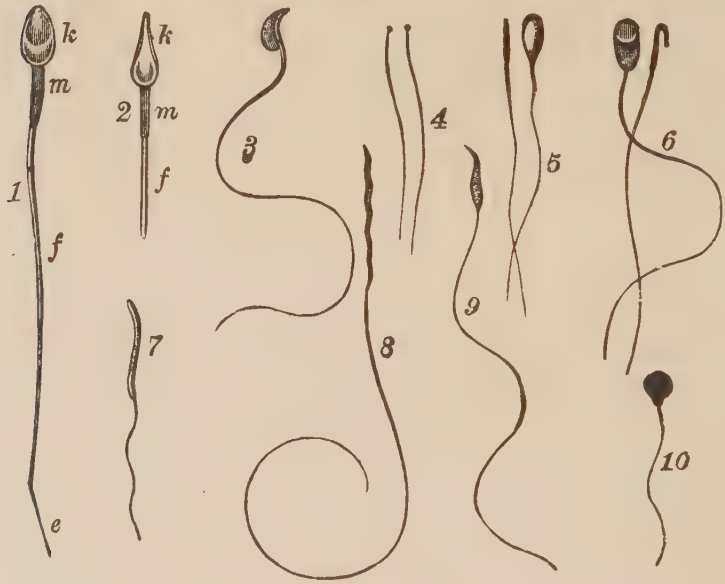

FIG. 171.—SPERMATOZOA.

1, human (× 600), the head seen from the side; 2, on edge; k, head; m, middle piece; f, tail; e, terminal filament; 3, mouse; 4, bothriocephalus latus; 5, deer; 6, mole; 7, green woodpecker; 8, black swan; 9, from a cross between a goldfinch (m) and canary (f); 10, cobitis.

vas deferens or excretory duct of the testicle. These structures conjoin at the internal abdominal ring, and pass along the inguinal canal to the testis. The testes are ovoidal in form, about one and three-fourths inches long, and weigh about an ounce each, and each is surmounted by a tail-like body,—the epididymis,—which consist of a body and the globus major (the head) above; the globus minor (the tail) below. The testis is invested

with the tunica vaginalis,—a serous sac derived from the peritoneum. The tunica albuginea is the white, fibrous, investing structure of the testis; it sends off fibres from the upper surface of the testicle, forming an incomplete septum, and also trabeculæ, which support the glandular structure. The tunica vasculosa consists of a plexus of capillaries, which lines the inner surface of the tunica albuginea. The testes are tubular glands; the tubuli are highly convoluted, each about eight feet in length, and about five hundred in number; they are about $\frac{1}{150}$ inch in diameter, and consist of a basement membrane, upon which are several layers of cells; the cells of the innermost layer become fibrillar, and undergo transformation into the spermatozoa, which are simply modified epithelial, ciliated cells.

The tubules, in groups of from three to five, are inclosed in delicate fibrous tissue, derived from the tunica albuginea; each group constitutes a lobule; near the termini of the tubules they become straight, and unite to form twenty or thirty larger ducts, each about one-fiftieth inch in diameter, which run along the upper border to the head of the epididymis; these larger ducts are called the vasa recta and unite so as to form about fifteen vessels, which perforate the tunica albuginea and become convoluted, forming the globus major of the epididymis. Each convolution of the globus major consists of a tubule six or seven inches long, and these open into a large, single, highly-convoluted tube, which forms the body and globus minor of the epididymis. So extraordinary are the convolutions of the tube forming the body and tail of the epididymis, that it measures, when carefully unraveled, about twenty feet. The globus minor terminates in the vas deferens. It is a strong, fibrous duct, which feels not unlike a whip-cord, and is

about one-eighth inch in diameter, and passes up the spermatic cord to the internal abdominal ring; it then descends into the pelvis, at the side of the bladder, to its base, where it runs along the inner side of the seminal vesicle; here it becomes much enlarged and sacculated; it then becomes contracted, unites with the duct of the seminal vesicle, and forms the ejaculatory duct, which opens on the floor of the prostatic urethra, in front of the veru montanum.

THE SEMINAL VESICLES.

The seminal vesicles are two tubular saculated structures which serve as reservoirs for the semen. They are situated against the base of the bladder. Each sac is about two and one-half inches long and one-third of an inch in width. They consist of a single convoluted tube having a series of pouches or alveoli. When uncoiled each seminal vesicle is found to be a long tube about one-twelfth of an inch in diameter and five inches long. It terminates in a narrow duct, which joins the vas deferens to form the ejaculatory duct, which is about an inch long and opens in front of the veru montanum. The seminal vesicles have an outer fibrous, a middle muscular, and an internal mucous coat. The mucous membrane of the vasa recta and epididymis is of the ciliated variety; throughout the vas deferens and ejaculatory duct it is of the columnar variety.

THE FEMALE ORGANS OF GENERATION.

The female organs of generation are divided into external and internal. The external are the mons veneris, the labia majora, the labia minora, the clitoris, meatus urinarius, vaginal orifice,—all comprised under

the name of *vulva*. The mons veneris is a cushion of fat placed above the pubes. It is covered with hair. The labia majora are two folds which elliptically surround the genito-urinary fissure. They are continuous above, but become less marked as they descend. They are connected posteriorly by the posterior commissure. The skin of the labia is pigmented, covered by short hair, and is lined internally by mucous membrane. Stretched between the posterior extremities of the labia is a delicate fold of mucous membrane, the fourchette. The depression between it and the posterior commissure is called the fossa navicularis. The labia minora are two well-marked folds of mucous membrane which project from the inner border of each labium and are continuous with one another across the clitoris, where they separate into two layers inclosing the clitoris, forming its prepuce. They are entirely deficient at the posterior third of the genital fissure. They consist of mucous membrane inclosing erectile tissue. They are abundantly supplied with mucous and sebaceous glands. The clitoris is situated in the median line, below the junction of the labia majora anteriorly and between the labia minora. It arises by two crura from the rami of the ischium and pubes, and consists of two adjoining corpora cavernosa surmounted by a glans.

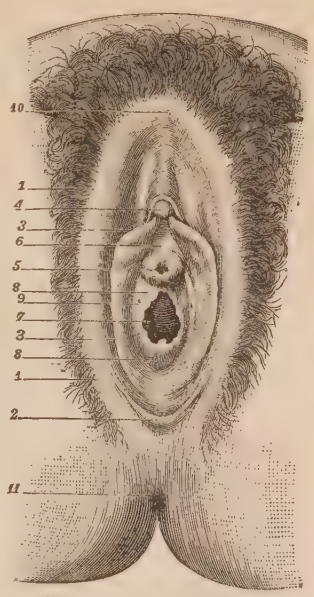

FIG. 172.—THE VULVA.

1, labia majora; 2, fourchette; 3, labia minora; 4, clitoris; 5, meatus urinarius; 6, vestibule; 7, orifice of vagina; 8, hymen; 9, orifice of duct of vulvo-vaginal gland; 10, anterior commissure; 11, anus.

It is bound down by the labia minora, and when erected simply advances toward the vaginal orifice. Below the clitoris is a triangular space called the vestibule, at the lower part of which, about three-fourths of an inch below the clitoris, is the meatus urinarius. It presents, as a rule, a prominent border. Below the meatus is the vaginal orifice, which is partially closed in the virgin by a thin, membranous fold called the hymen. This structure is commonly a semilunar fold stretched across the opening posteriorly, but it may be a diaphragm with a central opening or a number of apertures, circular, elliptical, or linear. It may be rudimentary or immensely thickened and fibrous, and its absence or destruction is never to be taken as a test of the chastity of the individual. After its rupture, small, nodular elevations surround the vaginal orifice called the myrtiform caruncles. The glands of Bartholine are situated at the sides of the vagina near its orifice. They are about the size of a pea and open by long ducts anterior to the vagina, close to the meatus. Below the mucous membrane of the vestibule is a quantity of erectile tissue arranged in the form of two bulbs connected by an intermediate portion. The pelvic or internal genito-urinary organs are the bladder, urethra, vagina, uterus, Fallopian tubes, ovaries, and associate parts.

THE URETHRA.

The urethra is a membranous canal about one and a half inches in length. It extends from the neck of the bladder to the meatus. It runs in the anterior wall of the vagina, is about one-quarter of an inch in diameter, but highly distensible, and has three coats,—muscular, erectile, and mucous. The erectile coat is analogous to the corpus spongiosum of the male.

THE VAGINA.

The vagina is a curved cylindrical canal which extends from the vulva to the uterus. It is about four inches along the anterior and six inches along the posterior wall, and is attached above to the cervix uteri. Its orifice is the most constricted portion. It presents three coats,—erectile, muscular, and mucous. The

FIG. 173.—NATURAL POSITION OF THE PELVIC ORGANS, WITH FULL BLADDER.

erectile coat consists of an abundant venous plexus, supported by connective tissue. The muscular coat has an outer circular and an inner, thick, longitudinal layer of fibres. The mucous membrane is loosely attached to the muscular coat, presents anteriorly and posteriorly a vertical column, from which pass off numerous transverse rugæ. They are all obliterated when the organ is distended. The epithelium of the vagina is of the squa-

mous variety. The vagina is interposed between the bladder and rectum. It corresponds to the axis of the pelvis, but is a movable organ, and its position is influenced by the degree of distension of either the bladder or rectum. On section, its walls are seen to be in contact, and it appears as a transverse slit.

THE UTERUS.

The uterus is the organ of gestation. It is a muscular organ, having thick walls and a small cavity. In the virgin, it is pear-shaped and sets in the upper portion of the vagina as a cork in the neck of a bottle. It is slightly flattened antero-posteriorly. Its upper broad end presents forward and upward; its lower end is directed downward and backward, and forms an angle with the vagina. It is one inch thick, two inches broad, and three inches long. Its walls are about half an inch thick, and it weighs about one and a half ounces. It is divided into a fundus, body and neck. The fundus is the upper portion of the organ. It is broad, convex, and covered by peritoneum.

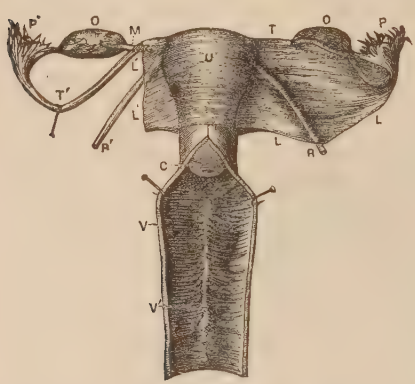

FIG. 174.—INTERNAL GENITAL ORGANS.
U, uterus (anterior surface); O O', ovaries; P P', fimbriæ; C, intra-vaginal portion of cervix; R R', round ligaments; V V', vagina laid open; L L', broad ligaments; M, ovarian ligament; T T', Fallopian tubes.

The body may be said to represent the frustum of a cone, which begins at the fundus and narrows toward the cervix. Anteriorly its upper part is covered by peritoneum, which also covers the posterior surface of the body. Laterally it affords attachment to the Fallopian

tubes, ligaments of the ovaries, and the round ligaments. The vessels ascend at the sides of the body. The cervix, or neck, is the constricted portion around which is attached the vagina. The inferior extremity of the uterus presents in the upper part of the vagina. At its centre is the os uteri, which is the outlet of the uterine canal. It is a transverse opening, about the size of a flattened straw. The os is bounded by the anterior short and thick lip, and the posterior long and narrow lip. The uterus is held in place by three pairs of ligaments, formed by the peritoneum: two anterior, the utero-vesical; two poste-

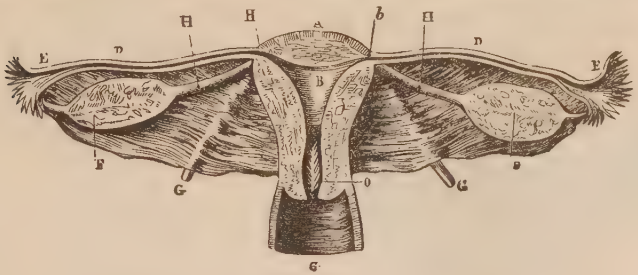

FIG. 175.—INTERNAL GENITAL ORGANS, SHOWING CAVITY OF UTERUS AND FALLOPIAN TUBES.

A, fundus; B, cavity of body of the uterus; O, cavity of cervix; D D, canals of Fallopian tubes cut open; E E, fimbriated extremities laid open; F F, ovaries, with Graafian follices; G, cavity of vagina; H H, ovarian ligaments; G G, round ligaments.

rior, the utero-rectal, which form the lateral boundaries of Douglas's *cul-de-sac*; and the two lateral, or broad ligaments, attached to the sides of the uterus. They pass outward to the sides of the pelvic cavity, dividing it into an anterior and posterior portion. The cavity of the uterus is divided into the cavity of the cervix and the cavity of the body, each about one and a quarter inches long. The cavity of the cervix is fusiform in shape, and communicates with the cavity of the body through the ostium internum. The mucous membrane along the anterior and posterior walls of the cavity of the cervix presents longitudinal columns, from which pass

oblique folds. The entire arrangement is designated the arbor vitæ uterina. The cavity of the body is triangular, flattened from front to back, and communicates with the cavity of the cervix at the inferior angle by the ostium internum. The superior angles lead into the Fallopian tubes, the orifices being each about the diameter of a bristle. The anterior and posterior walls are in contact.

The uterus has three coats,—serous, muscular, and mucous. The serous coat is derived from the peritoneum, which invests the posterior surface of the body, passes over the fundus, and descends as far as the upper half of the anterior surface of the body, whence it is reflected on the bladder. The muscular coat, composed of involuntary fibres, is about one-half inch thick, and disposed in three layers, the external consisting of a plane of fibres, which cover the organ. These fibres converge at the angles and form the round ligaments, some fibres passing over the Fallopian tubes and the ligaments of the ovary. The superficial plane of muscular fibres is an erectile plane, and assists in disposing the organ in a position favorable to fecundation. The middle layer is thick and irregular in distribution. The inner layer consists of two spiral laminæ arranged around the superior angles and the openings of the Fallopian tubes, for which they form a sort of sphincter.

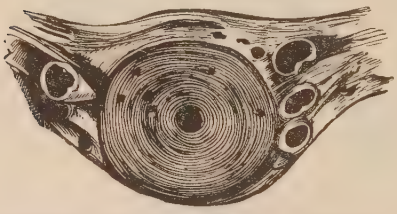

FIG. 176.—SECTION OF UTERUS THROUGH THE OSTIUM INTERNUM.

The mucous coat adheres closely to the muscular coat; it is continuous with the mucous membrane of the Fallopian tubes and the vagina. In the cavity of the body it is ciliated, but only a few ciliated epithelia are found in the cavity of the cervix, where the prevailing epithe-

lium is columnar. Great numbers of mucous follicles are imbedded in the mucous membrane of the uterus. Sometimes they become closed and then distend, forming slight elevations, called the ovula of Naboth. The uterine arteries are remarkably tortuous, and anastomose freely. The veins are sinuses which channel the substance of the organ. The uterus is extraordinarily supplied with sympathetic nerves. These form multiple ganglia in the substance of the organ.

FALLOPIAN TUBES.

The Fallopian tubes transmit the ova from the ovaries into the cavity of the uterus. They are two tubes, each about four inches long, which extend transversely outward from the superior angles of the uterus. They are inclosed within the free border of the broad ligament, and terminate externally in an expanded opening, the ostium abdominale, surrounded by fringe-like processes,—the fimbriæ. The tube has three coats,—serous, from the peritoneum, muscular, and mucous. The last is thrown into numerous longitudinal folds, and is covered by ciliated epithelium.

THE OVARIES.

The ovaries are two almond-sized and shaped bodies, situated in the broad ligament and attached to the outer extremity of the Fallopian tube by one of the fimbriæ and by the other end through the ligament of the ovary to the angle of the uterus behind the Fallopian tube. They are of a yellowish color, slightly irregular on their surface. Each ovary is composed of a loose, fibrous investment, from which is derived the stroma or sponge-work of the ovary, and in the meshes of which are the Graafian vesicles. The stroma consists of fibro-muscular structure, vessels, and nerves. A Graafian vesicle, when mature,

is about the size of a pea, consisting of two coats,—an outer fibro-vascular and an inner, called the ovi capsule, and which is lined by a layer of cells. These at a certain place accumulate and form a bed, the discus proligerus, in which the ovum is imbedded. The ova are formed by the involution of the germ epithelium from the surface of the ovary. They are gradually inclosed by the stroma and removed from the surface.

FIG. 177.—SECTION OF AN OVARY.

e, germ epithelium; 1, large-sized follicles; 2, 2, smaller-sized follicles; o, ovum within a Graafian follicle; v, v, blood-vessels of the stroma; g, cells of the membrana granulosa.

The ovum is a perfect cell, having a thick cell-wall, nucleus, and nucleolus. It is about $\frac{1}{150}$ inch in diameter. Its cell-wall is called the vitelline membrane; it is broad, clear, and shining, and appears as a bright ring; the dark, granular contents are known as the vitellus, or yelk, and within this is imbedded a bright, clear nucleus, about one-fourth the diameter of the ovum. It is called the germinal vesicle, and contains a dark nucleus,—the germinal spot, which measures about $\frac{1}{2400}$ inch in diameter. Before puberty the Graafian vesicles are undevel-

oped, and scattered profusely through the ovary. They measure about $\frac{1}{100}$ inch in diameter. At puberty they begin to mature, approach the surface of the ovary, and burst. The ruptured vesicle becomes distended with blood, forming the corpus luteum, which is a yellowish scar left after the rupture of the vesicle. This process is repeated in the human subject, during her menstrual life, regularly under normal conditions every twenty-eight days until interrupted by fecundation. Lying near the ovaries is the organ of Rosenmüller,—a relic of fœtal life.

The round ligaments are attached to the angles of the uterus in front of the Fallopian tubes; they are about four inches and a half long, and run along the inguinal canal, to become lost in the structure of the labia majora. The ligament of the ovary is formed of muscular fibre, and is attached to the superior angle of the uterus behind the Fallopian tubes.

THE MAMMARY GLANDS.

In the female the mammary glands are two large hemispherical structures placed upon the anterior part of the chest between the third and the seventh ribs. They undergo remarkable development at puberty, increase in size during pregnancy, and subserve the function of lactation. They are surmounted by a conical structure,—the nipple. The skin of the nipple, and for some distance surrounding it, is deeply pigmented and abundantly provided with large sebaceous follicles. The gland-tissue of the mammæ consists of lobes, these of lobules, these of clusters of vesicles. They are lined by epithelium which, during lactation, undergoes fatty change. The vesicles empty into minute tubuli, these into larger, and finally converge to form from fifteen to twenty ducts that open on the surface of the nipple.

They form slight dilatations, which become milk reservoirs. Between the lobes of the mammæ is a large amount of fat. The lobules are held together by connective tissue. The breasts are abundantly supplied with blood.

SPECIAL SENSES.

THE EYE.

THE eye is the organ of sight. It is placed in the orbital cavity, which protects it from injury. The eyeball is movable in all directions by the muscles attached

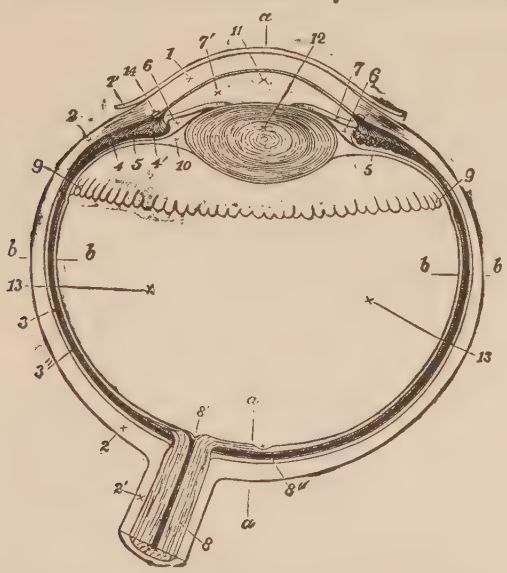

FIG. 178.—DIAGRAM OF A HORIZONTAL SECTION THROUGH THE HUMAN EYE.
1, cornea; 2, sclerotic; 3, choroid; 4, ciliary processes; 5, suspensory ligament of lens; 6, so-called posterior chamber between the iris and the lens; 7, iris; 8, optic nerve; 8', entrance of central artery of retina; 8'', central depression of retina, or yellow spot; 9, anterior limit of retina; 10, hyaline membrane; 11, aqueous chamber; 12, crystalline lens; 13, vitreous humor; 14, circular venous sinus which lies around the cornea; a a, antero-posterior, and b b, transverse axes of bulb.

to it, and is capable of a wide range of vision. It is imbedded in a quantity of loose fat, from which it is separated by a flattened serous sac,—the capsule of Tenon.

The eyeball consists of the segments of two spheres,—a smaller anterior, constituting one-sixth, and

a larger posterior portion, which forms five-sixths of the eyeball. The eyeball measures twenty-five millimetres antero-posteriorly, twenty-four millimetres transversely, and twenty-three millimetres vertically. It is held in place by the optic nerve, muscles, and palpebral structures. The optic nerve enters the posterior portion of the eyeball a trifle to the nasal side of the centre; it pierces the two outer coats, and expands to form the retinæ. The visual axes of the eyeballs are parallel; the axes of the orbits diverge. The eyeball presents three coats or tunics,—the outer, formed by the sclerotic and cornea; the middle, formed by the choroid, ciliary processes, and the iris; and the inner, called the retina. The refracting media are the vitreous and aqueous humors and the crystalline lens. The accessory refracting media are the cornea and capsule of the lens.

THE SCLEROTIC.

The sclerotic is a dense, white, fibrous structure which invests the posterior five-sixths of the eyeball, and serves to maintain it in form. It is thicker at the posterior part, where it presents numerous foramina for the transmission of vessels, and called the lamina cribrosa. It is about one millimetre in thickness, smooth externally, grooved internally by the ciliary nerves. The cornea is the transparent segment which forms the anterior one-sixth of the eye. It is about one millimetre thick, non-vascular, almost circular, and sets in the anterior margin of the sclerotic like the crystal of a watch on its case. It is composed of five layers,—the outer, the conjunctival mucous membrane, formed of flat, transitional, and columnar cells; the second, or anterior elastic lamina, composed of dense fibrous tissue, and measures about $\frac{1}{1500}$ inch in thickness; the central layer, or true cornea,

is continuous with the sclerotic, and is formed of fifty or sixty loosely-woven layers of fibrous tissue held together by a cement substance. In the meshes of these lamellæ are the corneal spaces, containing connective-tissue cells. The posterior elastic lamina is a brittle, homogeneous structure about $\frac{1}{1000}$ inch in thickness. When fractured, its tendency is to roll inward. The internal epithelial layer consists of a single layer of flat cells lining the posterior surface of the cornea.

THE CHOROID.

The choroid is the vascular tunic of the eye; it is attached to the sclerotic by delicate connective tissue,—the lamina fusca,—and invests the posterior five-sixths of the eyeball; it terminates abruptly at the ciliary ligament, and divides, forming the iris and ciliary processes. The choroid is formed of an outer, coarse, vascular, and an inner capillary layer, containing scattered pigment cells. Posteriorly it is pierced by the optic nerve. The ciliary ligament is a band of involuntary muscular fibres, about three millimetres in width, thicker in front than behind, and attached to the anterior portion of the choroid, to the anterior margin of the sclerotic, and internally to the iris and ciliary processes. The iris is a circular, vertical, muscular, perforated curtain, suspended between the cornea and crystalline lens; it presents an anterior and posterior surface, and the perforation or pupil. The surfaces are covered by flat cells, continuous with the endothelial lining of the cornea. A few fibres pass at intervals from the posterior elastic lamina of the cornea; they constitute the pectiniform ligament of the iris. The spaces between these fibres are the spaces of Fontana. These communicate with a circular sinus,—the canal of Schlemm,—which runs near the junction

of the ciliary ligament with the sclerotic. The posterior surface is of a deep-purple color, which is due to a layer of pigment-cells, and is called the uvea. The iris is formed of circular and radiating fibres, and, when viewed posteriorly, the arrangement resembles a wheel; the circular or sphincter fibres are arranged hub-like around the pupil, the dilator fibres spoke-like from the pupil to the circumference. The hub fibres of the iris surround the pupil and form its sphincter, which is supplied by the third nerve; the spoke fibres dilate the pupil; they are supplied by the sympathetic. The ciliary processes are sixty to eighty minute, pointed processes, each about one-tenth inch long, and formed by an involution of the deeper layer of the choroid. They form a pigmented band, which rests upon and impresses the anterior surface of the suspensory ligament of the lens; these impressions are frequently pigmented, and constitute the zone of Zinn.

THE RETINA.

The retina is the nervous tunic of the eyeball; it is formed by the expansion of the optic nerve, and terminates anteriorly, in an irregular, frayed-out margin,—the ora serrata. The retina presents the optic disk, the entrance of the optic nerve, and which is pierced by the arteria centralis. Vision at this point is wanting. About one-tenth inch to its other side, and at the principal focus of the rays of light, is the yellow spot of Sömmering; at this point vision is most acute. The retina here is very thin, and is formed mainly by the close grouping of the cones. At the centre of the yellow spot is a depression,—the fovea centralis. The retina is composed, from without inward, of the following ten layers:—

1. The pigmentary layer is applied to the choroid;

it consists of a pavement of accurately-jointed hexagonal pigmented cells.

2. The layer of rods and cones, or Jacob's membrane, consists of rods and cones, arranged perpendicularly to the surface. They each consist of an inner and outer segment, connected together by a cement substance. The outer segments are transversely striated, the inner segments striated and granular.

3. External limiting membrane, a lamina of cellular tissue.

4. Outer nuclear layer, consisting of bipolar cells transversely striated, called rod granules. They are connected by one extremity with a rod; the other enters the outer molecular layer. The cone-granules, less in number, are multipolar, nucleated cells, which are connected by numerous processes with the cone, and terminate internally in a single pole, which passes into the outer molecular layer.

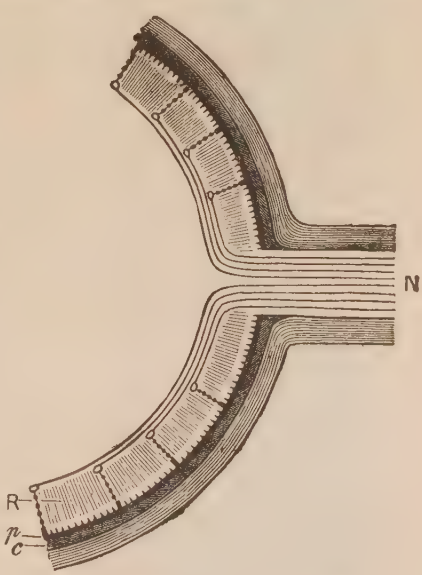

FIG. 179.—DIAGRAM OF THE FORMATION OF THE RETINA.

N, optic nerve; R, retina; p, pigment layer; c, choroid.

5. The outer molecular layer consists of a net-work of delicate fibres, with some ganglion cells. It has a granular appearance.

6. The inner nuclear layer consists of bipolar, nuclear cells, the poles of which communicate with a ganglion cell and a rod or cone.

7. The inner molecular layer is a thick layer, granular in appearance, which is formed of a dense net-work of fibres, imbedded in which are some ganglion cells.

8. Ganglion cell-layer, a single layer of large flask-shaped cells, having an inner pole, which communicates with an optic-nerve fibre, and several external branched poles, which pass into the inner molecular layer.

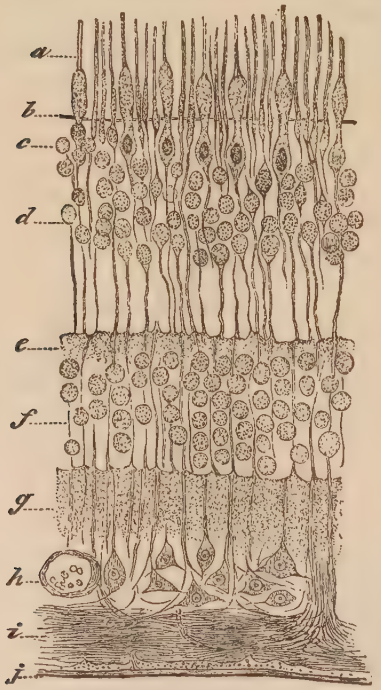

FIG. 180.—VERTICAL SECTION OF HUMAN RETINA.

a, rods and cones; b, external, j, internal limiting membranes; c, external, and f, internal nuclear layers; e, external, and g, internal granular layers; k, blood-vessel and nerve-cells; i, nerve-fibres.

9. Optic-nerve fibre-layer consists of a layer of naked axis-cylinders, which pierce all the other layers of the retina. They radiate from the disk, and also form frequent plexuses. Some communicate with the ganglion cells, others pass outward through the molecular layer.

10. The membrana limitans interna is formed of cellular tissue.

The retina is supported by a connective-tissue stroma, arranged between the internal and external limiting membranes. Between these pass columns of connective tissue, from which pass off skeletal supporting fibres.

The Humors of the Eye.—The aqueus fills both the anterior and posterior chambers of the eye. It contains a trace of chloride of sodium, is alkaline in

reaction, and weighs about four grains. The anterior chamber is bounded in front by the cornea, behind by the anterior surface of the iris. The posterior chamber is limited in front by the iris, behind by the suspensory ligament and ciliary processes. In the fœtus a delicate membrane, the membrana pupillaris, is stretched across the pupil. It becomes absorbed about the seventh month.

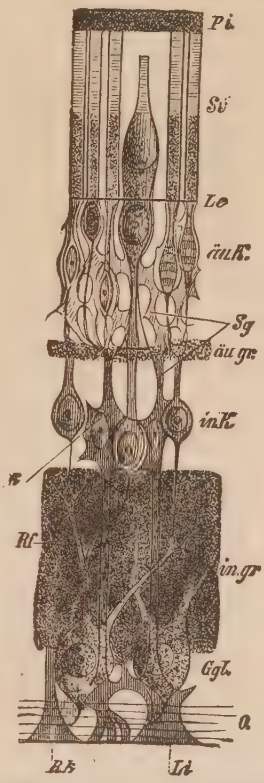

FIG. 181.—LAYERS OF THE RETINA.

Pi, hexagonal pigment cells; St, rods and cones; Le, external limiting membrane; äuK, external nuclear layer; äugr external granular layer; inK, internal nuclear; ingr, internal granular; Ggl, ganglionic nerve-cells; O, fibres of optic nerve; Li, internal limiting membrane; Rk, fibres of Müller; K, nuclei; Sg, spaces for the nervous elements.

The vitreous humor is inclosed in a sac called the hyaloid membrane. It fills the posterior four-fifths of the eyeball. It is transparent, albuminous, and slightly gelatinous. Anteriorly it is concave, and accommodates the crystalline lens. A leaflet of the hyaloid membrane passes to the margin of the lens, forming its suspensory ligament. The interval between this and the lens forms a canal, the sinus of Petit. In the fœtus very delicate septa are found throughout the vitreous humor. Running through the centre of the vitreous is the canal of Stilling, formed by the hyaloid membrane.

The crystalline lens is a biconvex, plastic body, invested by a capsule. It is placed behind the pupil, and rests in a depression in the vitreous humor. In front it

is in contact with the iris. Its margin is overlapped by the ciliary processes. The capsule is a homogeneous membrane, about $\frac{1}{3000}$ inch thick, which, when ruptured, has a strong tendency to roll inward. It is separated anteriorly from the lens proper by a single layer of transparent cells, which after death absorb moisture, become cloudy, forming the liquor Morgagni. The lens is about one-third of an inch transversely and one-quarter of an inch thick. It is an albuminoid structure, formed of numerous laminæ, soft externally, becoming firmer, and inclosing a hard nucleus. The laminæ consist of hexagonal prisms, with serrated edges, accurately adjusted to each other. Each prism measures about $\frac{1}{5000}$ inch in thickness. They are arranged to form three segments,—best demonstrated by immersing the lens in strong alcohol.

The *appendages of the eye* are the orbital muscles, —described in the earlier part of the book,—the eyelids and eyebrows, the conjunctiva, lachrymal gland and sac, and nasal duct.

The eyelids are two thin folds placed in front of the eye. The upper is the larger and more movable. When the lids are separated they disclose an elliptical fissure the angles of which are called the canthi. At the outer canthus the lids are joined at an acute angle. The inner canthus presents a triangular notch called the lacus lacrymalis. At the commencement of the lacus is a rounded elevation on each lid; upon the surface of each opens the punctum lacrymale.

The eyelids are composed of skin, cellular tissue, the fibres of the orbicularis palpebrarum, tarsal cartilages and ligaments, Meibomian glands, and conjuctiva. The upper lid presents, also, the aponeurosis of the levator palpebræ superioris. The skin is very thin, the

cellular tissue lax, and contains no fat. The palpebral fibres of the orbicularis are thin, pale, and more movable than the rest of the muscle. The tarsal cartilages are two thin, crescent-shaped fibroid structures, each about one inch long, placed on the free margin of the lids, along which they present a nearly straight, thick edge. Extending between the outer extremities of the tarsal cartilages are ligamentous fibres which are attached to the malar bone. The inner extremities are attached to the nasal and lachrymal bones by the tendo oculi. The fibrous aponeurosis of the lids extends between the border of the tarsal cartilages beneath the orbicularis palpebrarum to the circumference of the orbit.

The Meibomian glands are situated between the conjunctivæ and the fibrous aponeurosis of the lids. They are about fifty in number in both lids, less in the lower than in the upper, and resemble miniature strings of beads. They are disposed parallel to each other and open on the free edge of the tarsal cartilage, which they groove. They are compound sebaceous glands.

The eyelashes or cilia are short, strong, curved hairs which form a fringe to each lid. They are arranged in a double or triple row and curve outward. The eyebrows are two curved elevations of the skin above each orbit and are covered with hair.

The conjunctiva lines the under surface of the eyelids and is reflected over the anterior part of the sclerotic and cornea. It is a mucous membrane, thick and vascular over the lids, loosely connected to the sclerotic; non-vascular and very thin on the cornea, but everywhere abundantly supplied with nerves. The plica semilunaris is a fold of the conjunctiva at the inner canthus, at the outside of the caruncula lacrymalis, which is the rounded, red elevation in the lacus lacrymalis.

The lachrymal gland is situated in a depression at upper, outer angle of the orbit. It is about the shape and size of the kernel of a small almond, and resembles the salivary glands in structure. It has about ten short ducts which open upon the upper, outer part of the conjunctiva. The lachrymal canals begin in the papilla lacrymalis at the puncta and lead into the canaliculi, which pass inward and terminate in the lachrymal sac. The lachrymal sac is situated anteriorly to the lachrymal ridge on the lachrymal bone. It is the upper dilated portion of the nasal duct. Anteriorly it is covered by the tensor tarsi muscle and an aponeurosis from the tendo oculi. The nasal duct is a fibro-membranous canal about one inch long, which opens into the inferior nasal meatus.

THE EAR.

The ear is the organ of hearing, and is divided into three parts,—the external, middle, and internal; the external ear presents the pinna, which is formed of yellow fibro-cartilage, folded so as to convey the vibrations of sound to the external auditory meatus. The following names have been applied to the different prominent folds: The helix is the prominent rim; in front of this is the antihelix, and between them is the fossa of the helix; the antihelix divides above, and incloses a slight depression,—the fossa of the antihelix; within the antihelix is a deep cavity,—the concha; the antihelix is notched below, and limited by an anterior nodule—the tragus—and a posterior nodule,—the antitragus. The inferior portion of the pinna is soft and thick and devoid of cartilage, and forms the lobule; it is held to the side of the head by an anterior and posterior ligament. The muscles of the pinna are extrinsic and intrinsic. The extrinsic have been described; they are

the attollens, attrahens, and retrahens aurem. The intrinsic muscles pass between the different parts of the pinna; they are named the helicus major and minor, the tragicus and antitragicus, the transverse and the oblique. The auditory canal, or meatus auditorius externus, is also a portion of the external ear; it extends from the concha to the membrana tympani, and presents an external cartilaginous and an internal osseous portion, and is, therefore, an osseo-cartilaginous canal, cylindroid in form. Its vertical diameter externally exceeds the transverse at the membrana tympani. The transverse diameter is the greatest; it is about one and a quarter inches long, and runs forward, inward, and curves slightly upward. Its inner extremity presents a groove for the attachment of the tympanic membrane. This groove is complete, except the superior portion, where it is notched. The skin lining this canal is thin and tightly adherent, and externally presents a number of sebaceous glands, which form the cerumen, or ear-wax.

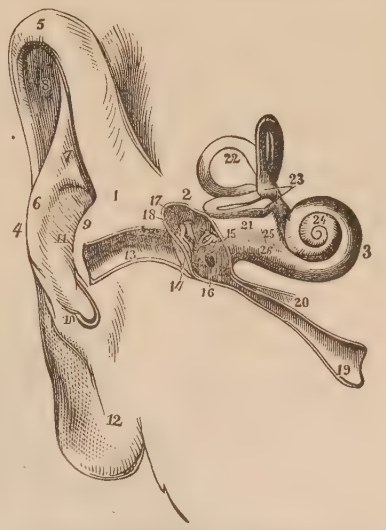

FIG. 182.—EXTERNAL, MIDDLE, AND INTERNAL EAR.

1, external ear; 2, middle ear; 3, internal ear; 4, pinna; 5, helix; 6, antihelix; 7, fossa navicularis; 8, fossa innominata; 9, tragus; 10, antitragus; 11, concha; 12, lobe; 13, meatus auditorius externus; 14, tympanic membrane; 15, promontory; 16, foramen rotundum; 17, posterior wall of the tympanum; 18, ossicula auditus; 19, Eustachian tube; 20, narrow canal, containing the tensor tympani muscle; 21, vestibule; 22, semicircular canals, the superior, posterior, and horizontal; 23, ampullæ; 24, cochlea; 25, prominence caused by the scala vestibuli; 26, scala tympani.

FIG. 183.—THE PINNA.

THE MIDDLE EAR.

The middle ear, or tympanum, is an irregular, cuboidal cavity, situated within the petrous portion of the temporal bone. It is separated from the auditory canal by the tympanic membrane. It is traversed by a chain of bones, which convey the vibrations of sound from the tympanic membrane to the internal ear, and is filled with air and communicates with the pharynx by the Eustachian

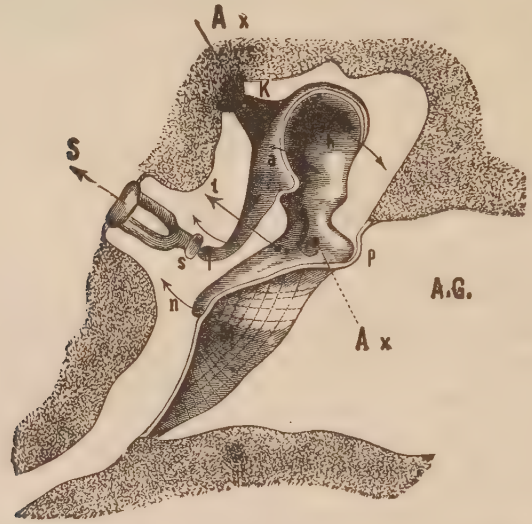

FIG. 184.—LEFT TYMPANUM AND AUDITORY OSSICLES.

A. G., external meatus; M, membrana tympani, which is attached to the handle of the malleus, n, and near it the short process, p; h, head of the malleus; a, incus; K, its short process, with its ligament; l, long process; s, Sylvian ossicle; S, stapes; A x, A x, the ax s of rotation of the ossicles, shown in perspective; t, line of traction of the tensor tympani. The other arrows show the movements of the ossicles when the tensor contracts.

tube. The cavity of the tympanum is about one-sixth inch in depth, one-fourth inch vertically, and three-eighths inch antero-posteriorly. It is irregularly cuboidal, and presents six walls for examination. The outer is formed by the membrana tympani, which is attached to a ring of bone. It presents three apertures,—the anterior and posterior, for the transmission of the chorda tympani nerve, and the Glaserian fissure. The posterior

aperture (iter chorda posterius) is about the centre of the angle between the outer and posterior walls of the tympanum; it leads into a canal, which terminates in the aquæductus Fallopii, and serves for the entrance of the chorda tympani into the tympanic cavity.

The anterior aperture (iter chorda anterius) opens above and in front of the ring of bone, for the attachment of the tympanic membrane; it leads into a fine canal (Huguier), which runs parallel with the Glaserian fissure; through it the chorda tympani leaves the tympanum.

The Glaserian fissure, continued from the glenoid fossa, opens just below the anterior aperture for the chorda tympani; it lodges the long process of the malleus, and transmits the laxator tympani muscle. The inner wall of the tympanum presents the oval window, the round window, the promontory, the pyramid, the opening for the stapedius, and the ridge formed by the aquæductus Fallopii. The oval window (fenestra ovalis) leads from the tympanum into the vestibule; it is closed by the lining membrane of the tympanum and vestibule, and has applied to it the base of the stapes. The round window (fenestra rotunda), a nearly circular opening below and behind the fenestra ovalis; it is placed at the bottom of a depression, and communicates with the cochlea; it is closed by Scarpa's membrane (membrana

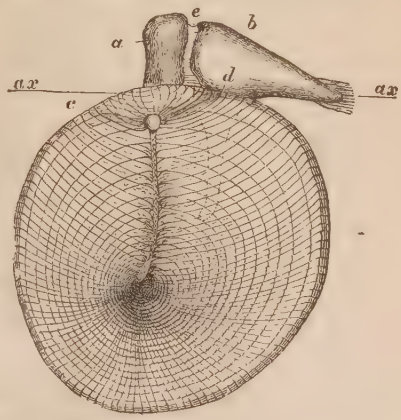

FIG. 185.—DIAGRAM OF THE EXTERNAL SURFACE OF THE LEFT TYMPANIC MEMBRANE.

a, head of the malleus; b, incus; e, joint between malleus and incus; between c and d is the flaccid portion of the membrane; ax, axis of rotation of ossicles. The deeply-shaded central portion is called the "umbo."

tympani secondaria). The promontory, in front of the fenestra rotunda, is a hollow, dome-like elevation, formed by the first turn of the cochlea; it presents two or three grooves, for the tympanic plexus.

The pyramid, cone-shaped, is placed behind the fenestra rotunda. It is hollow, and contains the stapedius muscle. At the apex of the pyramid is a minute orifice, which transmits the tendon of the stapedius. The aquæductus Fallopii skirts the upper and posterior portion of the inner wall. It contains the facial nerve. The posterior wall presents the openings of the mastoid cells. The anterior wall is separated from the carotid canal by a thin plate of bone. It presents the opening of the Eustachian tube, the processus cochleariformis, and the opening of the canal for the tensor tympani muscle.

The Eustachian tube is about one and one-half inches long, and is directed downward, forward, and inward. It is an osseo-cartilaginous canal; the osseous portion is about one-half inch in length; the cartilaginous portion, one to one and one-half inches long, opens trumpet-like into the pharynx. The processus cochleariformis is a thin plate of bone, which separates the Eustachian tube below from the canal above and transmits the tensor tympani muscle.

The membrana tympani is an oval, translucent membrane, which is placed obliquely at the bottom of the external auditory canal. It presents three layers,—external, or cuticular; middle, or fibrous; and internal, or mucous. The handle of the malleus descends between the fibrous and mucous layers to about the centre. Externally it is concave, but it changes its position slightly under the pressure of the air within the tympanum.

The ossicles of the tympanum are the malleus, incus, and stapes. They constitute a chain of bones, which transmit the vibrations of sound from the membrana tympani to the internal ear. The malleus presents a head, neck, and three processes. The head articulates with the incus. The handle is the vertical process attached to the membrana tympani. The processus gracilis gives attachment to the laxator tympani muscle. It passes outward nearly at right angles to the handle, and lies in the Glase-

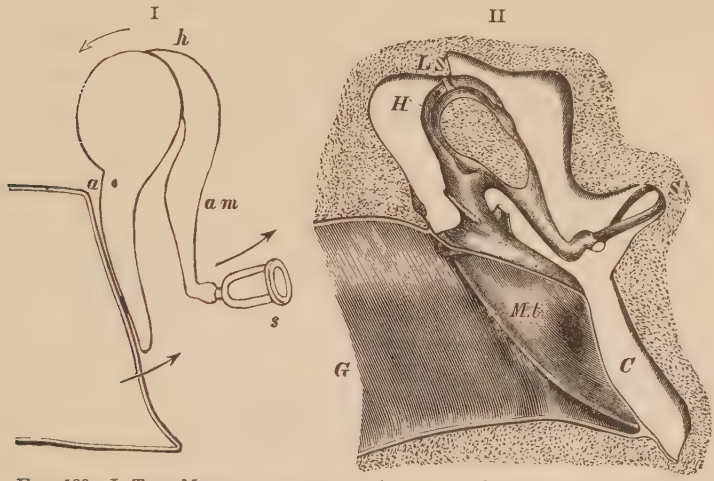

FIG. 186.—I. THE MECHANICS OF THE AUDITORY OSSICLES. II. SECTION OF THE MIDDLE EAR.

I. a, malleus; h, incus; am, long process of incus; s, stapes: the arrows show the direction of motion. II. G, external auditory canal; M. t., membrana tympani; C, tympanum; H, malleus; L S., superior ligament; S, stapes.

rian fissure. The short process is a tubercle on the root of the handle. It gives attachment to the tensor tympani.

The incus presents a body and two processes. The body articulates with the malleus. The processes are: the long and short, at right angles with one another. The short process is attached to the posterior wall; the long process, parallel with the handle of the malleus, terminates in the lenticular process, which articulates with the head of the stapes.

The stapes, or stirrup, presents a head, neck, two branches, and an oval-shaped base, which is applied to the fenestra ovalis. The ossicula are articulated and held together by capsular ligaments. The joints are covered by cartilage and lined by synovial membranes. They are also attached to the walls of the tympanum by delicate, ligamentous bands, and are moved by the three muscles:—

TENSOR TYMPANI.

Origin—Petrous portion of temporal bone.

Insertion—Runs backward in the canal above the processus cochleariformis and terminates in a tendon, which is inserted into the root of the handle of the malleus.

LAXATOR TYMPANI.

Origin—From the spine of the sphenoid.

Insertion—Runs backward through the Glaserian fissure, and is inserted on the neck of malleus above the processus gracilis.

STAPEDIUS.

Origin—From within the pyramid.

Insertion—Neck of stapes.

The mucous membrane is reflected over the different structures within the tympanum.

THE INTERNAL EAR.

The internal ear consists of the osseous and membranous labyrinth. The osseous labyrinth contains the vestibule, semicircular canals, and cochlea. The membranous labyrinth presents the utricle, saccule, and membranous cochlea and semicircular canals. The osseous labyrinth is developed in the substance of the petrous portion of the temporal bone.

The cochlea is in front; the vestibule is the central

communicating cavity between the cochlea and semicircular canals, and is in contact with the inner wall of the tympanum. It is ovoidal, and measures about one-fourth inch in its long diameter. It presents the oval window, to which the base of the stapes is applied. Opposite to this is the fovea hemisphærica, a depression which lodges the saccule. At the bottom of the fovea hemisphærica are a number of foramina, forming the macula cribrosa, which transmit filaments of the auditory nerve; also, on the inner wall, is an elevation,—the pyramidal eminence. The opening of the aquæductus vestibuli is at the lower posterior part. Above the fovea hemisphærica is the fovea semi-elliptica, which lodges the utricle. The three semicircular canals communicate with the posterior portion of the vestibule by five orifices. The cochlea opens in front by an elliptical opening into the scala vestibuli.

FIG. 187.—EXTERNAL APPEARANCE OF THE LABYRINTH AND FENESTRA OVALIS.

f, upper, h, horizontal, and s, posterior semicircular canals of the left side. The cochlea is seen to the left of the figure.

The three semicircular canals constitute each five-sixths of a circle; they are about one-twentieth inch in diameter, slightly compressed, so that the section is an ellipse, and at their origin each is dilated into an ampulla. They are named the superior, posterior, and external, and each canal is at right angles to the others. The superior and posterior open by a common canal; the external opens separately.

The cochlea is a conical structure about one-quarter inch at the base and one-quarter inch in height. The apex is directed forward and outward and slightly downward. It consists of a central, tapering, tubular axis,—the modiolus,—around which is wound a spiral canal for two and a half turns. The modiolus transmits branches

of the auditory nerve to the cochlea; it terminates in the apex of the cochlea (called the cupola) in a funnel-shaped dilatation, deficient at one side. The spiral canal of the cochlea is about one and a half inches long, decreases in size as it ascends, and terminates in the rounded apex,—the cupola. It is about one-tenth inch in diameter, and presents at its commencement: 1. the fenestra rotunda, which communicates with the tympanum. 2. The foramen ovale, which communicates with the vestibule. 3. The opening of the aquæductus cochlea.

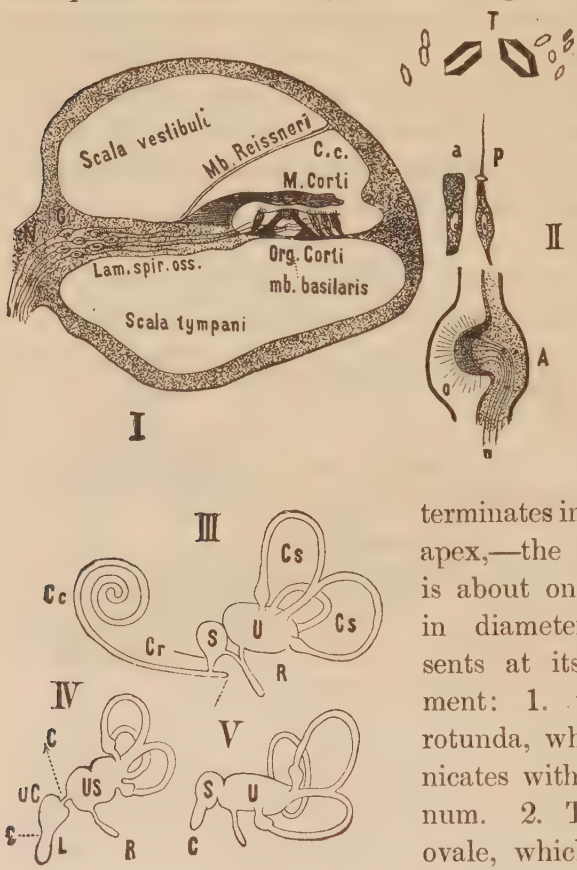

FIG. 188.—SCHEME OF THE LABYRINTH AND TERMINATION OF THE AUDITORY NERVE.

I. Transverse section of a turn of the cochlea. II. A, ampulla of a semicircular canal; a, p, auditory cells; p, provided with a fine hair; T, otoliths. III. Scheme of the human labyrinth. IV. Scheme of a bird's labyrinth. V. Scheme of a fish's labyrinth.

The spiral canal is divided by an osseo-membranous partition into an upper canal, the scala vestibuli, and a lower canal, the scala tympani. Along the circumference of the lower portion of the scala vestibuli is the scala

media. The lamina spiralis is the spiral bony plate which projects nearly at right angles from the modiolus, and which incompletely separates the scala. It consists of two lamellæ, between which pass the branches of the auditory nerve. Attached to the free edge of the osseous spiral plate is the membranous spiral lamina, which is attached to the inner surface of the cochlea; it completes the separation of scala vestibuli from the scala tympani.

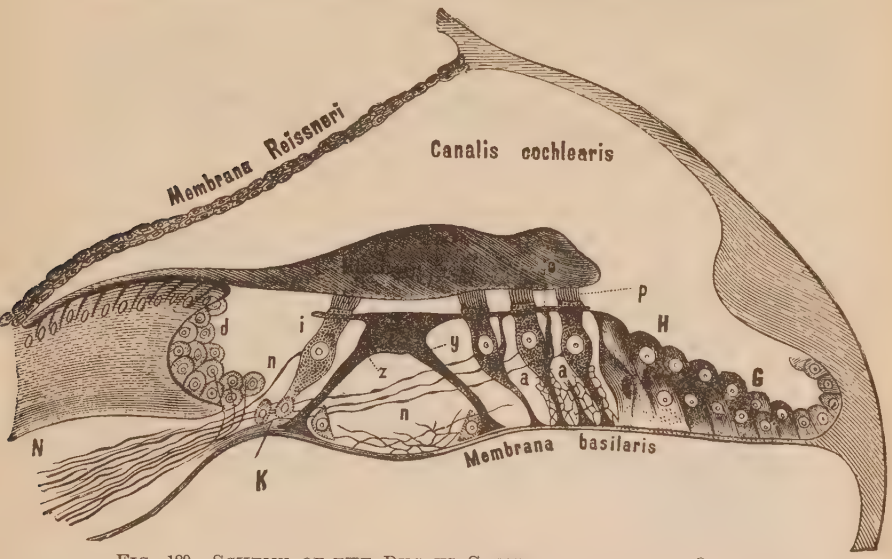

FIG. 189.—SCHEME OF THE DUCTUS COCHLEARIS AND THE ORGAN OF CORTI.

N, cochlear nerve; K, inner, and P, outer hair-cells; n, nerve-fibrils terminating in P; a, a, supporting cells; d, cells in the sulcus spiralis; z, inner rod of Corti; Mb. Corti, membrane of Corti, or the membrana tectoria; o, the membrana reticularis; H, G, cells filling up the space near the outer wall.

The membranous spiral lamina is formed of the following structures: The membrana basilaris; it is a delicate basement membrane stretched between the free edge of the bony lamina and the inner surface of the cochlea, where it becomes thickened and ligamentous, forming the ligamentum spirale. The investing endostium on the upper surface of the osseous lamina spiralis becomes thickened and forms the membrane of Todd. This divides into

two lips: an upper, the labium vestibulare, and a lower, the labium tympanicum; the groove between them is designated the sulcus spiralis. Attached between the labium vestibulare and the modiolus is the membrane of Reissner, which is attached to the inner wall of the cochlea, and subdivides the scala vestibuli into a lower, smaller canal, the scala media, and the larger, upper canal,

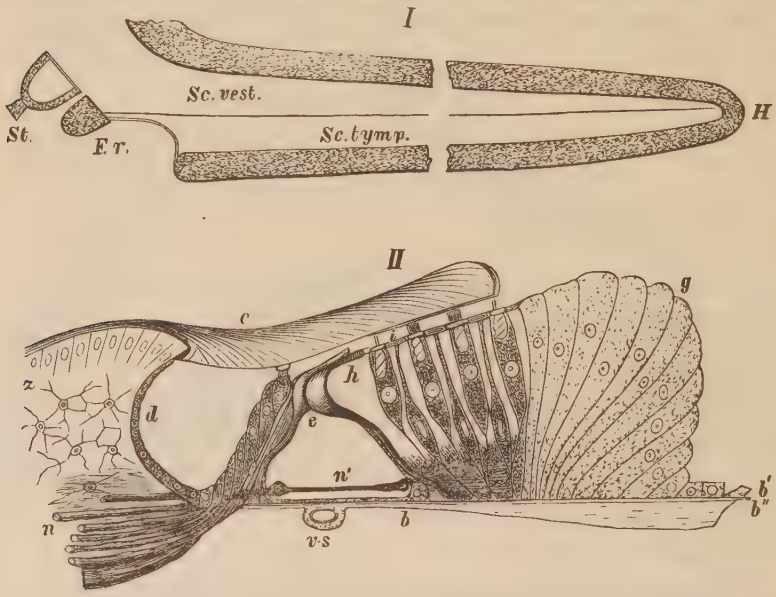

FIG. 190.—I. SECTION THROUGH THE UNCOILED COCHLEA. II. SECTION THROUGH THE TERMINAL NERVE-APPARATUS OF THE COCHLEA.

I. F.r., Fenestra rotunda: H, the helicotrema: St., the stapes. II. z, Huschke's process; b', basilar membrane; e, Corti's arch; g, supporting cells; h, cylindrical cells; i, Deiter's hair-cells; c, membrana tectoria; n, nerve-fibres; n', non-medullated nerve-fibres.

the scala vestibuli proper. Between the membrane of Reissner and the labium vestibulare arises the membrane of Corti, which passes outward parallel with the membrana basilaris, and is inserted on the inner wall of the cochlea, forming a canal called the ductus auditorium; it contains the organ of Corti. The organ of Corti consists of upward of three thousand arches, which spring from the labium tympanicum by the rods of Corti, and conjoin

the outer rods of Corti placed upon the membrana basilaris. The arch rises nearly to the under surface of the membrane of Corti. The rods of Corti are modified epithelial cells, some of which are ciliated. The scalæ vestibuli, media, and tympani communicate in the cupola by an opening called the helicotrema. The osseous labyrinth is lined by a delicate endosteum covered by epithelium, and which secretes a thin fluid, called the perilymph.

THE MEMBRANOUS LABYRINTH.

The membranous labyrinth is a very delicate serous sac contained within the osseous labyrinth. The membranous semicircular canals are about one-third of the diameter of the osseous canals, from which they are separated by the perilymph; they open into the utricle; the saccule is connected with the utricle by a delicate canal, and by means of the canalis reuniens communicates with the scala media of the cochlea. The membranous labyrinth is distended by a thin fluid,—the endolymph,—which it secretes. On the surface of the utricle and saccule are two small calcareous concretions,—the otoliths.

The auditory nerve enters the internal auditory meatus and divides into two branches,—cochlear and vestibular; the latter is distributed to the membranous semicircular canals, utricle, and saccule. The cochlear branch enters the modiolus, and is probably ultimately distributed to the ciliated cells of the organ of Corti.

THE ORGAN OF TASTE.

The tongue is a conoidal muscular organ, having an attached base and a free, movable point, or tip. It is contained within the buccal cavity, and while at rest its

sides and tips are in contact with the lingual surfaces of the upper teeth. It is covered by mucous membrane, in which are imbedded the organs of taste. The mucous membrane invests the dorsum, lateral surfaces, and tip, from which it is reflected to the floor of the mouth, forming its frænum. It is composed of two principal layers,—the cutis vera and epidermis. The cutis vera is a strong, fibrous, papillary structure intimately adherent to the muscular tissues of the tongue. The epiderm is epithelial in character. The papillæ of the tongue are

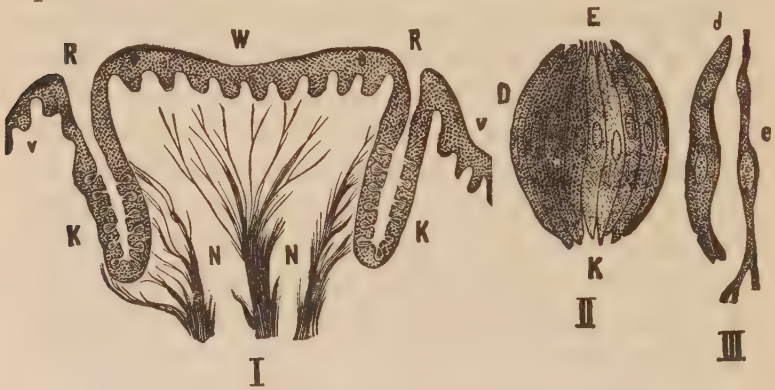

FIG. 191.—STRUCTURE OF THE GUSTATORY ORGANS.

I. Transverse section of a circumvallate papilla: W, the papilla; v, v, the wall in section; R, R, the circular split of fossa; K, K, the taste-bulbs in position; N, N, the nerves. II. Isolated taste-bulbs: D, supporting or protective cells; k, under end; E, free end open, with the projecting apices of the taste-cells. III. Isolated protective cells, d, with a taste-cell, e.

prominent and very abundant, and are divided into three classes,—the fungiform, the filiform, and the circumvallatæ. The fungiform are papillary elevations, about the size of a mustard-seed, scattered over the dorsum of the tongue. They are deep red in color, and are seen principally at the sides and tip. The filiform papillæ give to the mucous membrane its velvety appearance. They are very numerous, especially at the anterior two-thirds of the tongue. They are arranged in rows, which run outward and forward from the median line of the tongue, and

consist of minute conical papillæ, from which spring numerous filiform processes. The circumvallatæ papillæ are near the base of the tongue, and are about the size of a small pea. They vary from eight to ten in number, and are arranged like the letter **V**, with the point of the **V** at the base of the tongue. The papillæ consist of a fibrous structure, supporting capillaries, lymphatics, and nerves, and are invested with a basement membrane, covered by epithelial cells. In the circumvallate and fungiform papillæ are the "taste goblets," which consist of a nest of perpendicular, spindle-shaped, ciliated cells, into which the axis-cylinders of nerves can be traced. They are surrounded by large, flat, nucleated cells and spindle cells. The cilia project above the free surface of the epithelium. Imbedded in the mucous membrane are also a great number of mucous follicles and some lymphoid tissue. The epithelium is squamous. The chorda tympani nerve supplies the anterior two-third, the glossopharyngeal the posterior one-third of the mucous membrane of the tongue.

THE ORGAN OF SMELL.

The organ of smell is situated in the mucous membrane of the nasal cavities.

The nose is the projecting osseo-cartilaginous structure, triangular in outline, placed in the median line of the face. At its inferior portion are two oval apertures separated by a projection of the septum nasi. The nasal bones and nasal processes of the superior maxillæ form the osseous portion of the nose, which is completed by the two upper and two lower lateral and the triangular septal cartilages. Numerous small muscles act on the integument of the nose. They have been described.

The Schneiderean mucous membrane is closely adherent to the periosteum. It is continuous with the skin of the face at the anterior nares, and continuous with the mucous membrane of the pharynx at the posterior nares. It is also continuous with the mucous lining of the lachrymal duct, the frontal, sphenoidal, and maxillary sinuses. It is thick and vascular over the turbinated bones and septum nasi. Anteriorly the epithelium is squamous. In the inferior meatus it is ciliated; above it is columnar and imbedded in it are the olfactory cells, which consist of spindle-shaped, nucleated cells having an external hair-like process which projects slightly above the level of the mucous membrane. The other extremity is continuous with a filament of the olfactory nerve. Numerous mucous crypts are imbedded in the mucous membrane, and in the walls are seen spheroidal nucleated cells which appear to be intimately associated with the branches of the olfactory nerves.

THE SKIN.

The skin is the fibro-elastic investing structure of the body. It is the organ of touch and contains the sweat and sebaceous glands and hair-follicles, and serves for the protection of the deeper structures. It is thickest on the sole of the foot and palm of the hand and on the back, and thicker on the outer than the inner surface of the extremities. It is thinnest on the eyelids and penis. Its average thickness is about $\frac{1}{20}$ inch. It is divided into two layers,—the superficial and deep. The former is called the epiderm, the latter the cutis vera. Each of these is subdivided into two layers; the epiderm into a superficial called the stratum corneum, and a deep layer, the rete mucosum. The layers of the cutis vera are the

superficial or papillary and the deep or areolar layer. The epiderm is composed of cells. The deepest are columnar and present, in the colored races, numerous pigment cells; in the white races these are but few in number and scattered. Gradually, in passing toward the surface, the cells become flattened, lose their nuclei, become changed in their chemical properties, and are dis-

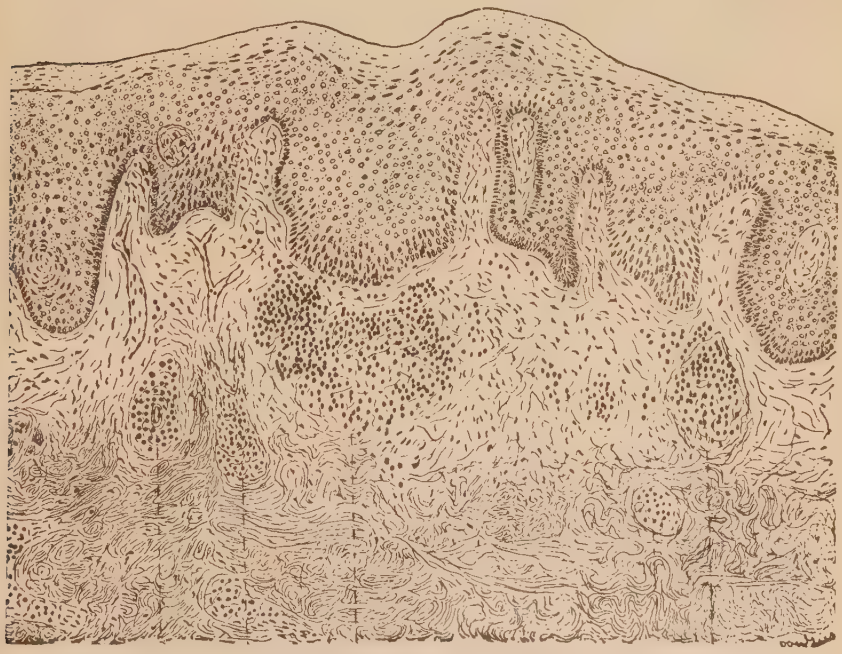

FIG. 192.—SECTION OF THE SKIN.

posed in strata of flat, scale-like cells, the outer layer of which is constantly exfoliated. The true skin is separated from the epiderm by a homogeneous basement membrane which invests the papillary layer. The papillary layer consists of papillæ, each about $\frac{1}{100}$ inch high, $\frac{1}{200}$ inch thick. They consist of a fibrous, skeletal structure, supporting capillary vessels and nerves, and, in certain localities, special nerve end-organs. The areolar layer is

below the papillary; it merges with the superficial fascia, to which it is attached by connective tissue. The areolar layer contains within its meshes fat-vesicles, sweat-glands, hair-follicles, and serves as a nidus for the ramification of vessels and nerves.

The hair and nails are appendages of the skin and consist of modifications of the epidermis. The sebaceous glands secrete the sebum, an oily substance which lubricates the skin. They consist of small, racemose glands, and frequently open in a hair-follicle.

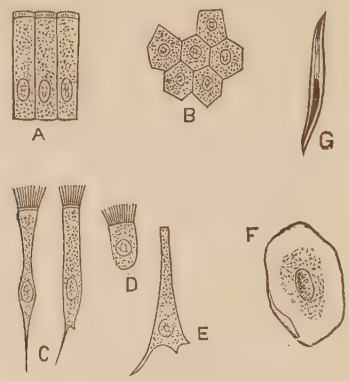

FIG. 193.—VARIOUS KINDS OF EPITHELIAL CELLS.
A, columnar cells of intestine: B, polyhedral cells of the conjunctiva; C, ciliated conical cells of the trachea; D, ciliated cell of frog's mouth; E, inverted conical cell of trachea; F, squamous cell of the cavity of the mouth, seen from its broad surface; G, squamous cell, seen edgeways.

The sweat-glands are tubular, excretory glands. They have a long duct leading from the gland, which lies in the subcutaneous connective tissue. The nerves terminate in the skin in three different ways: (1) the Pacchionian corpuscles, (2) the bulbs of Krause, and (3) the tactile corpuscles of Wagner.

1. The Pacchionian corpuscles are ovoidal masses of fibrous tissue, containing within a central canal a terminal axis-cylinder. They are about $\frac{1}{100}$ inch in diameter, and are found principally in the connective tissue of the fingers and toes. 2. The end bulbs of Krause are

minute capsules of connective tissue, about which are twined the axis-cylinders. They are found in the conjunctiva, glans penis and glans clitoris, and prepuce. 3. The tactile corpuscles of Wagner, or fir-cone bodies, are formed of connective tissue, about which the axis-cylinders form plexuses. They are found in the papillæ, and are the especial organs of touch.

REGIONAL ANATOMY.

THE NECK.

THE neck is the constricted, cylindrical segment extending between the head and trunk; it varies in form in the sexes, and at different ages; in the young adult male it is laterally compressed, and presents, in the median line anteriorly, the projectiug larynx; at the sides are the prominent, oblique, rounded elevations, which mark the sterno-mastoid muscles; posteriorly, the neck is flattened. In the young adult female the neck is nearly cylindrical, but slightly broader at its base. In infancy it presents numerous transverse or circular grooves and folds, due to the accumulation of fat in the subcutaneous structures. At old age the skin is wrinkled and presents two prominent folds, which pass from the sides of the chin downward and backward; they correspond to the anterior edges of the platysma muscles. Up to an advanced period the skin of the neck is loosely attached to the subcutaneous structures; in operations in this region it is necessary to fix or steady it by pressure or traction, to preserve the relations of the incisions to the deeper structures.

The superficial fascia is separable into two layers, between which pass the fibres of the platysma myoides muscle, which arises over the clavicle and passes obliquely upward, to be inserted on the fascia of the lower part of the face. Some of its fibres blend with the fibres of the orbicularis oris. The deep leaflet of the superficial fascia is very thin and membranous. The deep fascia—a thin, fibrous, investing structure—is exceedingly complex in

its ramifications; it is thick over the trachea and great vessels, for which it forms sheaths; it is attached posteriorly to the superior curved line of the occipital bone, to the ligamentum nuchæ, and the spine of the scapula; also, to the spines and transverse processes of the cervical vertebræ; it passes forward to the posterior border of the sterno-mastoid muscle, where it splits into two leaflets, to invest the muscle. The superficial layer becomes continuous with the superficial layer of the opposite side; the deep layer joins the superficial layer anterior to the sterno-mastoid; it then dips down and surrounds the internal jugular vein, common carotid artery, and pneumogastric nerve, forming their sheath; it is then reflected over the pharynx, making its fibrous coat. It forms, by its reflexions and reduplications, sheaths for the vessels, nerves, and muscles, and is attached to all the prominent osseous structures; its attachment to the first rib forms the pulley for the play of the tendon of the omo-hyoid muscle. Between the superficial and deep fasciæ are numerous superficial veins and nerves. Of these, the most important is the external jugular vein, which arises near the angle of the jaw and empties into the subclavian vein, just above the middle of the clavicle. The anterior jugular vein is inconstant; it is usually found near the anterior median line of the neck, and opens generally into the subclavian. A number of the superficial branches of the cervical plexus are seen running upward, transversely, and downward. Of these the great auricular, derived from the second cervical, emerges behind the sterno-mastoid, and is distributed to the facial and auricular regions. The small occipital, from the second or third cervical, runs along the posterior border of the sterno-mastoid, and is distributed to the occipital region. The descending nerves are dis-

tributed to the shoulder, clavicular, and sternal regions. A number of lymphatic glands are found within and beneath the superficial fascia. When the deep cervical fascia is opened, the sterno-mastoid muscle is brought prominently into view; it arises from the mastoid portion of the temporal and the adjoining occipital bone, passes obliquely downward and forward, and is inserted

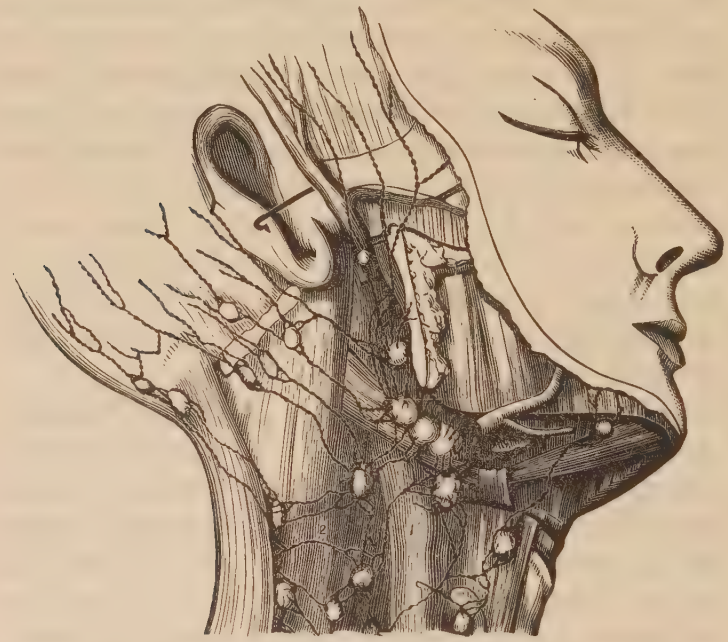

FIG. 194.—LYMPHATICS OF HEAD AND NECK.
1, internal jugular vein; 2, deep cervical glands.

by a tendon into the sternum, and, by a broad, muscular insertion, upon the clavicle. This muscle divides the side of the neck into two great triangles,—the anterior and posterior. The anterior great triangle is bounded above by the lower border of the inferior maxillary and a line drawn from its angle to the mastoid process; in front, by the median line; behind, by the anterior border

of the sterno-mastoid. The posterior great triangle is bounded in front by the posterior edge of the sterno-mastoid; behind, by the anterior border of the trapezius; and below, by the clavicle. The anterior great triangle is subdivided into three lesser triangles,—the submaxillary, the carotid, and the inferior. The submaxillary triangle is bounded above by the lower jaw; below and in front, by the anterior belly of the digastric; and behind, by the posterior belly, with some of the fibres of the stylo-hyoid muscle. The digastric muscle arises anteriorly below the genial tubercles, and passes downward to the hyoid bone. Its mesial tendon pierces the tendon of the stylo-hyoid, and the posterior, fleshy belly is inserted in the digastric fossa of the mastoid portion of the temporal bone. This triangle is covered by a double leaflet of deep cervical fascia; in the interval between them some lymphatic glands are frequently observed.

Beneath the deep fascia and within the triangle is the submaxillary gland, usually pierced by the facial artery. Some veins, lymphatics, and adipose tissue are also exposed. The floor of this triangle is formed by the mylo-hyoid and hyoglossus muscles, the latter being crossed by the hypoglossal nerve in its transit to the tongue. The carotid triangle is bounded above by the posterior belly of the digastric, below by the anterior belly of the omo-hyoid, and behind by the edge of the sterno-mastoid. The omo-hyoid muscle arises from the inferior surface of the body of the hyoid bone, passes downward beneath the sterno-mastoid, and becomes tendinous. Its tendon passes through a loop of the deep cervical fascia, and the posterior fleshy belly is inserted on the transverse ligament and upper border of the scapula. The floor of the carotid triangle is formed by the thyro-

hyoid, hyoglossus, the inferior and middle constrictors of the pharynx, the greater cornu of the hyoid bone, and the pharyngeal aponeurosis. The middle of the carotid triangle is on a level with the upper border of the thyroid cartilage. It contains the bifurcation of the common carotid artery, the external and internal carotid, the

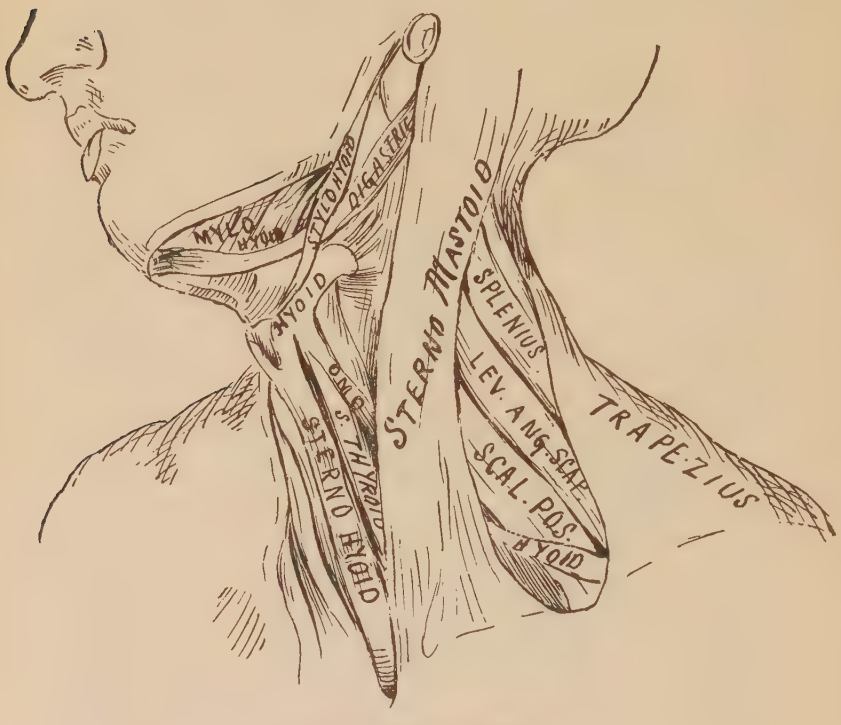

FIG. 195.—MUSCLES OF NECK.

jugular vein, and the pneumogastric nerve, inclosed within a sheath, upon which descend the descendens and communicans noni nerves, communicating and forming a loop beneath the omo-hyoid muscle. On either side of the median line of the neck are two flat, ribbon-like muscles,—the sterno-hyoid and the sterno-thyroid. Beneath them is the thyroid gland, which rests like a saddle

across the upper part of the trachea. Its lobes encroach upon the inferior triangles, which are bounded on each side above by the omo-hyoid, posteriorly by the sterno-mastoid, and anteriorly by the median line. Its floor is formed by the scalenus anticus and the longus colli muscles. It contains, beneath the cover of the sterno-mastoid, the common carotid artery, internal jugular vein, the pneumogastric and phrenic nerves, the trachea, and thyroid gland. The posterior triangles are: the superior, or suboccipital, and the inferior, or subclavian. The superior triangle is bounded in front by the posterior border of the sterno-mastoid, below by the posterior belly of the omo-hyoid, and posteriorly by the trapezius. Its floor is formed by the scalenus anticus, scalenus posticus, levator anguli scapulæ, and the splenius muscles. It is crossed by the spinal accessory nerve, the transversalis colli artery and vein, and contains branches of the cervical plexus, lymphatics, and adipose tissue. The subclavian triangle is bounded below by the clavicle, anteriorly and above by the sterno-mastoid, posteriorly and above by the posterior belly of the omo-hyoid. Its floor is formed by the scalenus medius, scalenus anticus, and scalenus posticus, the first rib, and some of the fibres of the serratus magnus. It contains the third part of the subclavian artery, which curves downward beneath the middle of the clavicle into the axilla. The subclavian vein is in front of the artery, but at a lower level. The brachial plexus lies on the scalenus medius muscle, above the subclavian artery. A quantity of fat and some lymphatics are also found in this triangle.

When the sterno-mastoid muscle is removed the deeper structures of the neck are exposed. The most important are: the carotid artery, internal jugular vein, subclavian artery and vein; the pneumogastric, phrenic,

hypoglossal, and spinal accessory nerves; the thoracic duct on the left side, and on the right side the right lymphatic duct. The common carotid artery on the right side is a branch of the innominate; on the left side it comes from the arch of the aorta. It passes obliquely up the neck in a line from the sterno-clavicular articulation to the angle of the jaw, and at the upper border of the thyroid cartilage it divides into the external and internal carotids. The external carotid in the neck sends off the superior thyroid, lingual, and facial to the structures anterior to the vessel; passing backward are the occipital and posterior auricular. The ascending pharyngeal is deeply placed behind the external carotid; it is given off just above the bifurcation. External to the carotid artery is the internal jugular vein, a capacious but delicate venous trunk. It begins at the jugular foramen, at the base of the skull, and receives the blood from the sinuses and superficial and deep parts of the head and neck. It lies in the same sheath with the carotid artery, from which it is separated by a cellular interval. The descendens noni from the hypoglossal forms a loop upon the sheath with the communicans noni, derived from the second or third cervical.

The subclavian artery is divided into three portions by the scalenus anticus muscle,—from the first part, between the muscle and the origin of the vessel, are given off the thyroid axis, the vertebral, and internal mammary; from the second part, behind the scalenus anticus, comes off the superior intercostal; the third portion gives off no branches. The subclavian artery arises about an inch above the clavicle; it rests on the cervical pleura, scalenus medius muscle, and the first rib. The subclavian vein is in front of the artery, but on a lower level; it receives the external jugular and the transverse cervical veins.

The phrenic and pneumogastric nerves pass between the subclavian artery and vein, the pneumogastric lying nearer the median line. The pneumogastric nerve in the neck presents, just after it emerges from the jugular foramen, a gangliaform enlargement, which sends off numerous filaments of communication. It runs down the neck within the sheath of the carotid artery and internal jugular vein, between but behind these vessels. It sends off a motor branch to the pharynx, the superior laryngeal, a sensory nerve to the larynx and the recurrent laryngeal, which is given off on the right side as the nerve passes over the subclavian artery; it then winds beneath and behind this trunk, runs upward to the larynx, to which it is the motor nerve. On the left side the recurrent laryngeal is given off below the arch of the aorta; it then runs behind this vessel along the trachea to the larynx.

The phrenic nerve is derived from the third and fourth cervical; it crosses the scalenus anticus, passes into the chest between the subclavian artery and vein. It is external to the pneumogastric.

The hypoglossal passes down under cover of the ramus of the inferior maxillary; it enters the submaxillary triangle, crosses the great vessels, and curves forward to the tongue; it sends off the descendens noni. The spinal accessory nerve pierces the upper portion of the sterno-mastoid, crosses the posterior superior triangle, and is distributed to the trapezius.

THE AXILLA.

The axilla is a pyramidal space which is bounded in front by the pectoral muscles; behind, by the latissimus dorsi, teres major, and subscapularis. Externally it is

limited by the humerus; internally, by the upper four or five ribs covered by the serrate muscle; the apex is above, and corresponds to the entrance of the axillary vessels and the brachial plexus of nerves. When the arm is placed at right angles to the trunk, the axilla, limited by the prominent lower anterior and posterior borders, is seen to be a marked concavity, narrower externally than internally. The skin is rather closely adherent, covered by a growth of short hair. Numerous sebaceous follicles, secreting an unctious, highly-odorous fluid, and sweat-follicles, are imbedded in the skin in this region. When the skin is removed the superficial fascia is seen. It is loaded with fat, as a rule, and presents some superficial veins, nerves, and lymphatics. The deep fascia is aponeurotic, and incloses the deeper structures. An incision should be made through the pectoralis major and minor, through the layer of cellular fascia beneath the pectoralis minor, and these structures turned aside. There will now be exposed the axillary vein and artery and their branches, the brachial plexus and its branches, and a cluster of lymphatic glands imbedded in a quantity of loose fat. The axillary vein lies in front of the artery; it is the continuation of the basilic vein, and receives the vena comites, numerous small branches, and the cephalic. The axillary artery is the continuation of the subclavian; it lies behind and to the outer side of the vein; they are invested with a quantity of loose cellular tissue. The larger branches of the axillary artery are the long thoracic, which is often concealed behind the lower border of the pectoralis major; the subscapular, which runs down the anterior surface of the subscapular muscle; the circumflex, external and internal, distributed to the neck of the humerus. The

axillary artery and vein bisect the axilla and run close to the outer wall, against the humerus.

The brachial plexus surrounds the axillary artery, lying on a plane posterior to it. The branches from the outer and inner cords unite in front of the artery to form

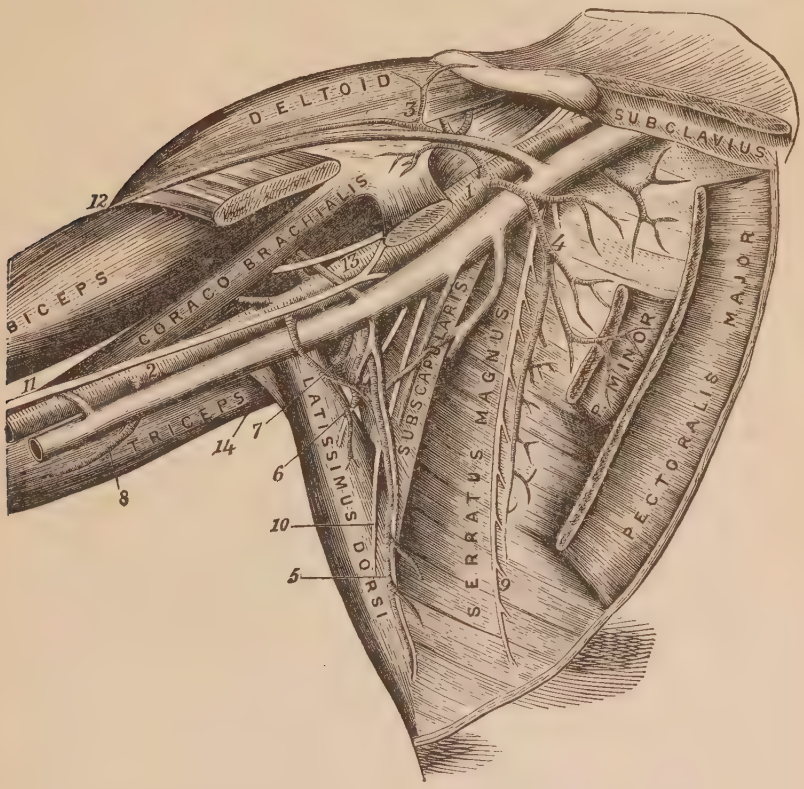

FIG. 196.—DISSECTION OF AXILLA.

1, axillary artery; 2, brachial artery; 3, acromio-thoracic artery; 4, superior thoracic artery; 5, subscapular artery; 6, dorsalis scapulæ artery; 7, posterior circumflex artery; 8, superior profunda artery; 9, posterior thoracic nerve; 10, long subscapular nerve; 11, median nerve; 12, cephalic vein; 13, musculo-cutaneous nerve; 14, teres major muscle.

the median nerve, which passes down in front of the vessels. To expose more fully the branches of the plexus it is necessary to remove the axillary vein. The axillary space is crossed by some lateral cutaneous branches of

the intercostal nerves. One of these, from the second intercostal, communicates with the lesser internal cutaneous. It is called the intercosto-humeral nerve, and is ultimately distributed to the integument near the elbow. The lymphatic glands of the axilla communicate with the cervical. They are of from ten to fifty in number and of variable size.

THE PERINEUM.

The male perineum is the diamond-shaped space limited in front by the scrotum, behind by the tip of the coccyx, laterally by the tuberosities of the ischia, the rami of the ischia and pubes, and the greater and lesser sacro-sciatic ligaments. A line drawn transversely through the tuberosities of the ischia subdivides this region into an anterior, the perineum proper, and a posterior, the ischio-rectal region. The skin of the perineum is pigmented, tightly adherent, thrown into numerous fine, transverse rugæ, and presents a median raphe, continuous with the raphe of the scrotum. It is covered by scattered, short, stiff hairs. Over the ischio-rectal region the skin is less firmly attached to the subcutaneous structures; the pigmentation is strongly marked about the anus, which is situated in the median line midway between the perineum and the coccyx. It presents numerous folds radiating from the anal aperture. Upon removing the skin of the perineum the superficial fascia is exposed. This fascia consists of two layers,—superficial and deep. The superficial layer is continuous with the outer layer of the superficial fascia of the abdomen, thighs, and ischio-rectal region, and is loaded with fat. The deep layer of the superficial fascia is continuous with the deep layer of the superficial fascia of the abdomen. In the perineum it is much thickened and firmly attached

to the ascending rami of the ischia and pubes and invests the deeper perineal structures. It passes backward to the posterior border of the transversus perinei, around which it is reflected. It then becomes very much thickened and fibrous, and passes forward, being firmly at-

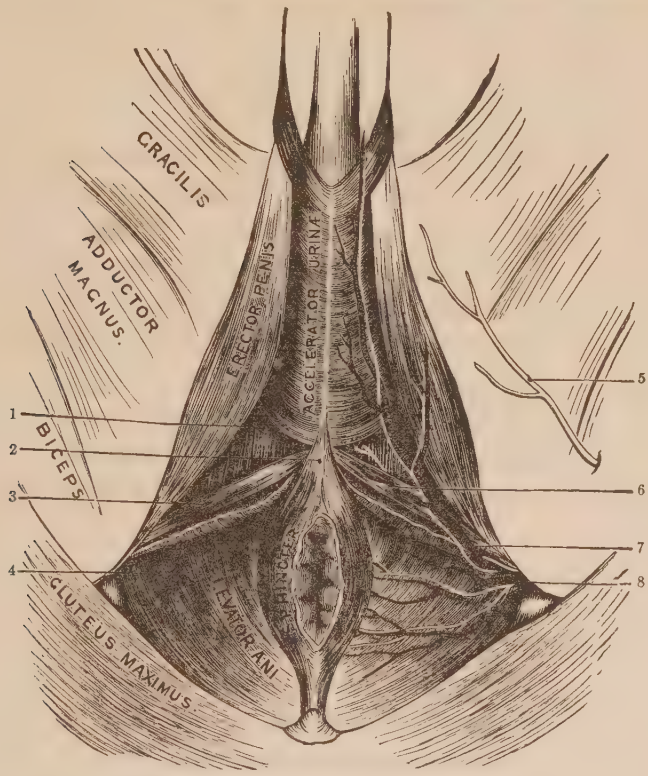

FIG. 197.—MUSCLES OF THE PERINEUM, WITH SUPERFICIAL VESSELS AND NERVES.

1, triangular ligament; 2, tendinous centre of the perineum; 3, transversus perinei; 4, ischio-rectal fossa; 5, inferior pudendal nerve; 6, transversalis perinei artery; 7, superficialis perinei artery; 8, external hæmorrhoid artery and nerve.

tached to the ascending rami of the ischia, descending rami of the pubes, and the subpubic ligament. It is pierced by the urethra and the dorsal vein of the penis, and is commonly called the triangular ligament. It is also known as the superficial layer of the deep perineal fascia.

The deep layer of the deep perineal fascia is a delicate membranous structure, which is derived from the deep layer of the superficial fascia as it curves around the posterior border of the transversus perinei muscles. It passes to the anterior and upper surface of the prostate gland. The perineal fasciæ are very simple in their arrangement. They inclose the important structures of the perineum. When the deep layer of the superficial fascia is removed the following structures are brought into view: The transversus perinei, erector penis, and accelerator urinæ muscles; the transverse and superficial perineal arteries and nerves, the corpus spongiosum and bulb, and the corpora cavernosa. The transversus perinei arise from the inner surfaces of the tuberosities of the ischia and pass transversely inward, and are inserted on the central tendon of the perineum. They are each about as thick as a lead-pencil. The erector penis on each side arises from the inner surface of the tuberosity of the ischium and is broadly inserted upon the corpus cavernosum.

The accelerator urinæ is a bipenniform muscle; it surrounds the corpus spongiosum and bulb, and may be said to arise from the central tendon; it is inserted at the sides of the crus penis. In the triangular interval between the accelerator urinæ and erector penis the superficial perineal artery and nerve are seen. The floor of this triangle is the superficial layer of the deep perineal fascia (the triangular ligament). When the accelerator urinæ is removed, the corpus spongiosum and bulb of the urethra are brought into view; they are in the median line, and inclose the urethra. When the superficial layer of the deep perineal fascia (triangular ligament) is removed, the following structures are brought into view: Artery of the bulb, Cowper's gland, internal pudic artery,

and membranous urethra. The artery of the bulb is a short branch of the internal pudic; it is distributed to the bulb. The internal pudic artery runs along the ascending ramus of the ischium, and gives off the artery to the corpus cavernosum. Cowper's gland is a small, yellow, lobular mass, about the size of a pea; its duct opens into the bulb of the urethra. The membranous urethra is that portion of the canal between the superficial and deep layers of the deep perineal fasciæ; removal of the deep layer of the deep perineal fascia exhibits the prostate and lower portion of the bladder.

The ischio-rectal region comprises that portion of the perineum behind the transversus perinei muscles; it presents at the centre the anal opening, surrounded by a superficial stratum of muscular fibres,—the external sphincter. On either side of the rectum is a conoidal space filled with fat; traversing the space are the superficial hæmorrhoidal vessels and nerves. When the fat is removed it brings into view the levator ani muscle, which supports the pelvic organs.

In the female the perineum consists of some of the external genitalia (already described, page 403) and the following modifications: The urethra, which opens between the labia minora, at the bottom of the vestibule, is a short canal three-fourths of an inch long; in fact, simply a membranous urethra imbedded in the anterior wall of the vagina. The opening of the vagina is guarded in the virgin state by the hymen, which is, in fact, a thin, incomplete prolongation of the superficial layer of the deep perineal fascia, lined by mucous membrane. The orifice of the vagina is surrounded by a superficial, flat, sphincter muscle, continuous with the superficial sphincter of the rectum. The perineum proper is that wedge-shaped mass of tissue between the vagina and

rectum; the base is below; it is formed of the transversus perinei, sphincters of the vagina and rectum where they are attached to the central tendon, and a mass of fibro-muscular tissue of variable height and thickness. Numerous arteries and veins, branches of the pudic and hæmorrhoidal, supply the perineum; it is also freely supplied with nerves communicating with the uterine and pelvic plexuses of the sympathetic.

SCARPA'S TRIANGLE.

Scarpa's triangle is situated at the upper anterior portion of the thigh; it is bounded above by Poupart's ligament, externally by the sartorius muscle, internally by the adductor longus. Its floor is formed from within outward by the pectineus, psoas magnus, and iliacus. The femoral vein, artery, and crural nerve pass from the middle of Poupart's ligament to the apex of the triangle; the vein is to the inner side, the artery in the middle, and the nerve externally. The artery and vein are inclosed in a sheath; the nerve is to the outer side. Near the anterior superior spine of the ilium emerges the external cutaneous nerve, and passes to the skin along the outer side of the thigh. Just after its exit from beneath Poupart's ligament, the anterior crural nerve breaks up into superficial cutaneous and deep muscular branches. One of the latter—the long saphenous—passes down the thigh with the femoral artery. About two inches below Poupart's ligament the femoral artery gives off the profunda, which supplies the muscles of the thigh. The femoral continues down the thigh and becomes the popliteal. The femoral vein receives numerous venous radicles; the most important branch is the long saphenous, which drains the superficial structures from the ankle to the groin.

FEMORAL HERNIA.

Femoral hernia is the protrusion of some of the abdominal viscera through the femoral ring. The superficial fascia over Scarpa's triangle consists of two layers: the superficial layer is thick and loaded with fat; beneath it are some of the superficial arteries, veins, nerves, and lymphatics. The long saphenous vein is the most important structure; it passes through the saphenous opening of the fascia lata, and opens into the femoral vein. That portion of the deep layer of the superficial fascia, attached to the margins of the saphenous opening, is called the cribriform fascia; it is perforated for the passage of numerous veins and small arteries. Clustered about the long saphenous vein are a number of lymphatic glands arranged in a double chain; the upper set communicate with the lymphatics of the external genitalia, the lower with the lymphatics of the thigh and leg. The deep fascia, or fascia lata, is aponeurotic, and presents at the upper part of Scarpa's triangle the saphenous opening; to its margins the cribriform fascia is attached and must be removed before the aperture can be plainly seen. It is oval in outline, about one inch in its longest diameter, and presents a well-marked, sharply-defined, outer border, known as the falciform process or Hey's ligament. It passes over the femoral vessels, and is attached to Poupart's ligament and continued through Gimbernat's ligament to the pubes. Inferiorly it forms a sharply-defined loop; the inner border is less defined than the outer; it passes beneath the femoral vessels and becomes continuous with the femoral sheath. The sheath for the femoral vessels is formed in front by a continuation of the transverse fascia beneath Poupart's ligament; the iliac fascia completes it behind. The femoral vein and artery enter the sheath and pass down

the thigh. To the inner side of the vein there exists an interval called the femoral ring, but filled with cellular tissue. Of all the parts below the femoral arch (formed by Poupart's ligament) this space is the point of least resistance; hence, in femoral hernia the protrusion engages almost uniformly at this point at the inner side of the vein. The coverings for femoral hernia, it will be seen, are, from within outward, the peritoneal sac, the cellular tissue (septum crurale) to the inner side of the vein, the sheath of the vessels, the cribriform fascia, superficial fascia, and skin.

INGUINAL HERNIA.

Inguinal hernia may be indirect or direct. The skin at the lower part of the abdomen is thin and loosely attached to the subcutaneous tissues, in which ramify the superficial arteries, veins, and lymphatics. The deep fascia is very thin, and is adherent to the linea alba. Beneath the deep fascia is the aponeurotic tendon of the external oblique muscle; its lower border is much thickened and cord-like; it is attached to the anterior superior spine of the ilium and the spine of the pubes, and is called Poupart's ligament. The direction of the fibres of the tendon of the external oblique is downward and inward, and that portion inserted upon the pubes is split, forming a long triangular separation of the fibres of the tendon, called the external inguinal ring. The base of this opening is at the pubes; the inner edge is called the inner column; the outer is called the outer column. Between the two columns the deep fascia is slightly thickened and attached to the margins of the ring, forming the intercolumnar fascia. When this is removed, the finger can be placed directly against the conjoined

tendon of the transversalis and internal oblique; this tendon fortifies the external ring. When the external oblique is removed the internal oblique, separated by fine connective tissue, is brought into view. From its lower border a number of loops of muscular fibres—the cre-

FIG. 198.—DISSECTION FOR INGUINAL HERNIA.

A, external oblique; B B, internal oblique; C, transversalis; D, conjoined tendon; E, rectus abdominis with sheath opened; F, fascia transversalis; H, cremaster; I, infundibular fascia.

master muscle—descend upon the spermatic cord, and between the loops a delicate connective tissue (cremaster fascia) holds them in their relative positions. Beneath the internal oblique is the transversalis; its tendon unites with the internal oblique and forms the conjoined tendon, which is broadly inserted upon the pubes behind the

external inguinal ring. Beneath the transversalis is the transversalis fascia, which presents, about midway between the anterior superior spine of the ilium and the spine of the pubes, the internal inguinal ring,—a round aperture which will admit the point of the little finger. It leads into a funnel-shaped prolongation over the spermatic cord (in the female, the round ligament). This funnel-shaped continuation is known as the infundibuliform process of the transverse fascia.

The inguinal canal is about two inches long. It begins at the internal inguinal ring and terminates at the external inguinal ring. It transmits the spermatic cord in the male, and the round ligament in the female. The testicle in fœtal life is lodged within the abdominal cavity, out of which it is drawn by the contraction of a fibro-muscular cord, the gubernaculum, which is attached to the bottom of the scrotal sac. In its descent the testicle pushes before it a fold of peritoneum, which ultimately becomes the tunica vaginalis. As it passes through the opening in the transverse fascia it carries with it a process, the infundibuliform, which surrounds the testes and cord, and the testicle in its further descent carries along some of the fibres of the internal oblique, forming the loops of the cremaster muscle. Generally at birth the testicle is within the scrotum, and the communication between the tunica vaginalis and the peritoneal cavity is closed. The descent of indirect inguinal hernia follows the course of the descent of the testicle; hence, the coverings for oblique hernia are as follow: Peritoneal sac, infundibuliform process of transverse fascia, cremaster muscle and fascia, intercolumnar fascia, superficial fascia, and skin.

In direct inguinal hernia the gut does not enter the internal inguinal ring; it forces the structures of the

abdominal wall directly through the external inguinal ring, and the coverings for direct inguinal hernia, from without inward, are: Skin, superficial fascia, intercolumnar fascia, conjoined tendon, some other soft structures, such as the fibres of the rectus abdominis, transverse fasciæ, and the peritoneal sac.

INDEX.

ABDOMEN, 367
apertures found in, 367
boundaries of, 367
muscles of, 201
regions of, 368
viscera of, 368
Acetabulum, 130
Acromion, 107
Air-cells, 349
-sacs of lung, 349
Alæ of nose, 435
of vomer, 52
Alimentary canal, 350
Alveoli, sockets of, 57
of lower jaw, 56
of stomach, 373
of upper jaw, 44
Amphiarthrosis, 152
Ampullæ of semicircular canals, 429
of tubuli lactiferi, 411
Anastomosis of arteries, 232
Ankle-joint, 168
Annulus ovalis, 338
Antihelix, 422
fossa of, 422
Antitragus, 422
Antrum of Highmore, 41
Anus, 378
muscles of, 231
Aorta, 234
abdominal, 247
branches of, 247
arch of, 235
ascending part of, 235
branches of, 235
descending part of, 235
of branches of, 235
transverse portion of, 235
descending, 235
sinuses of, 235
thoracic, 247
branches of, 247
Aponeurosis of deltoid, 206
of external oblique, in inguinal region, 204
of occipito-frontalis, 176
pharyngeal, 189
Apophysis, 10
Appendages of eye, 420
of skin, 438
of uterus, 409
Appendix, ensiform, 99
of left auricle, 339
of right auricle, 338
vermiformis, 376
Aqua labyrinthi, 433
Aquæductus cochleæ, 25
Fallopii, 25
Sylvii, 296
vestibuli, 25
Aqueous chamber, epithelial lining of, 413
humor, 418
Arachnoid membrane of brain, 277
of cord, 303
Arantii corpora, 339, 341
Arbor vitæ of cerebellum, 303
uterinus, 408
Arch, palmar, deep, 242
superficial, 243
plantar, 254
Arm, arteries of, 239
bones of, 111
muscles of, 205
nerves of, 321
veins of, 260
Arteriæ receptaculi, 246
Artery or Arteries, 232
anastomoses of, 232
capillary, 233
distribution of, 233
general anatomy of, 232
systemic, 234
acromial thoracic, 230
alar thoracic, 240
alveolar, 243
anastomotica magna of brachial, 241
of femoral, 253
angular, 243
aorta, 234
articular, of knee, 253
ascending cervical, 238
pharyngeal, 245
posterior, 244
axillary, 239
branches of, 239
azygos articular, of knee, 253
basilar, 238
brachial, 241
branches of, 241
bronchial, 247
of bulb of urethra, 251

Artery or Arteries calcanean, internal, 254
carotid, 243
common, 243
external, 243
internal, 245
carpal of radial, 241
of ulnar, 242
posterior, of radial, 241
of ulnar, 242
of cavernous body, 250
centralis retinæ, 246
cerebellar, 238
cerebral, 246
cervical, ascending, 238
superficial, 238
cervicis princeps, 244
profunda, 239
choroid, anterior, 246
ciliary, 246
anterior, 246
long, 246
short, 246
circle of Willis, 238
circumflex of arm, 241
anterior, 241
posterior, 241
iliac, 252
superficial, 252
of thigh, 252
external, 252
internal, 252
cœliac axis, 247
colica dextra, 248
media, 247
sinistra, 249
comes nervi ischiadici, 251
phrenici, 239
communicating, anterior, of brain, 246
posterior, of brain, 246
of ulnar, 242
coronary, of heart, 235
inferior, 235
left, 235
of upper lip, 243
of lower lip, 243
of corpus cavernosum, 251
crico-thyroid, 243
cystic, 247
cervical, 244
palmar arch, 243
temporal, 244
dental, inferior, 245
descending palatine, 245
digital, of plantar, 243
of ulnar, 243
dorsal, of lumbar, 249
of penis, 251
dorsalis pollicis, 242
Artery or Arteries, dorsalis indicis, 242
linguæ, 243
pedis, 254
branches of, 254
peculiarities of, 254
penis, 251
pollicis of foot, 254
scapulæ, 241
epigastric, deep, 251
peculiarities of, 252
relation of, to external ring, 457
to internal ring, 457
superior, 239
superficial, 252
ethmoidal, 246
facial, 243
transverse, 244
femoral, 252
branches of, 252
deep, 252
frontal, 243
gastric, 247
gastro-duodenalis, 247
epiploica dextra, 247
sinistra, 247
gluteal, 251
deep, 251
superficial, 251
hæmorrhoidal, external, 250
inferior, 250
middle, 250
superior, 249
hepatic, 247
hyoid branch of lingual, 243
of superior thyroid, 243
ileo-colic, 248
iliac, circumflex, deep, 252
common, 249
left, 248
right, 248
external, 251
internal, 250
ilio-lumbar, 251
infra-orbital, 243
innominate, 235
intercostal, 247
interosseous of ulnar, 242
dorsal of foot, 254
of hand, 242
of radial, 242
labial inferior, 243
lachrymal, 246
laryngeal, 243
inferior, 243
superior, 243
lateral sacral, 251
spinal, 236
lateralis nasi, 243

Artery or Arteries, lingual, 243
long ciliary, 246
thoracic, 241
lumbar, 249
malleolar, 254
external, 254
internal, 254
mammary, internal, 239
masseteric, 243
maxillary, internal, 245
median, 242
of forearm, 237
of spinal cord, 237
mediastinal, 247
posterior, 247
meningeal, from ascending pharyngeal, 245
anterior, from carotid, 246
inferior, from occipital, 244
middle, from internal maxillary, 245
posterior, from vertebral, 237
small, from internal maxillary, 245
mesenteric, inferior, 249
superior, 247
metacarpal, 242
metatarsal, 254
middle cerebral, 246
sacral, 251
musculo-phrenic, 245
mylo-hyoid, 245
nasal, 243
of ophthalmic, 246
nutrient of femur, 252
fibula, 254
humerus, 241
radius, 242
tibia, 254
ulna, 242
obturator, 250
occipital, 244
œsophageal, 247
ophthalmic, 246
orbital, 246
ovarian, 249
palatine, ascending, 245
descending, 245
inferior, 245
palmar arch, deep, 241
superficial, 243
interosseæ, 242
palpebral, 246
pancreatic, 247
pancreatico-duodenalis, 247
inferior, 247
perforating arteries, 247
from mammary artery, 239
from plantar, 254
from profunda, 253
Artery or Arteries, perforating, inferior, 253
middle, 253
superior, 253
pericardiac, 247
perineal, superficial, 250
transverse, 251
peroneal, 255
phrenic, 247
plantar external, 255
internal, 253
princeps cervicis, 244
pollicis, 242
profunda of arm, inferior, 241
superior, 241
cervicis, 239
femoris, 252
pterygoid, 245
pterygo-palatine, 245
pudic, 250
external, 252
deep, 250
internal, 250
peculiarities of, in female, 251
pulmonary, 255
pyloric, 247
radial, 241
arch of, 241
branches of, 241
radialis indicis, 242
ranine, 243
recurrent interosseous, 242
radial, 241
tibial, 254
ulnar, anterior, 242
posterior, 242
renal, 249
sacra media, 251
sacral, lateral, 251
scapular, posterior, 239
sciatic, 251
short ciliary, 246
sigmoid, 249
spermatic, 249
spheno-palatine, 245
spinal, anterior, 236
splenic, 247
sterno-mastoid, 243
stylo-mastoid, 244
subclavian, 236
branches of, 236
sublingual, 243
submaxillary, 243
submental, 243
subscapular, 240
superficialis volæ, 242
supra-orbital, 246
-renal, 249
-scapular, 238

Artery or Arteries, temporal, 244
anterior, 244
deep, 245
thoracic, acromial, 239
alar, 240
aorta, 247
long, 240
superior, 240
thyroid, inferior, 243
middle, 243
superior, 240
axis, 238
tibial, anterior, 253
branches of, 254
posterior, 254
branches of, 254
recurrent, 254
tonsillar, 243
transverse, of basilar, 238
facial, 244
transversalis colli, 238
tympanic, from internal carotid, 246
from internal maxillary, 245
ulnar, 242
arch of, 243
branches of, 242
relations of, in hand, 242
in wrist, 242
recurrent, anterior, 242
posterior, 242
uterine, 251
vaginal, 251
intestini tenuis, 249
vertebral, 236
vesical, inferior, 236
middle, 250
superior, 250
vestibular, 246
Vidian, 245
Arthrodia, 152
Articulations, 150, 152
acromio clavicular, 160
ankle, 168
calcaneo-astragaloid, 169
-cuboid, 169
carpal, 163
carpo-metacarpal, 165
classification of, 152
costo-clavicular, 160
-sternal, 156
-transverse, 156
-vertebral, 155
elbow, 161
hip, 165
immovable, 152
knee, 166
metacarpal, 165
metacarpo-phalangeal, 165
metatarsal, 170
Articulations, metatarso-phalangeal, 171
mixed, 152
movable, 152
occipito-atloid, 154
-axoid, 154
of pelvis, 157
with spine, 157
phalanges, 165, 171
pubic, 159
radio-carpal, 163
-ulnar, inferior, 162
middle, 162
superior, 162
sacro-coccygeal, 158
-iliac, 157
-sciatic, 158
scapular, 160
scapulo-clavicular, 160
shoulder, 161
of spine with cranium, 154
sterno-clavicular, 159
of sternum, 156
tarsal, 169
tarso-metatarsal, 170
temporo-maxillary, 153
tibio-fibular, inferior, 168
middle, 168
superior, 168
of vertebral column, 155
wrist, 163
Astragalus, 143
Atlas, 87
Auricle of heart, appendix of, 338, 340
Axes of pelvis, 132
Axis, 88
Axis-cylinder of nerve-tubes, 273

Back, muscles of, 194
Ball-and-socket joint, 152
Bartholine, duct of, 364
Bladder, 393
arteries of, 395
base of, 394
body of, 393
fundus of, 394
interior of, 394
ligaments of, 394
neck, 394
nerves of, 395
shape, position, and relations of, 393
structure of, 394
trigone of, 394
Blue spot of fourth ventricle, 298
Body of vertebra, 83
Bone, 1
apophyses of, 10
canaliculi of, 4

Bone, cancellous tissue of, 2
cells, 4, 7
analysis of, 7
compact tissue of, 2
development of, 6
eminences and depressions of, 10
epiphyses of, 10
Haversian system of, 3
lacunæ of, 3
lamellæ of, 5
marrow of, 5
microscopic structure of, 2
number of, 9
ossification of, 7
periosteum of, 6
astragalus, 143
atlas, 87
axis, 88
carpal, 119
clavicle, 105
coccyx, 96
cranial, 9
cuboid, 145
cuneiform of carpus, 121
of tarsus, 145
ethmoid, 33
facial, 9
femur, 133
fibula, 140
frontal, 11
hand, 123
humerus, 111
hyoid, 96
ilium, 125
innominate, 125
ischium, 129
lachrymal, 46
maxillary, inferior, 54
superior, 38
metacarpal, 122
metatarsal, 147
nasal, 36
occipital, 16
os calcis, 143
os magnum, 121
parietal, 14
patella, 137
pelvic, 131
phalanges of foot, 148
of hand, 124
pisiform. 121
pubic, 127
radius, 116
ribs, 100
sacrum, 93
scaphoid of carpus, 119
of tarsus, 144
scapula, 107
semilunar, 120
sphenoid, 26
Bone, sphenoidal spongy, 28
sternum, 97
tarsal, 141
temporal, 20
tibia, 138
trapezium, 121
trapezoid, 121
processes of turbinated, inferior, 53
of ethmoid, middle, 35
superior, 35
ulna, 114
unciform, 122
vertebra prominens, 89
vertebræ, cervical, 36
dorsal, 89
lumbar, 91
sacral, 93
vomer, 51
Wormian, 62
Brain, 274
arachnoid of, 277
base of, 286
dura mater of, 276
interior of, 290
lateral ventricles of, 290
lobes of, 282
membranes of 276
subdivision into parts, 274
upper surface of, 281
weight of, 274
Bronchi, 346
mode of subdivision in lung, 346
septum of, 346
structure of, in lobules of lung, 349

Calamus scriptorius, 308
Calcar, 293
Canal, anterior dental, 42
palatine, 45
for Arnold's nerve, 25
auditory, 22, 423
carotid, 25
incisive, 45
infra-orbital, 39
for Jacobson's nerve, 25
malar, 37
naso-palatine, 52
anterior, 45
pterygo-palatine, 29
sacral, 96
Canaliculi of bone, 4
Capsule of Glisson, 381
of Bowman, 385
Carpus, 119
Cartilage or Cartilages, 156
arytenoid, 344
cells of, 150
cricoid, 343

Cartilage or Cartilages, cuneiform, 344
of epiglottis, 343
fibro-, 150
hyaline, 150
interarticular, 151
reticular, 150
structure of, 151
thyroid, 343
yellow, 156
Casserian ganglion, 310
Cavity, cotyloid, 130
glenoid, 110
of pelvis, 132
Cells of bone, 4
ethmoidal, 35
hepatic, 382
mastoid, 21
Centrum ovale majus, 290
minus, 289
Cerebellum, 301
corpus dentatum of, 302
hemispheres of, 302
laminæ of, 303
lobes of, 302
lobulus centralis, 302
median lobe of, 302
peduncles of, 300
structure of, 303
valley of, 302
weight of, 301
Cerebrum, 279
base of, 286
commissures of, 289
convolutions of, 280
crura of, 288
fissures of, 282
general arrangement of, 282
gray matter of, 279
hemispheres of, 279
interior of, 290
lobes of, 280
peduncles of, 288
structure of, 279
sulci of, 282
under surface of, 286
ventricles of, 280
Choroid coat of eye, 415
Choroid plexus of lateral ventricle, 293
Clavicle, 105
development of, 107
Clitoris, 403
frænum of, 403
prepuce of, 403
Clusters of air-cells, 349
Coccyx, 96
Cochlea, 428
central axis of, 429
cupola of, 430
Cochlea, lamina spiralis of, 431
modiolus of, 429
scala tympani of, 430
vestibuli of, 430
spiral canal of, 430
Colon, 376
ascending, 376
descending, 376
sigmoid flexure of, 377
transverse, 376
Columnæ carneæ of left ventricle, 339, 340
of right ventricle, 339
Columns of Bertin, 389
Commissures of brain, anterior, 295
middle, 279
posterior, 279
great, 279
Conus arteriosus, 341
Convolution, development, 279
Convolution of corpus callosum, 285
of longitudinal fissure, 284
Convolutions, primary, 280
secondary, 280
number of, 280
of cerebrum, cortical substance of, 280
of frontal lobe, 282
of parietal lobe, 283
of occipital lobe, 283
of temporo-sphenoidal, 283
of island of Reil, 284
of orbital lobe, 283
of inner surface of hemisphere, 284
structure of, 280
white matter of, 279
of hyoid bone, 97
Cornua of sacrum, 95
Corpora albicantia, 288
geniculata, 292
striata, 291
Corpus callosum, 286
fimbriatum, 293
Corpuscles, Malpighian, of kidney, 389
of spleen, 384
Corti, organ of, 432
Cotunnius, nerve of, 312
Cowper's glands, 397
Craniometry, 79
Crest of ilium, 126
of tibia, 138
occipital, external, 17
internal, 19
sphenoidal, 28
turbinated, of palate, 49
Crista galli, 34
Crura cerebri, 288

Cuboid bone, 145
Cuneiform bone of foot, 145
of hand, 121
external, 147
internal, 145
middle, 147
Curvatures of spine, 85, 92

Diarthrosis, 152
rotatorius, 152
Digestion, organs of, 350
Duct or Ducts, of Bartholine, 364
biliary, 382
common choledoch, 383
of Greenhow, 383
of liver, 382
lymphatic, right, 266
of pancreas, 383
parotid, 363
Steno's, 363
Whartons, 363
Wirsung, 383
Duodenum, 373

Ear, 422
auditory canal, 423
auricle of, 423
cochlea, 429
external, 422
helix of, 422
internal, 428
labyrinth, 429
membranous, 433
middle, 424
ossicula of, 427
pinna, 423
semicircular canals, 429
tympanum, 424
vestibule, 429
Elbow-joint, 161
Eminence, canine, 43, 55
frontal, 11
ilio-pectineal, 131
parietal, 15
Eminentia articularis, 22
collateralis, 293
Endocardium, 342
Epiphyses, 10
Ethmoid bone, 32
cribriform plate of, 34
development of, 35
lateral masses of, 35
perpendicular plate of, 33
os planum of, 35
unciform process of, 35
Eustachian tube, 426
Eye, 413
appendages of, 420
chambers of, 414
ciliary ligament, 415
Eye, ciliary muscle, 415
processes, 416
humors of, 418
aqueous, 418
crystalline lens, 419
vitreous, 419
membrana pupillaris, 419
choroid, 415
conjunctiva, 421
cornea, 414
hyaloid, 419
iris, 416
Jacob's, 417
retina, 416
sclerotic, 414
pupil of, 418
uvea of, 416
Eyebrows, 420
Eyelashes, 420
Eyelids, 420
cartilage of, 421
Meibomian glands of, 421
muscles of, 420
tarsal ligament of, 421

Face, bones of, 36, 73
Fallopian tubes, 409
fimbriated extremity of, 409
Falx cerebelli, 277
cerebri, 276
Fascia dentata, 294
fibro-areolar, 151
Fasciculi teretes, 298
Female organs of generation, 402
carunculæ myrtiformes, 404
clitoris, 403
fossa navicularis, 403
fourchette, 403
frænulum pudendi, 403
glands of Bartholine, 404
hymen, 404
labia majora, 403
minora, 403
mons veneris, 403
nymphæ, 403
uterus, 406
vagina, 405
vestibule, 403
Femur, 133
development of, 137
structure of, 136
Fibro-cartilage, 150
acromio-clavicular, 160
intervertebral, 155
of knee, 168
of lower jaw, 153
pubic, 159
radio-ulnar, 162
semilunar, 168
sterno-clavicular, 159

Fibro-cartilage, triangular, 163
Fibrous tissue, white and yellow, 151
Fibula, 140
Fissure, auricular, 25
horizontal, of cerebellum, 303
longitudinal, of cerebrum, 279
of liver, 380
pterygo-maxillary, 77
spheno maxillary, 77
of Sylvius, 282
Fissures of brain, calloso-marginal, 285
inner surface of cerebrum, 285
parieto-occipital, 285
calcarine, 286
collateral, 286
longitudinal, 286
Rolando, 282
parieto-occipital, 282
transverse, 294
of cord, anterior and posterior median, 304
Follicles of Lieberkühn, 374
Foot, bones of, 141
ligaments of, 169
Foramen cæcum of frontal bone, 13
of medulla oblongata, 308
carotid, 25
condyloid, 18, 65
dental, inferior, 58
ethmoidal, 35
incisive, 45
infra-orbital, 43
intervertebral, 84
jugular, 65
lacerum anterius, 70
medium, 70
posterius, 70
magnum, 18, 65
mastoid, 21
mental, 56
of Monro, 292
ovale of sphenoid, 30
palatine, anterior, 45
posterior, 68
parietal, 15
pterygoid, 28
pterygo-palatine, 29
rotundum, 30
sacro-sciatic, 129
spheno-palatine, 51
spinosum, 30
stylo-mastoid, 25
supra-orbital, 12
vertebral, 87
Vesalii, 30
of Winslow, 371
Foramina, malar, 37
Foramina, olfactory, 34
sacral, 94
Thebesii, 338
Forearm, bones of, 115
Fornix, 293
Fossa, canine, 43
digastric, 21
digital, 134
glenoid, 21
iliac, 125
infra-spinous, 107
incisive, 43
jugular, 25
navicular of urethra, 396
of vulva, 403
occipital, 18
ovalis, 338
pituitary, 27
pterygoid of sphenoid, 32
scaphoid, 32
of skull, anterior, 68
middle, 68
posterior, 69
subscapular, 109
supra-spinous, 107
temporal, 76
zygomatic, 76
Fourchette, 403
Frontal bone, 11
air-sinus, 14

Gall-bladder, 382
duct of, 383
fissure for, 380
structure of, 382
valve of, 383
Ganglion or Ganglia, 273
Arnold's, 314
of Andersch, 317
cardiac, 331, 332
carotid, 330
Casserian, 310
cephalic, 311, 312, 314
cervical, inferior, 332
middle, 330
superior, 330
ciliary, 311
on circumflex nerve, 322
diaphragmatic, 332
of fifth nerve, 311, 312, 314
of fourth ventricle, 298
glosso-pharyngeal, 317
impar, 333
on interosseous nerve, posterior, 323
jugular, 317
lenticular, 311
lumbar, 332
Meckel's, 312
mesenteric, 331

Ganglion or Ganglia, ophthalmic, 311
otic, 314
petrous, 317
pneumogastric, 317
renal, 332
of Ribes, 330
of root of vagus, 317
sacral, 333
semilunar, of abdomen, 332
of fifth nerve, 310
of sympathetic, 332
solar, 332
spheno-palatine, 312
of spinal nerves, 319
submaxillary, 314
of sympathetic nerve, 331
thoracic, 332
of trunk of vagus, 317
of Wrisberg, 332
Ganglion cells, 271
Gladiolus, 99
Gland, agminate, 375
Brunner's, 374
Cowper's, 397
lachrymal, 422
of Littré, 396
Meibomian, 421
Peyer's, 375
prostate, 396
solitary, 374
Pacchioni, 13
Gliding movement, 150
Groove, bicipital, 112
infra-orbital, 42
lachrymal, 42
Grooves on radius, 118
Growth of bone, 6
Gyri operti, 284
Gyrus fornicatus, 285

Hand, bones of, 119
ligaments of, 164
Haversian canals, 2
Heart, 335
annular fibres of auricles, 342
auricles of, 337
circular fibres of, 342
conus arteriosus, 341
endocardium, 342
fibres of auricles, 342
of ventricles, 342
fibrous rings of, 341
fœtal relics in, 338
left auricle, 339
ventricle, 340
muscular structure of, 343
right auricle, 337
ventricle, 338
septum ventriculorum, 336
Heart, size and weight, 336
spiral fibres of, 342
structure of, 336
valves of, 339, 340
vortex of, 342
Hernia, direct inguinal, 456
coverings of, 457
femoral, 455
coverings of, 456
inguinal, 456
Hiatus Fallopii, 24
Highmore, antrum of, 38
Hippocampus major, 294
minor, 293
Humerus, 111
Hyoid bone, 96
development of, 97

Ileum, 373
Ilium, 125
Incus, 427
Inferior maxillary bone, 54
alveolar, 57
Infundibulum of brain, 288
Innominate bone, 125
development of, 131
Interarticular cartilage, 150
of jaw, 153
of knee, 168
of pubes, 159
of radio-ulnar joint, 163
of scapulo-clavicular joint, 160
of sterno-clavicular joint, 160
Intercellular substance of cartilage, 150
Intestine, large, 376
cellular coat of, 377
ileo-cæcal valve, 376
mucous membrane of, 378
muscular coat of, 377
serous coat of, 376
small, 373
cellular coat of, 374
divisions of, 373
glands of, 374
mucous coat of, 374
muscular coat of, 374
serous coat of, 374
simple follicles of, 375
valvulæ conniventes, 374
villi of, 374
Ischium, 130

Jacobson's nerve, canal for, 25
Jaw, lower, 54
ligaments of, 153
rami of, 57
symphysis of, 54
Jejunum, 373
Joints, 150

Kidneys, 384
artery of, 390
calyces of, 386
cortical substance of, 386
hilum of, 385
infundibula of, 386
Malpighian bodies of, 386
mammillæ of, 386
medullary substance of, 387
papillæ of, 386
pelvis of, 386
pyramids of Ferrein, 389
of Malpighi, 386
sinus of, 386
tubes of Ferrein, 388
tubuli uriniferi, 387
veins of, 390
weight and dimensions of, 384
Knee-joint, 168

Labia pudendi majora, 403
minora, 403
Labyrinth, membranous, 433
Lachrymal gland, 422
bones, 46
Lacteals, 267
Lacunæ of bone, 4
Lamina cinerea, 288
Larynx, 343
cartilages of, 343
cavity of, 345
glottis, 345
interior of, 345
ligaments of, 344
mucous membrane of, 346
muscles of, 345
superior aperture of, 344
ventricle of, 346
vocal cords of, false, 345
inferior, 346
true, 346
Leg, bones of, 139
ligaments of, 165
Lenticular ganglion, 311
Ligament or Ligaments, structure of, 151
acromio-clavicular, superior, 160
alar, of knee, 167
of ankle, anterior, 168
lateral, 168
annular, of ankle, 168
anterior, 168
external, 168
internal, 168
of radius and ulna, 162
of wrist, anterior, 163
posterior, 163
anterior, of knee, 168
astragalo-scaphoid, 169
atlo-axoid, anterior, 169
Ligament or Ligaments, broad, of lung, 347
calcaneo-cuboid, internal, 169
long, 169
short, 169
superior, 169
calcaneo-scaphoid, superior, 170
capsular, 171
carpo-metacarpal, 165
of carpus, 163
check, 154
common vertebral, anterior, 155
posterior, 155
conoid, 160
coraco-acromial, 160
-clavicular, 160
coracoid, 160
coronary, of knee, 168
costo-clavicular, 160
cotyloid, 166
crico-arytenoid, 344
-thyroid, 344
crucial, of knee, 167
deltoid, 169
of elbow, 161
glenoid, 161
glosso-epiglottidean, 344
of hip, 166
hyo-epiglottic, 344
ilio-femoral, 166
-lumbar, 158
interarticular, of ribs, 155
interspinous, 155
intertransverse, 155
intervertebral, 155
of jaw, 153
of knee, 167
of larynx, 344
of liver, 380
lumbo-iliac, 158
sacral, 158
metacarpal, 165
metacarpo-phalangeal, 165
metatarsal, 170
metatarso-phalangeal, 171
mucosum, 167
odontoid, 154
orbicular, 162
of pelvis, 157
plantar, 170
long, 170
posterior, of knee, 167
posticum Winslowii, 167
pterygo-maxillary, 153
pubic, anterior, 159
radio-carpal, 163
radio-ulnar, anterior, 162
round, of hip, 166
sacro-iliac, anterior, 157
oblique, 157

Ligament or Ligaments, sacro-iliac, posterior, 157
sacro-sciatic, anterior, greater, 158
lesser, 158
of scapula, 160
scapulo-clavicular, 160
of shoulder, 161
stellate, 155
stylo-maxillary, 153
subflavous, 155
subpubic, 159
supra-spinous, 155
thyro-hyoid, 344
tibio-fibular, 168
-tarsal, 169
transverse, of hip, 166
of knee, 167
of scapula, 160
of tibio-fibular, 168
trapezoid, 160
of wrist, 163
Ligamenta alaria, 167
subflava, 155
Ligamentum mucosum, 155
patellæ, 163
Linea aspera, 135
ileo-pectinea, 132
quadrati, 135
Liver, 379
arteries of, 381
ducts of, 381
fibrous coat of, 379
fissures of, 380
ligaments of, 379
lobes of, 379
lobules of, 381
situation, size, and weight, 379
structure of, 381
vessels of, 380
Lower extremity, bones of, 125
Lungs, 347
air-sacs of, 349
capillaries of, 350
clusters of, 347
lobes and fissures of, 348
lobules of, 349
structure of, 347
subdivision of bronchi in, 349
weight, color, etc., 348
Lymph-sinuses, 264
Lymphatic duct, right, 267
Lymphatic glands, 264
axillary, 266
bronchial, 267
of elbow, 266
inguinal, deep, 269
superficial, 269
of lower extremity, 269
mediastinal, 266
Lymphatic glands of neck, 265
of thorax, 267
of upper extremity, 265
Lymphatics, 264
abdomen, 267
arm, 265
bladder, 269
cervical, 265, 266
chest, 267
clitoris, 269
cranium, 265
face, deep, 265
superficial, 265
groin, 269
head, 265
intestines, 268
lacteals, 267
large intestine, 267
lower extremity, 265
lung, 266
mesenteric, 267
neck, 265
origin of, 264
ovaries, 269
pelvis, 269
penis, 269
prostate, 269
rectum, 269
scrotum, 269
small intestine, 267
testicle, 269
thoracic duct, 267
thorax, 266
thyroid, 265
trunk, 265
upper extremity, 265
uterus, 269
vagina, 269

Magnum (os) of carpus, 121
Malar bone, 37
Malleolus, external, 141
internal, 140
Malleus, 427
Mammary gland, 411
Manubrium of sternum, 98
Marrow of bone, 5
Mastoid cells, 22
portion of temporal bone, 21
Meatus auditorius externus, 20
internus, 23
of nose, inferior, 74
middle, 74
superior, 74
urinarius, female, 404
male, 396
Meckel's ganglion, 312
Mediastinum, anterior, 335
middle, 335
posterior, 335

Medulla oblongata, 299
Membrana pupillaris, 414
tympani, 426
secundaria, 425
Metacarpus, 122
Metatarsus, 147
Motor oculi, 316
Mouth, 350
Muscles, minute anatomy, 172
of animal life, 172
aponeurosis, 176
arrangement of fibres, 173
fasciculi of, 174
fibrils of, 174
insertion of, 175
involuntary, 174
of organic life, 174
sarcous elements of, 174
sheath of, 174
striped, 173
unstriped, 174
voluntary, 174
Muscle or Muscles, 172
of abdomen, 207
abductor minimi digiti, of foot, 227
of hand, 215
pollicis, of foot, 226
of hand, 213
accelerator urinæ, 229
accessorius ad sacro-lumbalem, 197
pedis, 227
adductor brevis, 219
longus, 219
magnus, 219
pollicis, of hand, 214
of foot, 228
anconeus, 211
arytæno-epiglottideus inferior, 345
superior, 345
arytænoideus, 345
attollens aurem, 178
attrahens aurem, 178
azygos uvulæ, 188
of Bell, 394
biceps, of arm, 207
of leg, 221
biventer cervicis, 199
brachialis anticus, 208
buccinator, 183
cervicalis ascendens, 197
coccygeus, 231
compressor nasi, 180
narium minor, 180
urethræ, 230, 231
constrictor pharyngis inferior, 190
medius, 190
superior, 189
Muscle or Muscles, coraco-brachialis, 207
corrugator supercilii, 176
corrugator cutis ani, 231
crico-arytænoideus lateralis, 345
posticus, 345
crico-thyroid, 345
crureus, 218
deltoid, 206
depressor alæ nasi, 180
diaphragm, 192
digastric, 186
dilator naris, anterior, 180
posterior, 180
erector clitoridis, 231
penis, 229
spinæ, 197
extensor brevis digitorum, 226
carpi radialis brevior, 210
longior, 210
ulnaris, 210
coccygis, 201
communis digitorum, 210
indicis, 212
longus digitorum, 223
minimi digiti, 211
ossis metacarpi pollicis, 213
primi internodii pollicis, 213
proprius pollicis, 223
secundi internodii pollicis, 213
flexor accessorius, 227
brevis minimi digiti, of foot, 228
of hand, 215
brevis digitorum, 226
pollicis, of foot, 227
of hand, 213
carpi radialis, 208
ulnaris, 209
digitorum profundus, 209
sublimis, 209
longus digitorum, 226
pollicis, of foot, 225
of hand, 209
gastrocnemius, 224
gemellus inferior, 221
superior, 221
genio-hyoglossus, 187
-hyoid, 187
gluteus maximus, 219
medius, 220
minimus, 220
gracilis, 218
hyoglossus, 187
iliacus, 216
infra-costal, 192
infra-spinatus, 296
intercostal, 192
external, 192
internal, 192

Muscle or Muscles, interossei, dorsal, 216
palmar, 215
plantar, 228
interspinales, 200
intertransversales, 201
latissimus dorsi, 195
levator anguli oris, 182
scapulæ, 195
ani, 229, 231
labii inferioris, 182
superioris, 182
alæque nasi, 180
menti, 182
palati, 188
palpebræ, 177
superioris, 177
levatores costarum, 192
lingualis, 187
longissimus dorsi, 198
longus colli, 191
lumbricales, of foot, 227
of hand, 215
masseter, 183
multifidus spinæ, 199
mylo-hyoid, 187
obliquus abdominis externus, 201
internus, 202
capitis inferior, 200
superior, 200
oculi inferior, 179
superior, 179
obturator externus, 221
internus, 220
occipito-frontalis, 176
omo-hyoid, 186
opponens minimi digiti, 215
pollicis, 213
orbicularis oris, 182
palpebrarum, 176
palato-glossus, 188
-pharyngeus, 188
palmaris brevis, 215
longus, 208
pectineus, 219
pectoralis major, 205
minor, 205
peroneus brevis, 224
longus, 224
tertius, 223
plantaris, 225
platysma myoides, 185
popliteus, 225
pronator quadratus, 209
radii teres, 208
psoas magnus, 216
parvus, 216
pterygoid, external, 184
internal, 184
pyramidalis abdominis, 203
Muscle or Muscles, pyramidalis nasi, 180
pyriformis, 220
quadratus femoris, 221
lumborum, 204
menti, 182
quadriceps extensor femoris, 218
rectus abdominis, 203
capitis anticus major, 190
minor, 190
posticus major, 200
minor, 200
femoris, 217
lateralis, 191
oculi externus, 178
inferior, 178
internus, 178
superior, 178
retrahens aurem, 178
rhomboideus major, 196
minor, 196
risorius of Santorini, 183
rotatores spinæ, 200
sacro-lumbalis, 197
sartorius, 217
scalenus anticus, 191
medius, 191
posticus, 191
semimembranosus, 222
semispinalis colli, 199
dorsi, 199
semitendinosus, 222
serratus magnus, 206
posticus inferior, 196
superior, 196
soleus, 224
sphincter ani, external, 231
internal, 231
vaginæ, 231
spinalis colli, 198
dorsi, 198
splenius, 197
capitis, 197
colli, 197
sterno-cleido-mastoid, 185
-hyoid, 185
-thyroid, 185
stylo-glossus, 188
-hyoid, 187
-pharyngeus, 190
subanconeus, 208
subclavius, 205
subcrureus, 218
subscapularis, 206
supinator brevis, 211
longus, 210
supra-spinales, 206
supra-spinatus, 206
temporal, 184

Muscle or Muscles, tensor palati, 188
tarsi, 177
vaginæ femoris, 217
teres major, 206
minor, 206
thyro-arytænoideus, 345
-epiglottideus, 345
-hyoid, 185
tibialis anticus, 223
posticus, 225
trachelo-mastoid, 198
transversalis abdominis, 203
colli, 198
transversus pedis, 228
perinæi, 229, 231
trapezius, 194
triangularis menti, 182
sterni, 192
triceps extensor cubiti, 208
vastus externus, 217
internus, 218
zygomaticus major, 181
minor, 181

Nasal bones, 36
fossæ, 72
Nates of brain, 297
Negroid brain-weight, 275
Nerve or Nerves, cerebro-spinal, 270
composition of, 270
neurilemma of, 273
cells, 273
abducens, 314
accessory obturator, 326
acromial, 322
auditory, 316
auricular, of auricularis magnus, 320
of auriculo-temporal, 313
posterior, from facial, 315
of second cervical, 320
of small occipital, 320
of vagus, 317
auricularis magnus, 320
cardiac, 330, 331
inferior, 331
middle, 331
of pneumogastric, 317
superior, 330
cardiacus magnus, 330
minor, 332
cavernous, of penis, 329
cervical, anterior, 320
posterior, 320
superficial branches of, 320
cervico-facial, 320
chorda tympani, 316
ciliary, long, 311
Nerve or Nerves, ciliary, short, 311
circumflex, 322
clavicular, 322
coccygeal, 326
cochlear, 316
communicans noni, 321
peronei, 328
of Cotunnius, 312
cranial, 303
anterior crural, 326
cutaneous, of accessory obturator, 326
of arm, external, 322
internal, 323
lesser internal, 323
of cervical plexus, 320
circumflex, 322
coccygeal, 326
crural, anterior, 326
dorsal nerves, 324
dorsalis penis, 329
external, 325
hæmorrhoidal inferior, 329
ilio-hypogastric, 325
-inguinal, 325
intercostal, 324
internal, 326
of ischio-rectal region, 329
lateral of dorsal, 324
of intercostal, 324
lumbar, 324
median, 322
musculo-cutaneous, 322
-spiral, 323
obturator, 326
palmar, 324
perineal, 329
peroneal, 328
plantar, 328
popliteal, external, 328
internal, 327
middle, 326
radial, 323
sacral, 327
sciatic, lesser, 329
small, 329
of thorax, anterior, 322
lateral, 322
tibial, anterior, 328
posterior, 328
ulnar, 323
dental, anterior, 312
inferior, 313
posterior, 312
descendens noni, 319
digastric, from facial, 316
digital of foot, dorsal, 329
plantar, 329
of hand, dorsal, 324
palmar, median, 324

Nerve or Nerves, dorsal, 324
anterior branches of, 324
posterior branches of, 324
of penis, 329
eighth pair, 316
of eyeball, 311
facial, 314
fifth, 310
fourth, 310
frontal, 311
gastric branches of vagus, 318
genito-crural, 325
glosso-pharyngeal, 316
gluteal, inferior, 329
superior, 329
gustatory, 314
of heart, 330
hæmorrhoidal, inferior, 329
hypoglossal, 319
ilio-hypogastric, 325
-inguinal, 325
incisor, 313
infra-orbital of facial, 316
-trochlear, 311
intercostal, 324
intercosto-humeral, 323
interosseous anterior, 323
posterior, 323
Jacobson's, 318
labial, 316
lachrymal, 311
of Lancisi, 289
laryngeal, 318
inferior, 318
recurrent, 318
superior, 318
lingual, of glosso-pharyngeal, 317
lumbar, 324
branches of, 324
roots of, 324
lumbo-sacral, 326
malar branch of facial, 316
masseteric, 313
maxillary, inferior, 313
superior, 311
median, 322
mental, 313
motor oculi, 313
musculo-cutaneous, of abdomen, 325
of arm, 322
from peroneal, 329
musculo-spiral, 323
mylo-hyoid, 313
nasal, from Meckel's ganglion, 312
of ophthalmic, 311
from superior maxillary, 312
from Vidian, 312
Nerve or Nerves, naso-palatine, 312
ninth, 316
obturator, 325
accessory, 325
occipital of facial, 316
great, 320
small, 320
from third cervical, 320
occipitalis major, 320
minor, 320
œsophageal, 332
olfactory, 308
ophthalmic, 310
optic, 309
palatine, 312
anterior, or large, 312
posterior, or small, 312
palmar cutaneous of median, 323
ulnar, 323
palpebral, 311
par vagum, 317
pathetic, 310
perineal, 329
superficial, 329
peroneal, 328
petrosal, small, 315
superficial external, or large, 315
pharyngeal, of external laryngeal, 318
of glosso-pharyngeal, 317
of Meckel's ganglion, 312
of pneumogastric, 318
of sympathetic, 331
phrenic, 320
plantar, cutaneous, 329
external, 328
internal, 328
pneumogastric, 317
popliteal, external, 328
internal, 327
portio dura, 314
mollis, 316
pterygo-palatine, 312
pudic, 329
pulmonary, from vagus, 318
radial, 323
recurrent laryngeal, 318
renal splanchnic, 332
respiratory, external, 322
internal, 320
sacral, 327
roots of, 327
saphenous, external, or short, 328
internal, or long, 326
sciatic, great, 327
small, 329
seventh, 314
sixth, 314

Nerve or Nerves, spermatic, 325
spheno-palatine, 312
spinal accessory, 318
splanchnic, great, 332
lesser, 332
renal, or smallest, 332
splenic, 331
stylo-hyoid of facial, 316
subclavian, 322
suboccipital, 320
subscapular, 322
superficialis colli, 322
supra-clavicular, 322
-maxillary, of facial, 316
-orbital, 311
-scapular, 322
sympathetic, 330
cephalic portion of, 330, 331
cervical portion of, 330
lumbar portion of, 332
pelvic portion of, 333
thoracic portion of, 332
temporal, of auriculo-temporal, 313
deep 313
of facial, 316
temporo-facial, 316
third or motor oculi, 310
thoracic, anterior, 322
cardiac, 331
posterior, 322
tibial, anterior, 328
posterior, 328
of tongue, 319
tonsillar, 317
trifacial, 310
trigeminus, 310
tympanic, of facial, 316
of glosso-pharyngeal, 317
ulnar, 323
uterine, 333
vaginal, 333
vagus, 317
branches of, 318
ganglia of, 317
Vidian, 312
of Wrisberg, 323
Nervous substance, microscopical appearance of, 270
Nervous system, general anatomy of, 270
of animal life, 270
cerebro-spinal axis, 274
cortical substance, 279
fibrous nervous matter, 270
ganglia, 273
gray matter, 272, 307
of organic life, 330
sympathetic, 330
composition of, 273
Nervous system, sympathetic, gelatinous fibres of, 273
tubular fibres of, 271
vesicular matter, 272
white or medullary substance of, 273
Neurilemma, 2
Neuroglia, 273
Nidus hirundinis, 302
Nose, bones of, 36
meatuses of, 72
Notch, cotyloid, 130
ethmoidal, 13
sacro-sciatic, greater, 129
lesser, 129
sigmoid, 58
supra-scapular, 109

Occipital bone, 16
crests of, 18
Œsophagus, 366
structure of, 366
Olfactory bulb, 286
nerve, 308
Olivary bodies of medulla oblongata, 299
Optic commissure, 288
nerve, 309
thalami, 292
Orbits, 71
Os calcis, 143
hyoides, 96
innominatum, 125
magnum of carpus, 121
planum, 35
Ossification of bone, 6
intra-cartilaginous, 6
inter-membranous, 6
Osteology, 1
Otic ganglion, 314
Ovary, 409
corpus luteum of, 411
Graafian vesicles of, 409
ligament of, 411
shape, position, and dimensions of, 409
stroma of, 410
Ovula of Naboth, 409

Pacchionian depressions, 13
bodies, 277
Palate, hard, 45
bone, 47
Pancreas, 383
duct of, 383
structure of, 383
Parietal bones, 14
Parotid gland, 362
Patella, 137
Patheticus, 310

Pelvic viscera, 393
Pelvis, arteries of, 131, 393
axes of, 132
brim of, 132
cavity of, 132
diameters of, 132
male and female, differences of, 133
Penis, 397
arteries of, 399
body of, 397
corpora cavernosa, 398
corpus spongiosum, 398
dorsal artery of, 399
nerve of, 399
vein, 398
glans, 398
prepuce of, 398
root of, 397
suspensory ligament of, 397
Perforated space, anterior, 287
posterior, 288
Pericardium, 335
Peritoneum, 369
folds of, 369
lesser cavity of, 371
ligaments, 371
mesenteries, 370
omenta of, 370
reflections of, 369
Pes hippocampi, 294
Phalanges, of foot, 148
of hand, 124
Pharynx, 364
aponeurosis of, 365
mucous membrane of, 365
muscles of, 364
Pia mater of brain, 278
Pineal gland, peduncles of, 295–297
Pinna of ear, 422
cartilage of, 422
muscles of, 422
Pisiform bone, 121
Pituitary body, 288
Pleura, 347
cavity of, 347
parietal layer of, 347
reflections of, 347
visceral layer of, 347
Plexus of nerves, aortic, 332
brachial, 321
cardiac, anterior, 332
deep, or great, 332
superficial, 332
carotid, 314
cavernous, 311
cervical, 320
cœliac, 332
cystic, 333
Plexus of nerves, diaphragmatic, 332
hæmorrhoidal, inferior, 333
superior, 333
hepatic, 333
hypogastric, 333
lumbar, 325, 332
meningeal, 316
œsophageal, 332
prostatic, 262, 333
pulmonary, anterior, 330
posterior, 330
pyloric, 331
renal, 331
sacral, 327, 332
solar, 330
vaginal, 262
hæmorrhoidal, 262
pampiniform, 262
uterine, 262
Pons Varolii, 300
Process or Processes, acromion, 107
alveolar, 56
angular, external, 12
internal 12
auditory, 22
basilar, 17
clinoid, anterior, 69
middle, 69
posterior, 69
condyloid, of lower jaw, 59
coracoid, 109
coronoid, of lower jaw, 58
of ulna, 114
ethmoidal, of inferior turbinated, 53
cerebello ad testes, 297
frontal, of malar, 37
hamular, of sphenoid, 32
of Ingrassias, 29
jugular, 17
lachrymal, of inferior turbinated bone, 53
malar, of superior maxillary, 38
mastoid, 21
maxillary, of inferior turbinated, 53
of malar bone, 37
nasal, 38
odontoid, of axis, 88
olecranon, 114
olivary, of palate, 48
palatine, of superior maxillary, 44
pterygoid, of palate bone, 49
of sphenoid, 31
spinous, of ilium, 125
of sphenoid, 31
of tibia, 138

Process or Processes, spinous, of vertebræ, 83
styloid, of radius, 118
of ulna, 116
transverse, of vertebræ, 84
unciform, 122
of ethmoid, 35
vaginal, of sphenoid, 28
of temporal, 25
vermiform, of cerebellum, 302
zygomatic, 21
Promontory of sacrum, 94
Prostate gland, 396
lobes of, 397
position of, 396
size and shape of, 396
structure of, 396
changes in, 397
Protuberance, occipital, external, 17
internal, 18
Pubes, 127
symphysis of, 132
Puncta vasculosa, 289
Pyramids, anterior, 299
decussation of, 299
of Ferrein, 389
of Malpighi, 386
posterior, 299

Radius, 116
Ramus of ischium, 129
of lower jaw, 58
of pubes, 127
Receptaculum chyli, 267
Rectum, 378
folds of, 378
Regional anatomy, 440
axilla, 447
femoral hernia, 463
inguinal hernia, 466
neck, 440
perineum, 450
Scarpa's triangle, 454
Restiform bodies of medulla oblongata, 299
Retina, 416
Ribs, 100
common characters of, 101
false, 100
floating, 100
peculiar, 102
true, 100
Ridge, internal occipital, 18
mylo-hyoidean, 55
pterygoid, 31
superciliary, 11
temporal, 76
Rosenmüller, organ of, 411
Rostrum of sphenoid bone, 28

Saccule, 433
Sacrum, 93
cornua of, 95
development of, 96
structure of, 96
Salivary glands, 362
structure of, 362
Scaphoid bone, of foot, 144
of hand, 119
Scapula, 107
Scarpa's triangle, 454
Sclerotic, 414
Seminal vesicles, 402
Shoulder-joint, bones of, 107, 111
Sinus or Sinuses, cavernous, 258
circular, 259
coronary, 337
of diploe, 257
of dura mater, 257, 277
lateral, 258
longitudinal, inferior, 257
superior, 257
maxillary, 41
occipital, 258
petrosal, greater, 259
lesser, 259
pituitary, 259
straight, 257
sphenoidal, 28
transverse, 259
uterine, 262
Skin, anatomy of, 436
appendages of, 438
Skull, 60, 77
angles, 79–82
anterior region of, 71
base of, 63
cerebral or internal surface, 68
fissures of, 77
fossa of, 68
lateral region of, 76
sutures of, 61
vertex of, 62
Smell, organ of, 435
Spermatic cord, 400
Spermatozoa, 401
Sphenoid bone, 26
development of, 32
Sphenoidal spongy bones, 28
Spinal cord, 303
arachnoid of, 303
arrangement of gray and white matter in, 304
central canal of, 308
columns of, 304
dura mater of, 303
fissures of, 304
gray matter of, 307
ligamentum denticulatum of, 304
membranes of, 303

Spinal cord, pia mater of, 303
white matter of, 304
Spinal nerves, 319
ganglia of, 319
roots of, anterior, 319
posterior, 319
Spine, 83
curves of, 92
in relation to structures of back, 85
of ischium, 129
nasal, anterior, 73
posterior, 67
pharyngeal, 17
of pubes, 127
of scapula, 107
Spleen, 383
capillaries of, 384
fibrous elastic coat of, 384
fissure of, 384
hilum of, 384
Malpighian corpuscles of, 384
proper substance of, 384
structure of, 384
suspensory ligament of, 383
trabeculæ of, 384
Squamous portion of temporal bone, 26
Stapes, 427
Steno's duct, 363
Sternum, 97
Stomach, 371
cellular coat of, 373
curvatures of, 371
fundus of, 372
follicles of, 372
glands, 373
mucous glands of, 373
mucous membrane of, 373
muscular coat of, 372
orifices of, 372
peptic glands of, 373
pyloric end of, 372
structure of, 372
Subarachnoid fluid, 278
space of brain, 278
Sublingual gland, 364
duct of, 364
Submaxillary gland, 363
duct of, 363
ganglion, 314
Sulci of cerebrum, 279
Superior maxillary bone, 38
articulations of, 38
development of, 46
Supra-renal capsules, 391
structure of, 391
Suture, coronal, 61
cranial, 61
frontal, 61
Suture, fronto-malar, 60
-maxillary, 60
lambdoid, 61
Synovial, of wrist, 164
tarsal, 170
System, Haversian, 2

Tænia semicircularis, 292
Tarsus, 141
Taste, organ of, 433
Teeth, 351
bicuspid, 356
canine, 354
cement of, 358
cortical substance of, 358
crown of, 352
crusta petrosa of, 358
deciduous, 351, 357
dentine of, 358
development of, 360
enamel of, 359
eruption of, 361
eye, 354
fang of, 352
growth of, 360
incisors, 353
intertubular tissue of, 358
milk, 351
molar, 356
permanent, 353
pulp-cavity of, 358
roots of, 358
structure of, 358
temporary, 357
tubuli of, 359
wisdom, 351, 357
Temporal bone, 20
mastoid portion of, 21
petrous portion of, 23
squamous portion of, 20
Tendo-oculi, 421
Tentorium cerebelli, 276
Testes, 399
of brain, 297
coverings of, 399
tunica albuginea, 401
vaginalis, 400
vasculosa, 401
gubernaculum, 399
lobules of, 401
lymphatics of, 400
mode of descent of, 400
size and weight of, 400
structure of, 401
tubuli seminiferi of, 401
vas deferens of, 402
vasa efferentia of, 401
recta, 401
Thigh, bone of, 133
Thoracic duct, 267

Thorax, 103, 334
bones of, 103
openings of, 334
Thymus gland, 392
Thyroid gland, 391
Tibia, 138
structure of, 140
Tonsils, 366
Torcular Herophili, 18
Trachea, 346
cartilages of, 346
structure of, 346
Trapezium bone, 121
Trapezoid bone, 121
Trifacial nerve, 310
Trochanters, greater and lesser, 134
Trochlea of humerus, 114
Tubes, Fallopian, 409
Tuber cinereum, 288
Tubercle, conoid, 108
genial, 56
of zygoma, 21
Tubercula quadrigemina, 297
Tuberosities of humerus, greater and lesser, 111
of tibia, 139
Tuberosity of ischium, 130
maxillary, 46
of palate bone, 48
of radius, 117
Tubuli of Ferrein, 388
of Bellini, 387
of Henle, 389
uriniferi, 387
Turbinated bone, inferior, 53
middle, 53
superior, 53
Tympanum, 424
cavity of, 424
membrane of, 426
mucous membrane of, 426
muscles of, 428
ossicula of, 427

Ulna, 114
Unciform bone, 123
Upper extremity, bones of, 105
Ureters, 390
Urethra, female, 404
male, 395
bulbous portion of, 395
membranous portion of, 395
prostatic portion of, 395
spongy portion of, 395
structure of, 396
veru montanum of, 395
Uterus, 406
appendages of, 406
arbor vitæ of, 408
cavity of, 407
Uterus, cervix of, 407
fundus of, 406
ligaments of, 407
nerves of, 409
shape, position, etc., of, 406
structure of, 408
vessels of, 409
Utricle of vestibule, 433

Vagina, 405
columns of, 405
orifice of, 402
Valve, Eustachian, 338
mitral, 340
semilunar, aortic, 339, 311
pulmonic, 339, 341
tricuspid, 339
of Vieussens, 297
Valvulæ conniventes, 374
Vein or Veins, general anatomy of, 255
anastomoses of, 256
coats of, 256
plexus of, 256
valves of, 256
articular, of knee, 261
auricular, posterior 256
axillary, 260
azygos, 263
major, 263
minor, 263
basilic, 260
basi-vertebral, 264
brachial, 260
cava, inferior, 262
superior, 263
cephalic, 260
cerebellar, 257
cerebral, 257
circumflex iliac, 262
superficial, 262
of corpora cavernosa, 262
of corpus spongiosum, 262
of diploe, 257
dorsal, of penis, 262
epigastric, 262
superficial, 262
facial, 256
femoral, 261
gastric, 263
hæmorrhoidal, 262
of head, 256
hepatic, 262
iliac, common, 262
external, 261
internal, 261
innominate, 263
intercostal, 263
superior, 263
interlobular, 263, 381

Vein or Veins, jugular, anterior, 257
external, 257
posterior, 257
internal, 257
lobular, 263
of liver, 381
longitudinal sinus, inferior, 257
superior, 257
lumbar, 262
mammary, internal, 263
maxillary, internal, 256
median, 260
basilic, 260
cephalic, 260
mesenteric, inferior, 263
superior, 263
of neck, 257
occipital, 256
ophthalmic, 258
phrenic, 262
popliteal, 261
portal, 263
profunda femoris, 261
radial, 260
renal, 262
saphenous, external or short, 261
internal or long, 261
spermatic, 262
splenic, 263
subclavian, 261
sublobular, 263
supra-renal, 262
temporal, 256
middle, 256
temporo-maxillary, 256
thyroid, inferior, 263
ulnar, anterior, 260
of upper extremity and thorax, 260
vaginal, of liver, 263
of vertebræ, 257
Velum interpositum, 295
Venæ Galeni, 295
Venter of ilium, 125
of scapula, 109
Ventricle of brain, third, 295
fourth, 297
fifth, 295
of heart, left, 340
right, 338
of larynx, 346
Vertebra prominens, 89
Vertebræ, 83
cervical, 86
coccygeal, 96
development of, 92
dorsal, 89
general characters of, 83
lumbar, 91
sacral, 93
Vertex of skull, 62
Vidian nerve, 312
Villi, 374
Violet streaks of fourth ventricle, 298
Vocal cords, false, 345
inferior, 346
superior, 345
true, 346
Vomer, 51
alæ of, 52
development of, 52
Vulva, 403

White substance of brain, 273
of Schwann, 273
Wormian bones, 63

Xanthochroic races, 275
brain-weights, 275

Zygoma, 21

PHILADELPHIA

SCHOOL OF ANATOMY,

1713 and 1715 Cherry Street,

PHILADELPHIA.

The school is open for practical work in Anatomy and Operative Surgery from September 1st to June 1st. The hours are from 8 A.M. to 10 P.M. Close attention is given to the work of each student, the classes being under the direction of able and experienced demonstrators.

FEES.

Dissection, including Lectures and Demonstrations,	$10.00
Material, Each Part,	1.00

Operative Surgery, including Material and Use of Instruments.

For Classes of Four or More, Each,	15.00
For Classes of Three, Together,	50.00
For Classes of Two, Together,	40.00
For One Person,	30.00

For further information, address

HENRY C. BOENNING, M.D.,

1713 and 1715 Cherry Street.

Or the Following Demonstrators:

T. T. BLAND, M.D. BERNARD BERENS, M.D. A. B. HIRSH, M.D.
T. C. SANGREE, M.D. J. W. CROSKEY, M.D.
T. B. EARLEY, M.D. R. F. LONGACRE, M.D.

Andrew Drummond, Janitor.

ANATOMICAL DEPARTMENT
BELFAST
QUEEN'S UNI

QUEEN'S UNIVERSITY OF BELFAST
SHELVED AT
QH 34/1
BIOMEDICAL LIBRARY
CHARGE 0